



Integrated Test Online CVS + HEMAT

25-08-2025

Dr. Zaina Vora

INTEGRATED CVS

1. Which of the following is not included as a major component of Jones criteria for diagnosing acute rheumatic fever?

A. Chorea

B. Increased PR interval

C. Erythema marginatum

D. Arthralgia

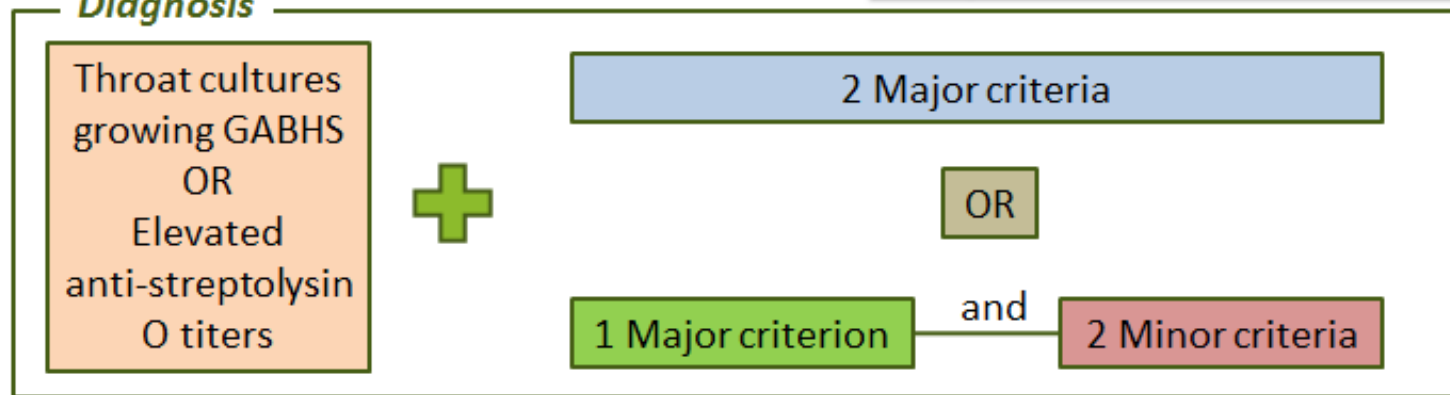
Major Criteria

J	Joint Involvement
O	O looks like a heart = myocarditis
N	Nodules, subcutaneous
E	Erythema marginatum
S	Sydenham chorea

Minor Criteria

C	CRP Increased
A	Arthralgia
F	Fever
E	Elevated ESR
P	Prolonged PR Interval
A	Anamnesis of Rheumatism
L	Leukocytosis

Diagnosis

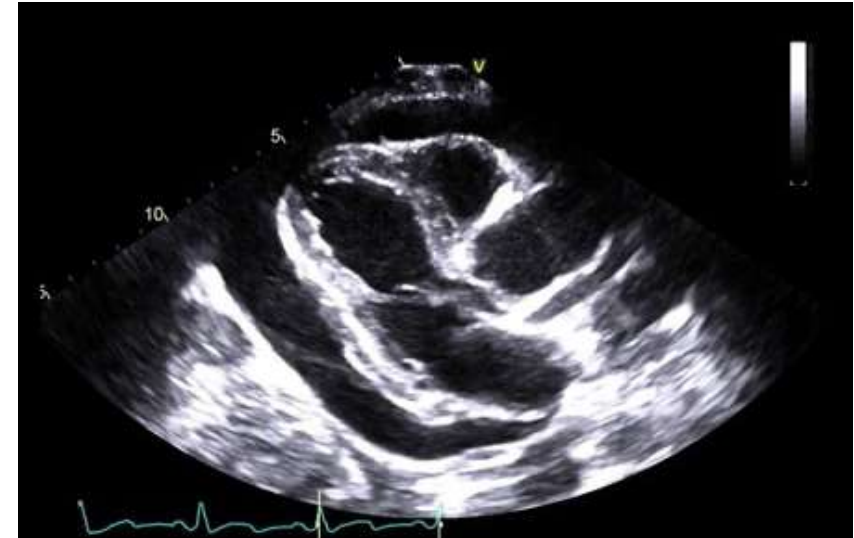

2. Choose the cardiac event that corresponds to the phase of isovolumetric contraction:

- A. S3 heart sound
- B. S2 heart sound
- C. QRS wave of ECG
- D. c wave of JVP

3. A 46-year-old man complains of dyspnoea and chest discomfort. He believes that the symptoms are due to a respiratory infection he had 4 weeks ago, but he did not see a doctor at that time. ECHO is shown below. Which of the following additional findings may be seen?

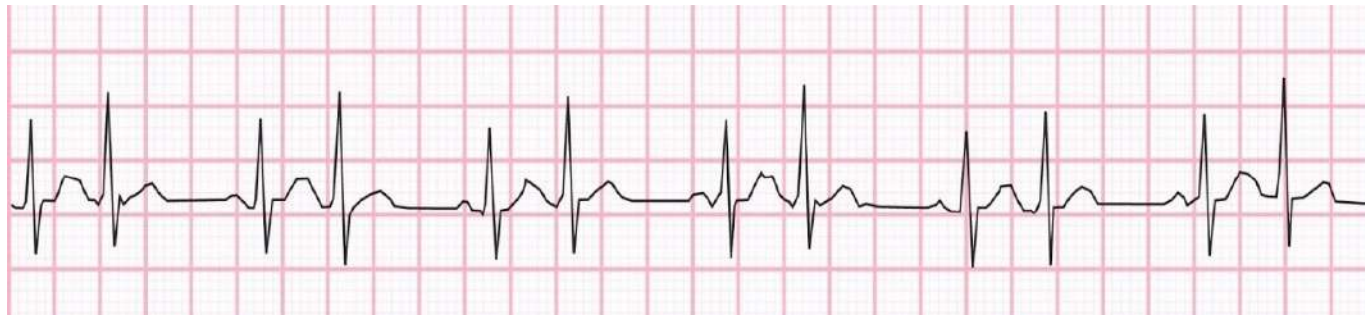
- A. High-pitched, early diastolic sound
- B. Systolic anterior motion of mitral valve
- C. Delta wave on ECG
- D. Inferonasal ectopia lentis



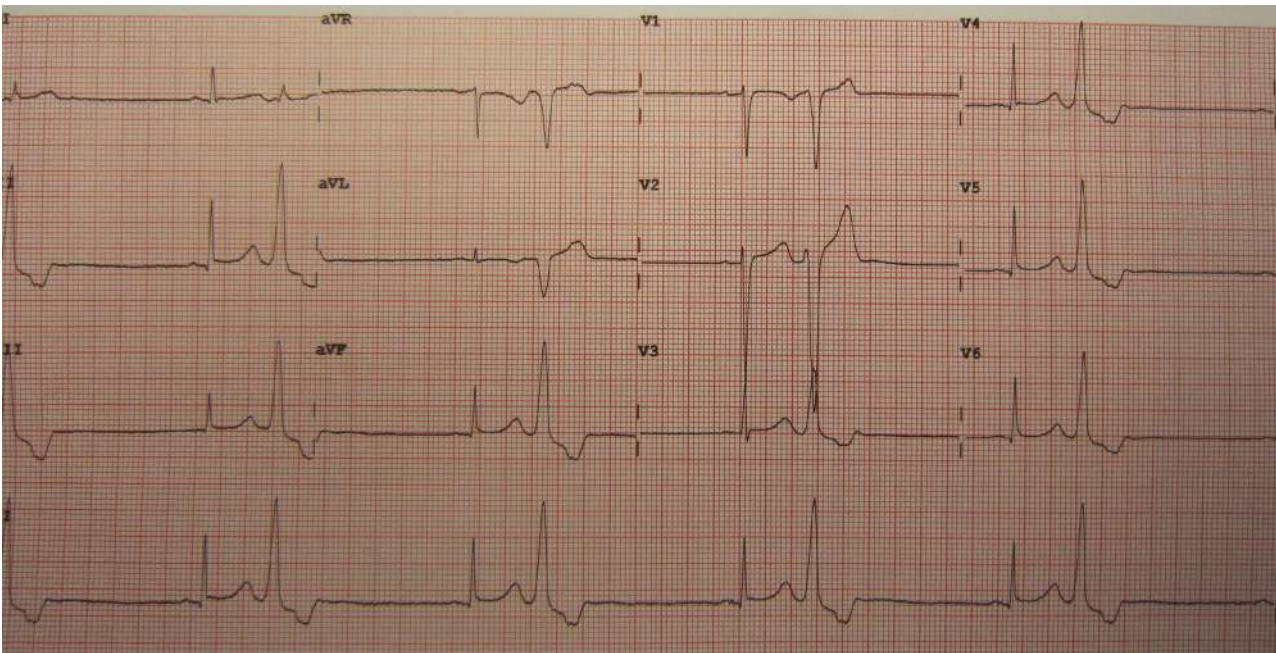
4. A 53-year-old man with hyperlipidemia comes to the physician for a follow-up examination. His home medications include acetaminophen and atorvastatin. Serum studies show elevated total cholesterol and triglyceride concentrations. A drug that activates the peroxisome proliferator-activated receptor alpha is added to his existing therapy. This patient is most likely to develop which of the following drug-related adverse effects?

- A. Waxing and waning confusion
- B. Reddish-brown discoloration of urine
- C. Pruritus and flushing of the skin
- D. Acutely swollen and painful joint

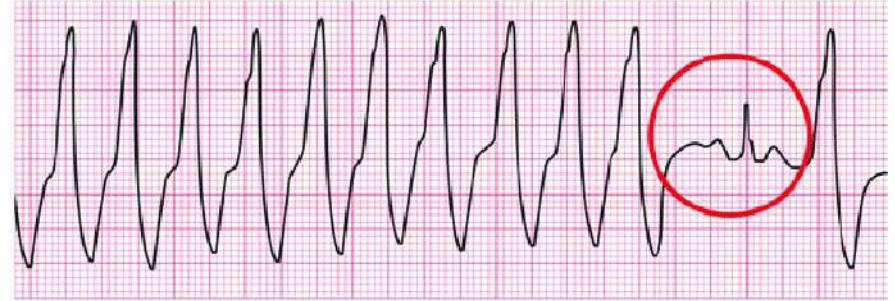5. A 17-year-old boy presents with sudden-onset palpitations and light headedness while playing video games. He states this has occurred intermittently over the past year, but the episodes typically resolve spontaneously after a few minutes. He denies chest pain, shortness of breath, or syncope. ECG is shown below. Which of the following abnormalities is most likely present in this patient?



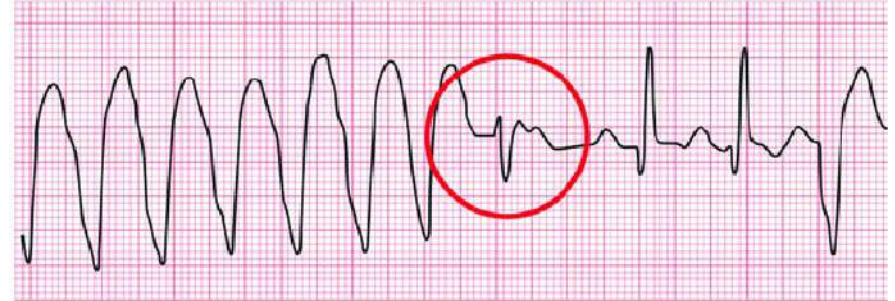
- A. Accessory pathway bypassing the AV node
- B. Degeneration of the atrioventricular conduction system
- C. Ectopic atrial pacemaker activity
- D. Dysfunction of the sinoatrial node



Capture beat:

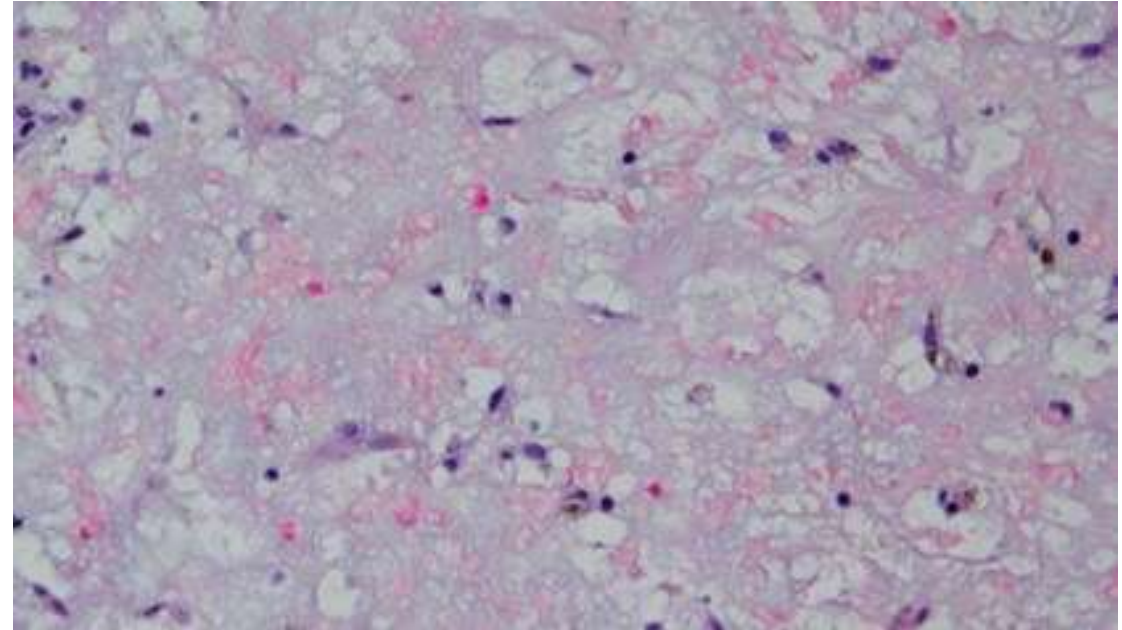


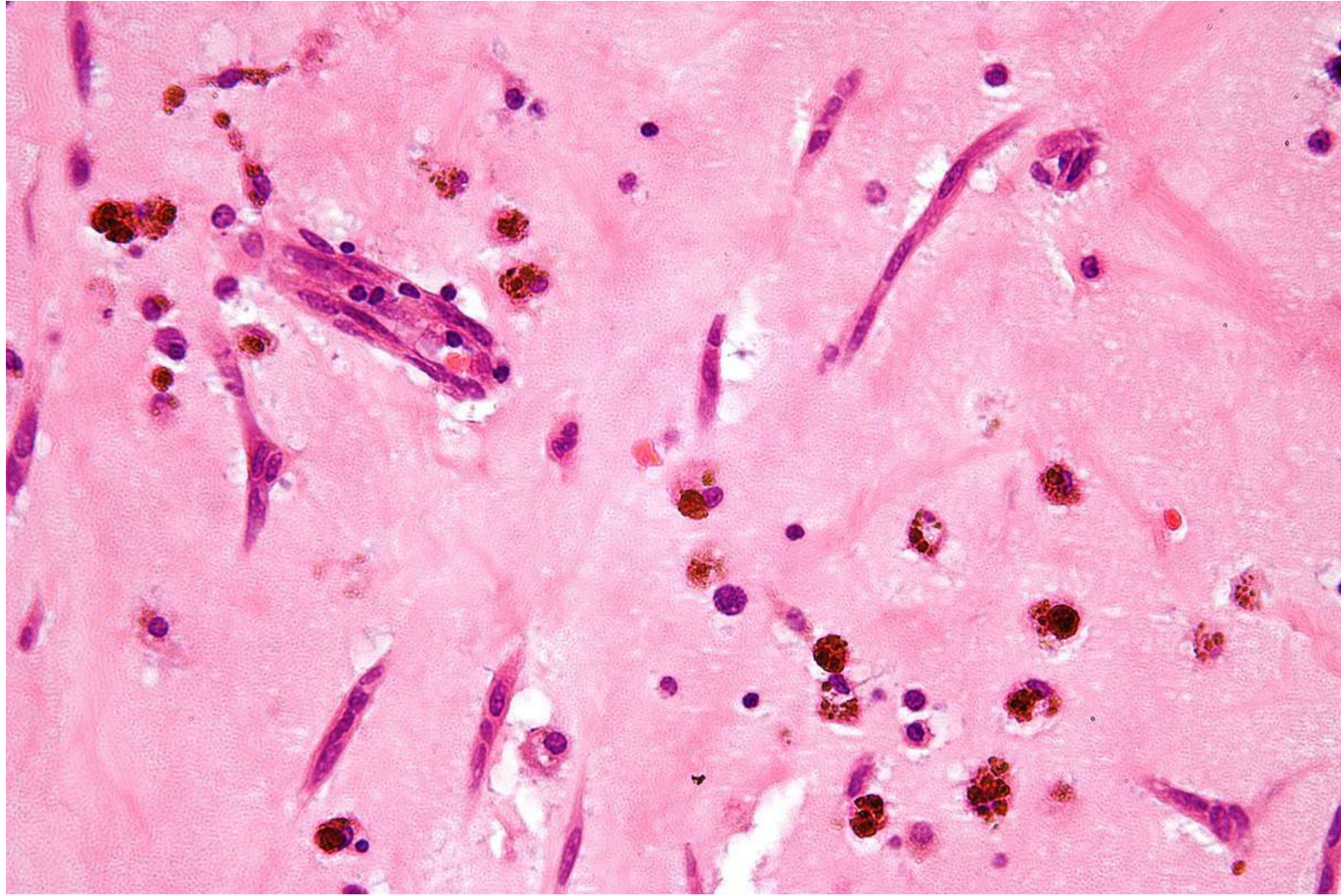Fusion beat:



6. A 35-year-old woman is brought to the emergency department due to severe right leg pain. Right-sided dorsalis pedis and posterior tibial pulses are absent, and the popliteal pulse is barely palpable. Emergency embolectomy is performed and a gelatinous mass causing arterial occlusion is successfully removed. Histopathologic section of the mass is shown in the image below. Which of the following is the most likely origin of this patient's embolus?

- A. Femoral vein
- B. Descending aorta
- C. Left atrium
- D. Left ventricle





7. Which of the following statements is true about beta blockers:

- 1. Carvedilol is the most widely used beta blocker.**
- 2. These are drug of choice in acute decompensated heart failure.**
- 3. Pindolol would be less likely to induce severe bradycardia in comparison to the other β -blockers.**
- 4. Sotalol can prolong the AP duration leading to torsade's de pointes.**

A. 1, 2, 3, 4

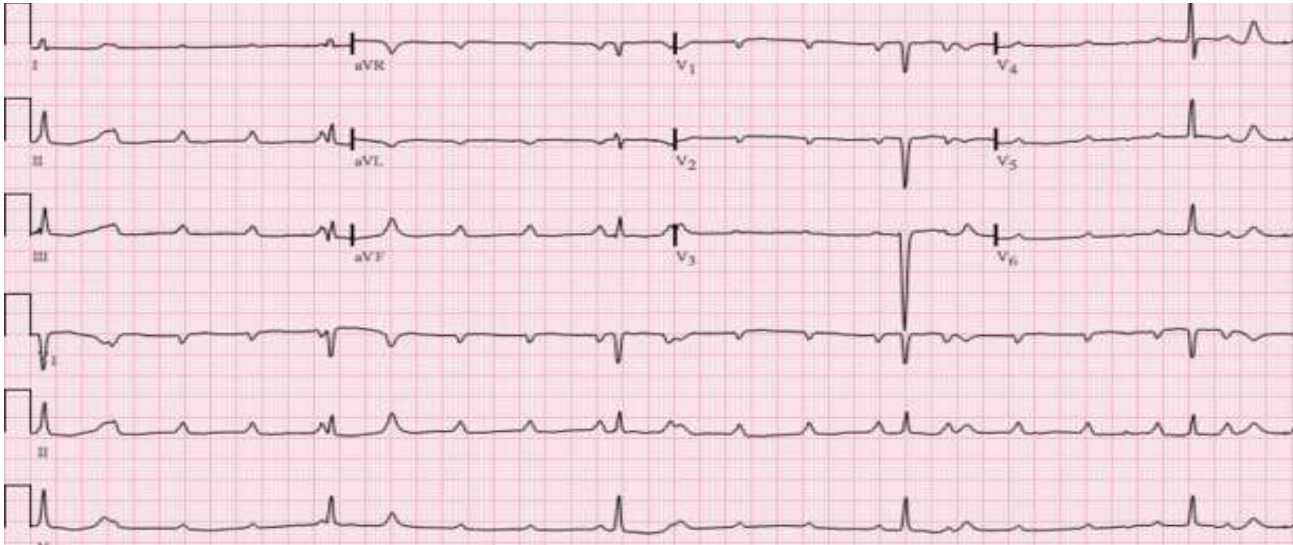
B. 3, 4

C. 1, 3, 4

D. 2, 4

ISA—Acebutolol, Celiprolol, Pindolol, Carteolol, Labetalol (A+B)

8. 67-year-old man comes to the emergency department with light-headedness and generalized weakness for the last 2 days. He has chronic stable angina with exertion. However, over the last 2 days he has also had occasional chest discomfort at rest. The patient's medical problems include hypertension and bronchial asthma. He has no shortness of breath, cough, or peripheral edema. His only medications are aspirin and isosorbide dinitrate. Blood pressure is 105/66 mmHg. Electrocardiogram obtained in the emergency department is shown here.

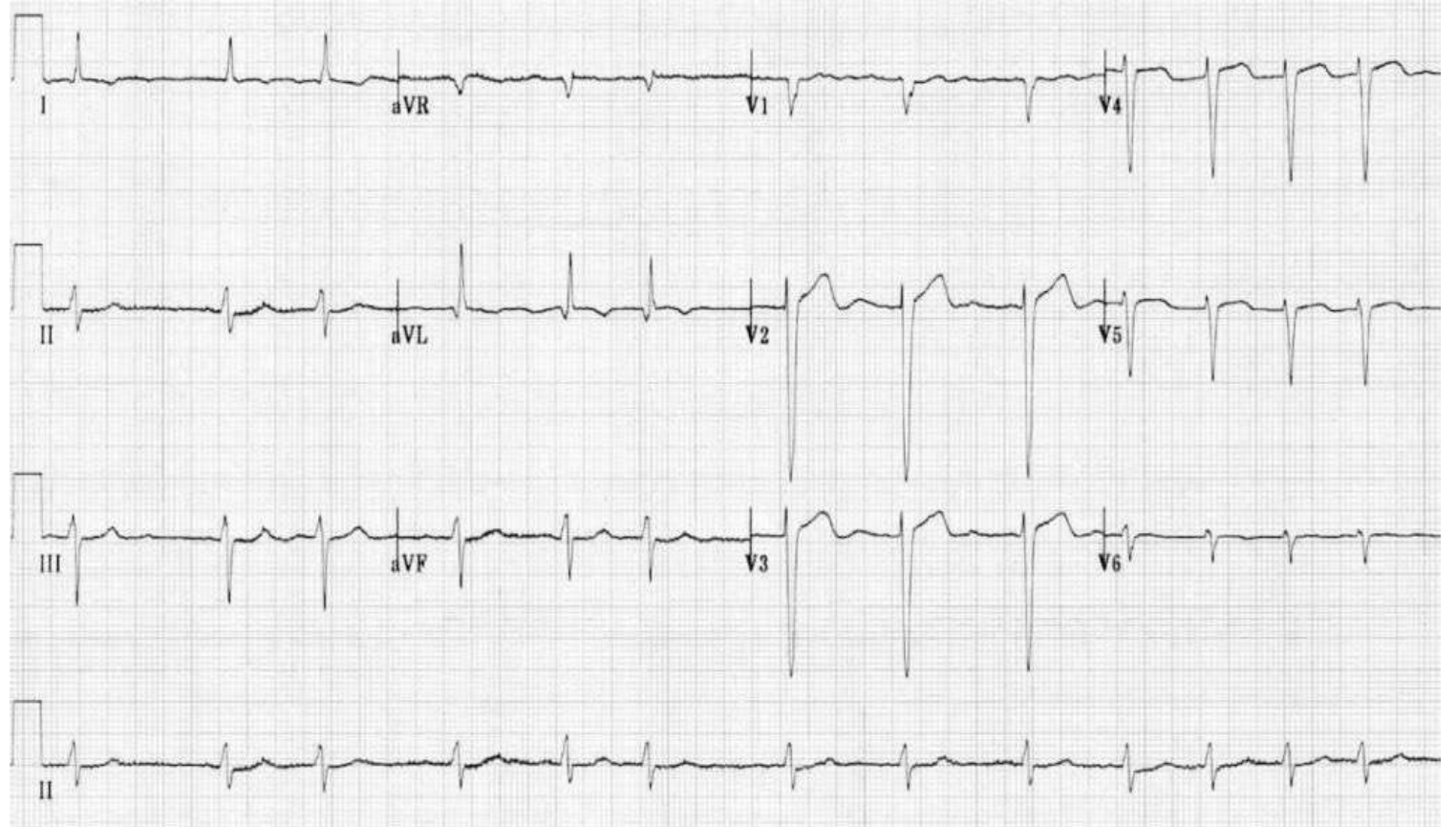


Which of the following is the best next step in management of this patient?

- A. Adenosine
- B. Cardiac pacing
- C. Digoxin
- D. Fibrinolytic therapy

9. 64-year-old man with a history of hypertension and diet-controlled type 2 diabetes mellitus comes to the office due to generalized malaise and palpitations for the past 2 weeks. An echocardiogram last year showed mild left atrial dilation and left ventricular hypertrophy. The patient's medications include lisinopril and hydrochlorothiazide. Blood pressure is 170/90 mmHg. ECG is shown. Which of the following is the most appropriate next step in management of this patient?

- A. Adenosine
- B. Electric cardioversion
- C. Diltiazem
- D. Lidocaine



10. 35-year-old woman comes to the OPD for a routine physical examination. The patient reports occasional palpitations but has no other chronic medical problems. She has caries of right upper molar tooth and is due to have an extraction next week. She has no significant medical history but had been told that she has "a murmur." The patient's only medication is a daily oral contraceptive. She lives a sedentary lifestyle and reports no dyspnea on routine activity. She developed hives with use of trimethoprim-sulfamethoxazole in the past. Blood pressure is 120/70 mmHg and pulse is 70/min. Physical examination shows no jugular venous distension in the upright position. Normal vesicular breath sounds are heard on chest auscultation. A late systolic murmur heard over the apex prolongs with the Valsalva manoeuvre. Which of the following is recommended for this patient prior to the procedure?

- A. Intravenous ampicillin
- B. Intravenous cefazolin
- C. No antibiotics
- D. Oral amoxicillin

Indications of prophylaxis required before dental procedures at high risk of endocarditis:

1. Prosthetic heart valve
2. Prior endocarditis
3. Unrepaired congenital heart disease
4. Completely repaired congenital heart disease(<6month)
5. Incomplete repaired congenital heart disease
6. Valvulopathy after cardiac transplant

11. A 34-year-old woman comes to the office due to exertional dyspnea. The patient has a history of IgA nephropathy; she received hemodialysis for 2 years before undergoing kidney transplantation last month. Chest x-ray reveals cardiomegaly and pulmonary congestion. Further evaluation determines that her symptoms are likely due to persistence of the arteriovenous fistula that was used for hemodialysis. Which of the following physiologic changes in 1) cardiac output, 2) systemic vascular resistance and 3) venous return respectively are present in this patient due to the fistula?

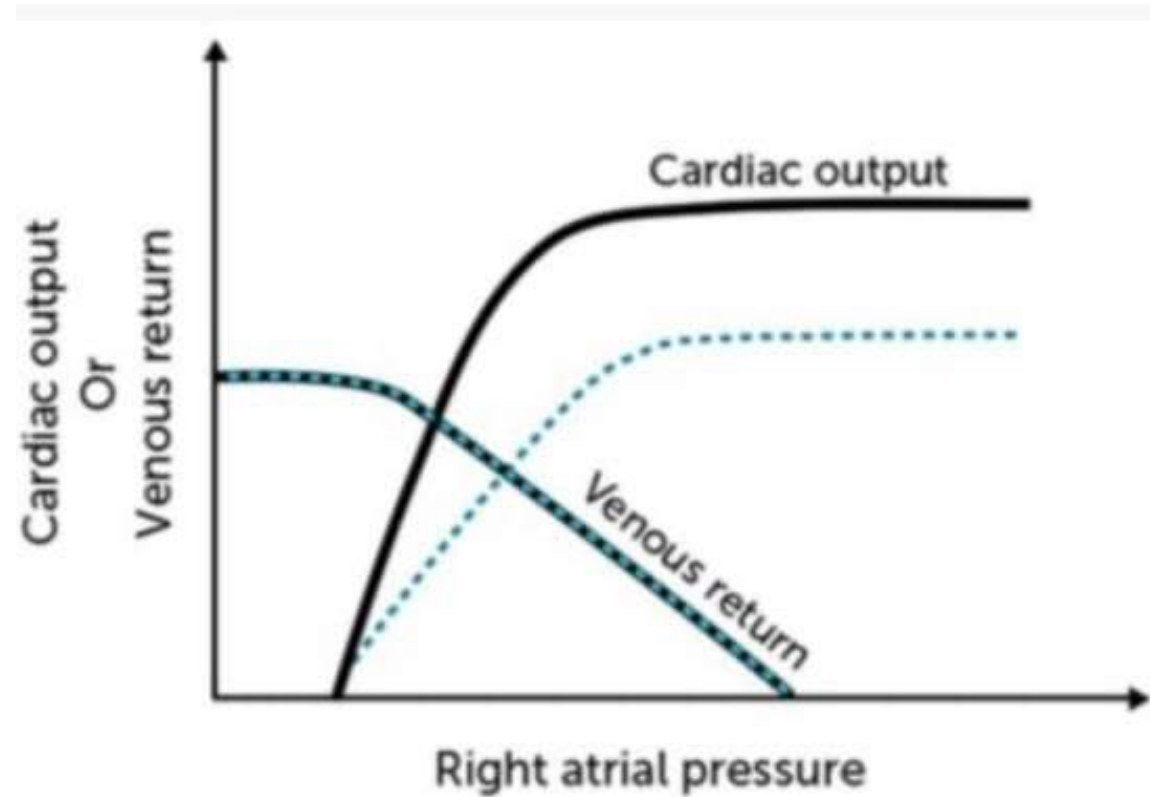
- A. Decreases, increases, decreases
- B. Decreases, increases, increases
- C. Increases, increases, decreases
- D. Increases, decreases, increases

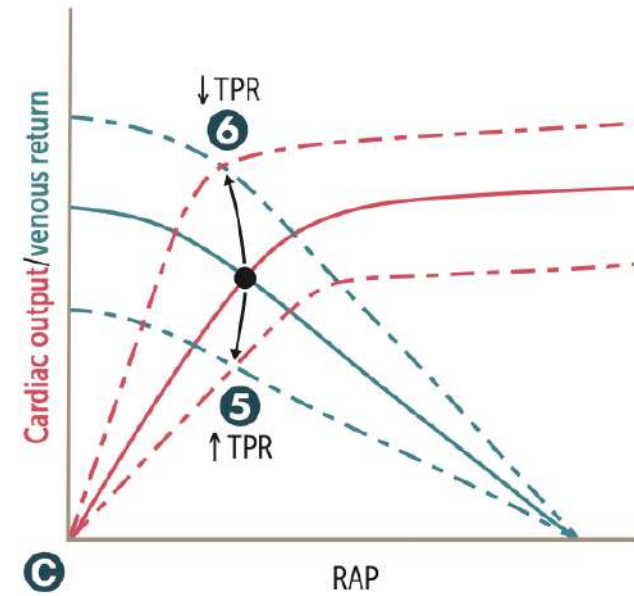
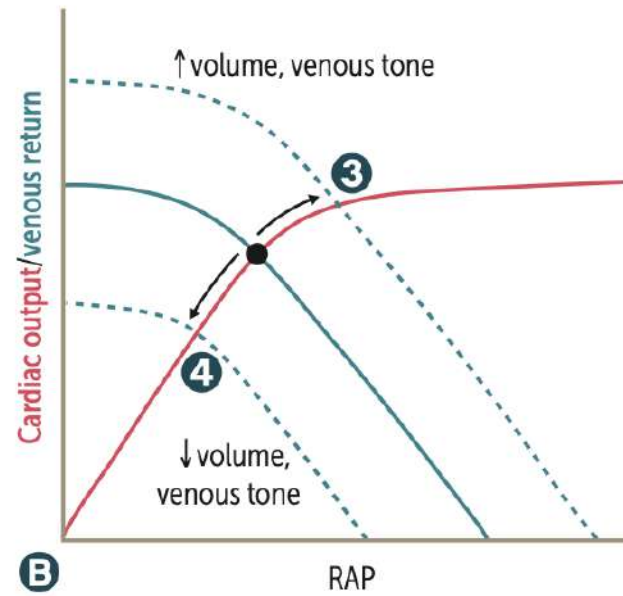
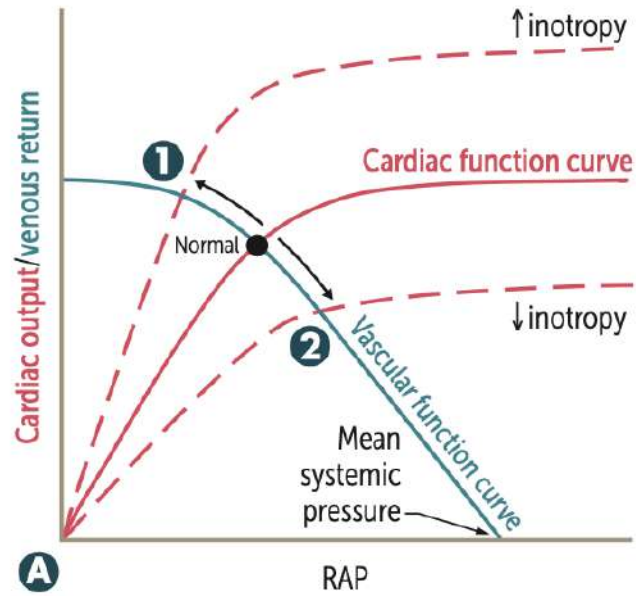
12. The true statement among the following is:

- A. The dose of telmisartan should be reduced in renal failure but not in hepatic failure.
- B. The dose of irbesartan should be reduced in case of mild-moderate hepatic failure and renal failure.
- C. The dose of candesartan should be reduced in mild-moderate liver failure but not in renal failure.
- D. Losartan acts as thromboxane A₂ antagonist and inhibits platelet aggregation.

13. The cardiac output and venous return curves of a healthy person are shown below with solid lines. Which of the following is the most likely cause of the change depicted by the dashed lines?

- A. Excessive hydration
- B. Acute hemorrhage
- C. Chronic anemia
- D. Myocardial infarction





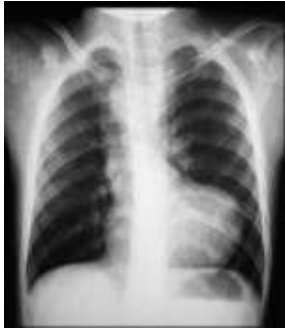- ① Catecholamines, dobutamine, digoxin, exercise ⊕
- ② HF with reduced EF, narcotic overdose, sympathetic inhibition ⊖

- ③ Fluid infusion, sympathetic activity, arteriovenous shunt ⊕
- ④ Acute hemorrhage, spinal anesthesia ⊖

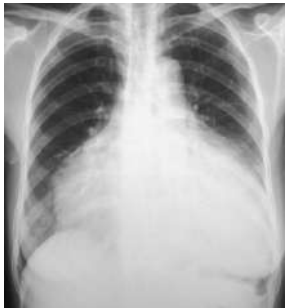- ⑤ Vasopressors ⊕
- ⑥ Exercise, arteriovenous shunt ⊖

14. A 28-year-old man comes to the emergency department with a 3-day history of increasing chest tightness and intermittent sharp chest pains. The patient has no prior chronic medical conditions but had an upper respiratory illness a week ago that resolved without treatment. ECG reveals sinus tachycardia and low voltage QRS complexes that vary in the amplitude from beat to beat. Which of the following is the most likely chest x-ray finding in this patient?

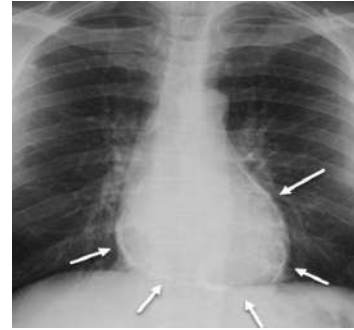
A.



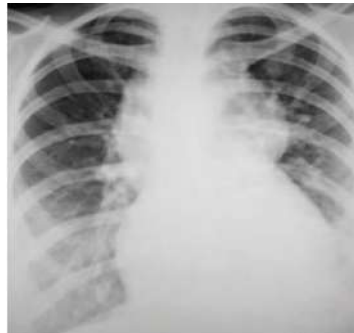
B.



C.



D.

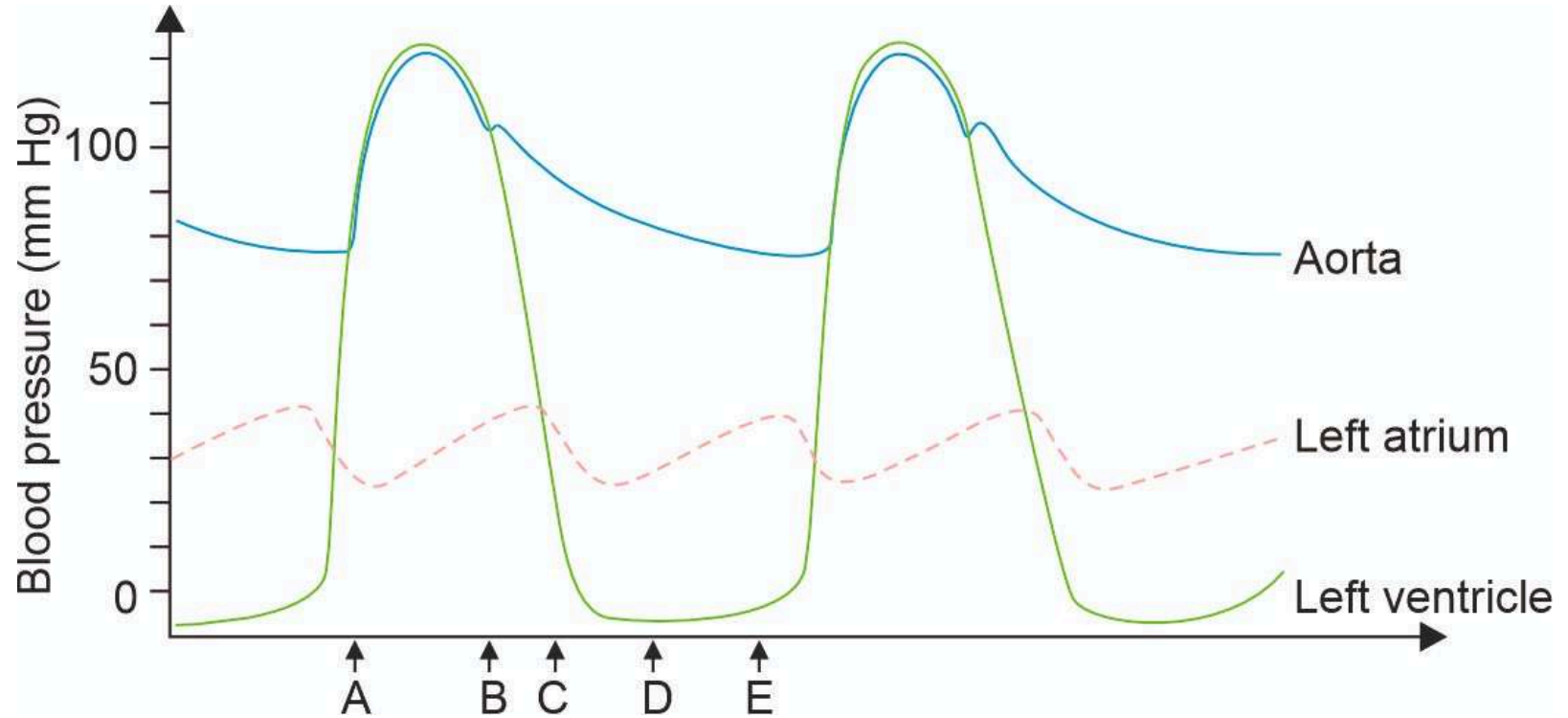


15. A 68-year-old man comes to the OPD due to several weeks of progressive exertional dyspnea and lower extremity edema. Echocardiography shows biventricular dilation and a left ventricular ejection fraction of 35%. After initial stabilization, long-term use of which of the following medications will most likely improve survival in this patient?

- A. Furosemide
- B. Amlodipine
- C. Carvedilol
- D. Digoxin

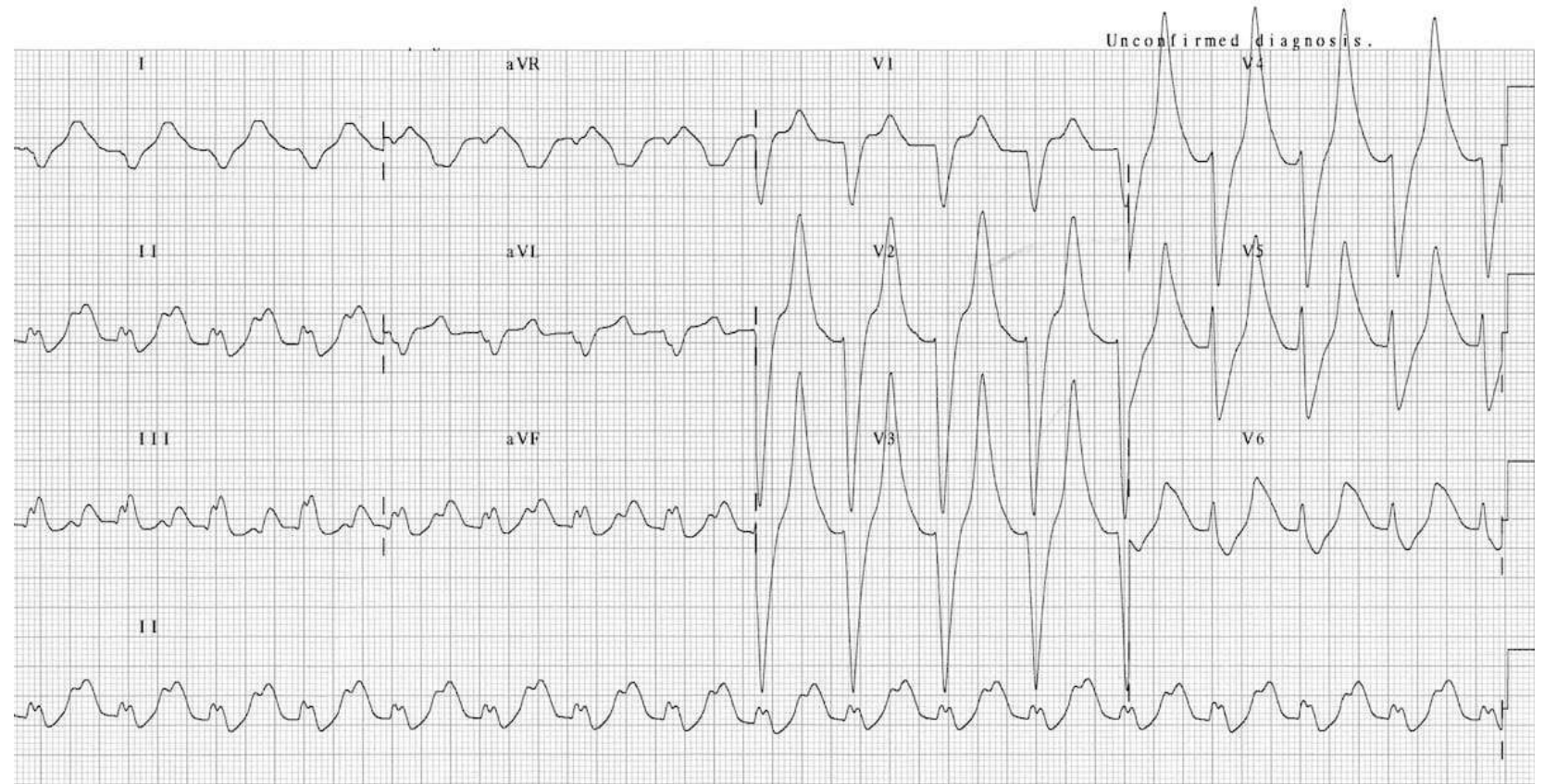
16. 32-year-old woman with a history of mitral stenosis comes to the OPD. Cardiac auscultation reveals an opening snap and a rumbling murmur heard best in the left fifth intercostal space at the midclavicular line. Timing of these sounds best corresponds to which of the following letters?

- A. A
- B. B
- C. C
- D. E




17. An elderly man with diabetic nephropathy presented to the emergency department with palpitations and chest discomfort. The ECG is shown below. What is the next step?

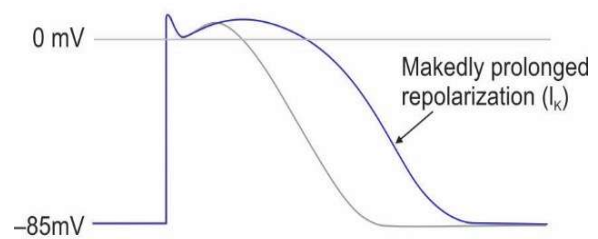
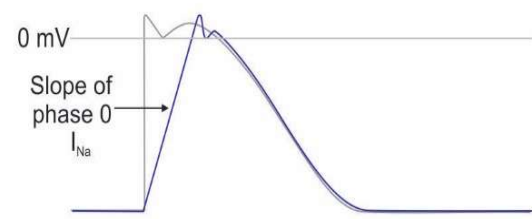
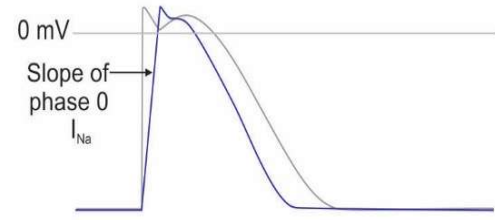
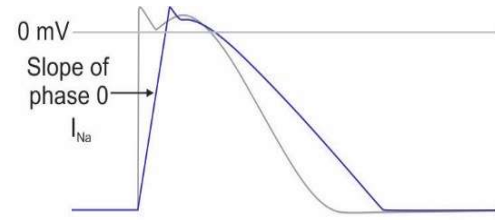
- A. Epinephrine
- B. Glucagon
- C. Atropine
- D. Lactic acid



18. 44-year-old man reports exertional shortness of breath and palpitations. On examination, he has a systolic murmur at the left sternal border and cardiac apex, which gets louder when he stands up. He is diagnosed with obstructive hypertrophic cardiomyopathy and paroxysmal atrial fibrillation and is started on a medication. Changes in the action potential of ventricular muscle cells before and after administration of medication are shown in the image below. The patient is most likely being treated with which of the following medications?

- A. Lignocaine
- B. Digoxin
- C. Diltiazem
- D. Disopyramide





Cell action potential

19. Deep y descent in JVP is seen in all except:

- A. Cardiac tamponade
- B. RCM
- C. Constrictive pericarditis
- D. Tricuspid regurgitation

20. Arrange the following phases of cardiac cycle in sequential order from systole to diastole:

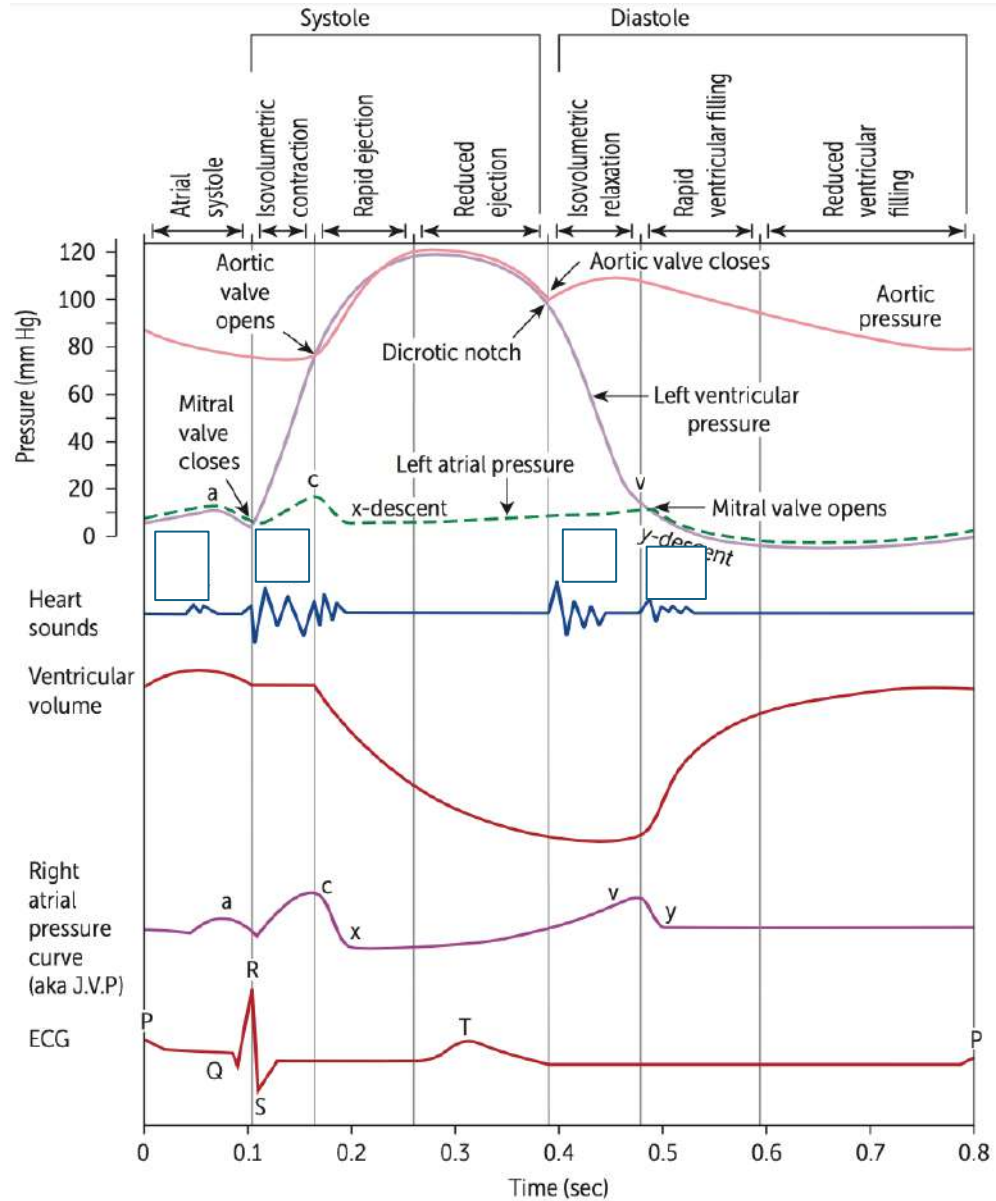
- 1. S1**
- 2. S4**
- 3. y descent**
- 4. R wave**

Options;

- A. 1-2-3-4
- B. 4-1-3-2
- C. 2-3-4-1
- D. 3-1-2-4

Wiggers diagram

P a4 QRS 1 cx T 2dn v 3y



21. A 34-year-old man develops severe chest and abdominal pain while shopping in a mall. Paramedics arrive and find him in severe distress. Several minutes later, he suffers a cardiac arrest with pulseless electrical activity and cannot be resuscitated. Postmortem examination reveals an internal hemorrhage as the cause of death. Histochemical evaluation of the patient's tissues reveals a defect affecting a large extracellular glycoprotein. This protein is normally found abundantly in large blood vessels, periosteum, and zonular fibers of the lens and functions to form microfibrils by surrounding elastin. This patient most likely suffered from which of the following conditions?

- A. Ehlers-Danlos syndrome
- B. Homocystinuria
- C. Marfan syndrome
- D. Osteogenesis imperfecta

22. The absence of loud S1 in mitral stenosis would indicate all of the following, except:

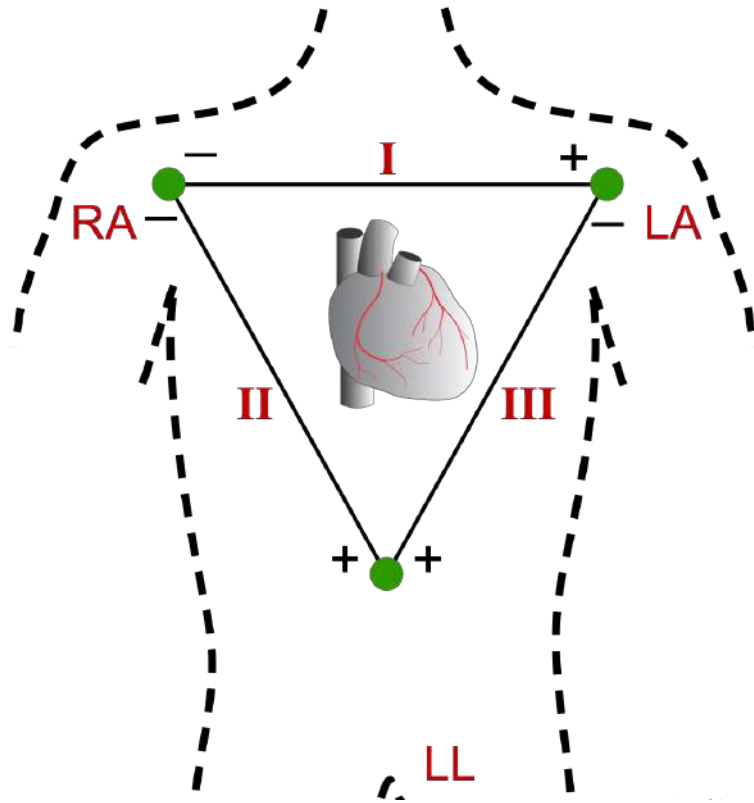
- A. Calcified valve
- B. Aortic regurgitation
- C. First degree heart block
- D. Mild mitral stenosis

Loud S1: MS, Reduced PR (WPW-Child), Hyperdynamic circulation

Soft S1: MR/TR, CHF, Calcified valves, Prolonged PR (1st degree heart block)

23. Which of the following is true regarding the placement of ECG leads?

- A. The earth to all leads is in the right leg
- B. Lead I: Positive pole to the right and negative pole towards the left
- C. Lead II: Positive pole on the left and negative pole towards the right
- D. Lead II: Positive pole on the right and negative pole towards the left



24. A 62-year-old woman comes to the emergency department due to palpitations and shortness of breath that began an hour ago. Medical history includes hypertension, coronary artery disease, and paroxysmal atrial flutter. Blood pressure is 108/76 mm Hg and pulse is rapid. ECG shows atrial flutter with a ventricular rate of approximately 150/ min. The estimated atrial rate based on ECG flutter waves is 300/min. Which of the following is most likely responsible for the rate difference between the atria and the ventricles?

- A. Calcium current within the atrioventricular node
- B. Calcium current within the sinoatrial node
- C. Sodium current within an atrioventricular accessory pathway
- D. Sodium current within the atria

25. A 65-year-old man is admitted to the hospital with an acute ST-segment elevation myocardial infarction. The patient undergoes coronary angiography with stent placement in the left circumflex artery, and he is started on therapy with a beta blocker and antiplatelet agents. On day 3 of hospitalization he experiences chest pain. The pain, described as sharp and radiating to his neck and shoulders, is exacerbated by coughing and swallowing. Temperature is 37.5 C (99.5 °F), blood pressure is 130/80 mmHg, pulse is 90/min and regular, and respirations are 20/min. The lungs are clear on auscultation. There is no peripheral edema. Which of the following is the most likely cause of this patient's chest pain?

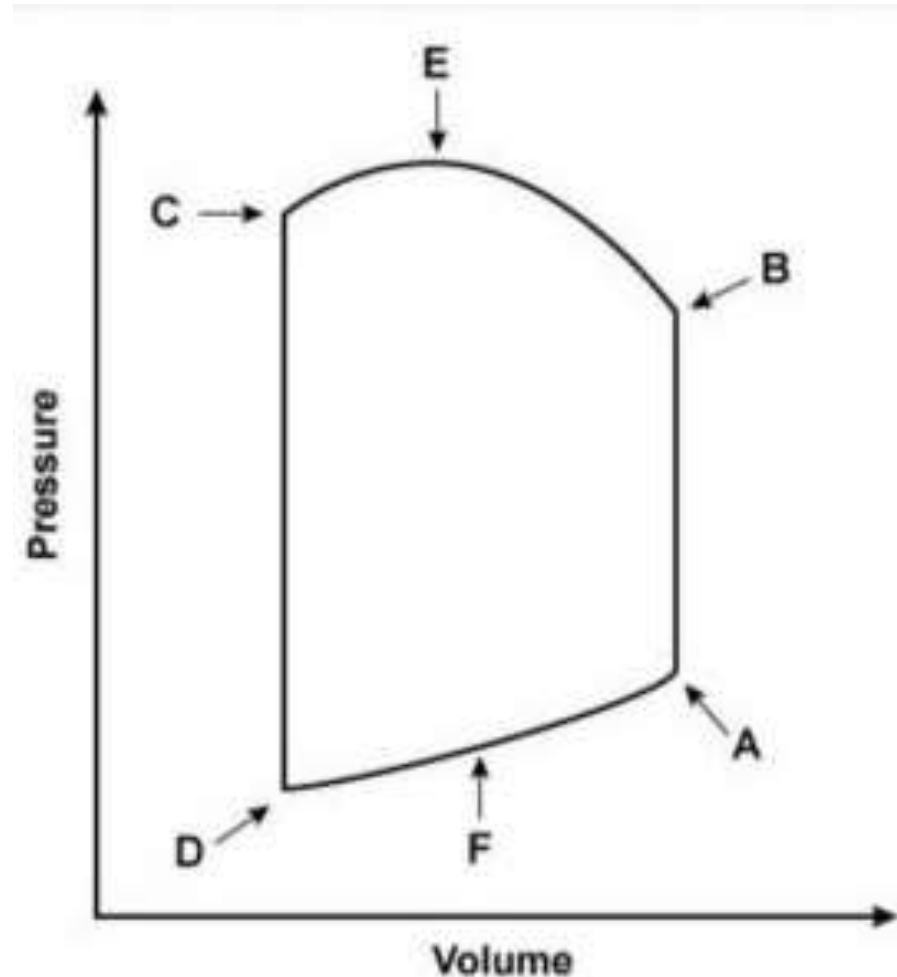
- A. Pericardial inflammation due to autoimmune reaction to necrotic tissue
- B. Pericardial inflammation due to concomitant viral infection
- C. Pericardial inflammation overlying the necrotic segment of myocardium
- D. Recurrent thrombosis of the culprit coronary vessel

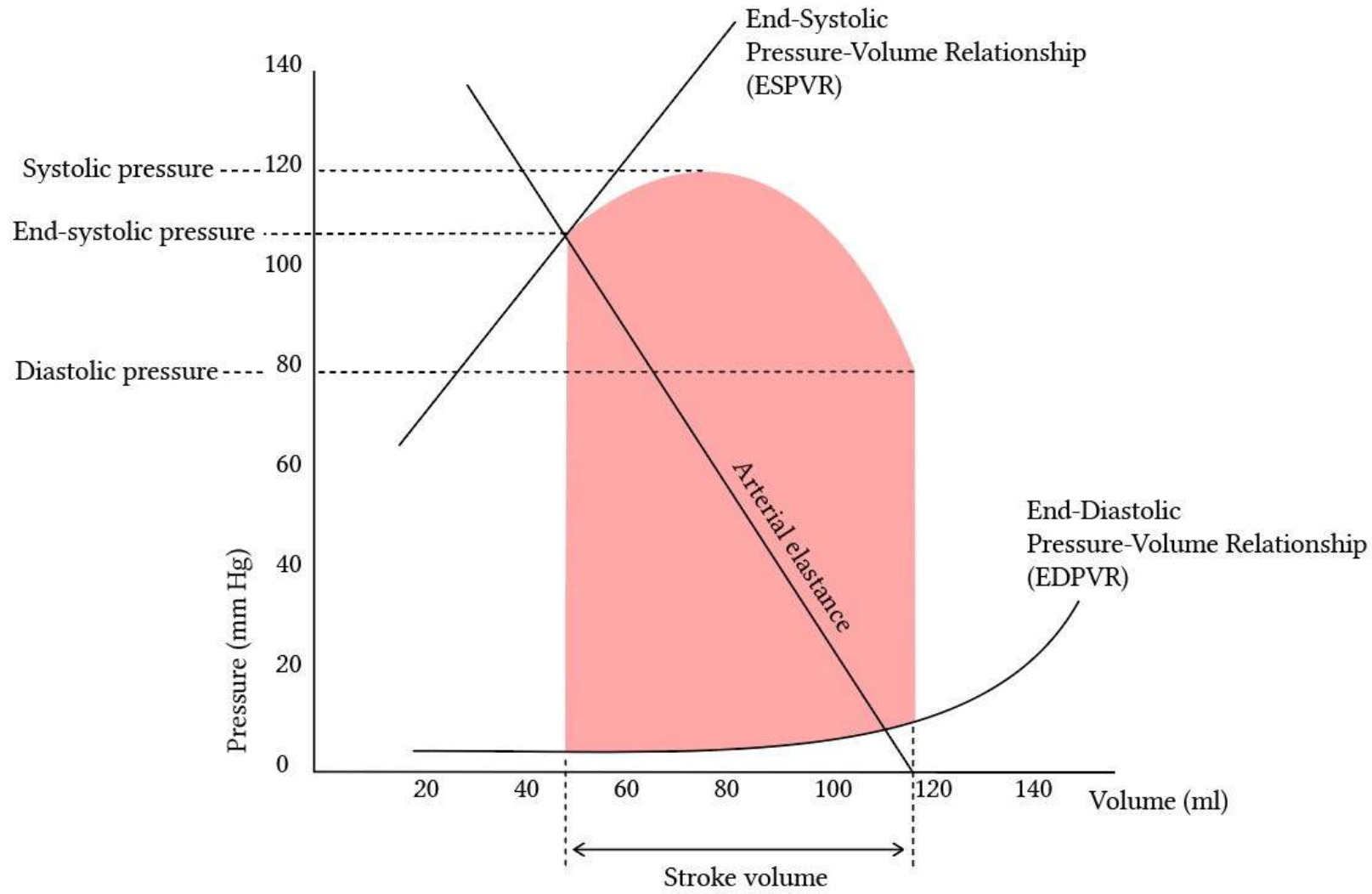
27. A 55-year-old man comes to the OPD due to recurrent episodes of retrosternal chest pain. The episodes occur during physical activity, usually when he climbs stairs or walks uphill, and resolve after he rests for a few minutes. He is prescribed sublingual nitroglycerin to take as needed when the chest pain occurs. This drug is most likely to relieve this patient's symptoms by causing which of the following hemodynamic changes?

- A. Decrease in heart rate
- B. Decrease in left ventricular end-diastolic volume
- C. Decrease in peripheral arteriolar resistance
- D. Increase in coronary blood flow

28. 34-year-old woman comes to the physician due to weakness, exertional dyspnea, and orthopnea. On cardiac auscultation, a snap followed by a rumbling diastolic murmur is heard over the cardiac apex. The snap most likely occurs nearest to which of the following points on the cardiac pressure-volume loop?

- A. A
- B. B
- C. C
- D. D





29. A 66-year-old man comes to the emergency department because of shortness of breath. His temperature is 37.2°C (99°F) and pulse is 105/min. When the blood pressure cuff is inflated to 140 mm Hg, the patient's pulse is audible and regular. However, upon inspiration, the pulse disappears and does not reappear until expiration. Only when the blood pressure cuff is inflated to 125 mm Hg is the pulse audible throughout the entire respiratory cycle. Which of the following underlying conditions is most likely responsible for this patient's physical examination findings?

- A. Mitral regurgitation
- B. Lobar pneumonia
- C. Hypertrophic cardiomyopathy
- D. Asthma

A 60-year-old man with a known history of diabetes mellitus presents with a BP of 150/90 mmHg and dizziness. What is the best way to manage this patient?

- A. Diet, Exercise, Lifestyle modification + Metoprolol
- B. Diet, Exercise, Lifestyle modification
- C. Diet + Prazosin
- D. Diet, Exercise, Lifestyle modification + Amlodipine

Hypertension

Category	SBP	DBP
Normal	<130	<85
High-normal	130-139	85-89
Grade 1 hypertension	140-159	90-99
Grade 2 hypertension	>160	>100

Blood Pressure Category	Systolic BP (mm Hg)	Diastolic BP (mm Hg)
Normal	Less than 120	Less than 80
Elevated	120-129	Less than 80
Stage 1 Hypertension (High BP)	130-139	80-89
Stage 2 Hypertension (High BP)	140 or higher	90 or higher
Severe Hypertension	Higher than 180	and/or higher than 120

Emergency: Severely elevated BP with acute hypertension mediated organ damage (HMOD)

Urgency: Severely elevated BP without acute hypertension mediated organ damage (HMOD)

**Hypertension with:
DM / CKD/ Scleroderma-
Osteoporosis/ Renal stones-
Raynaud/ Cyclosporine induced-
BPH-
Migraine/ Thyrotoxicosis/ Angina/ Tremor-**

31. A 74-year-old man comes to the physician for a 6-month history of progressively worsening fatigue and shortness of breath on exertion. His pulse is 89/min and blood pressure is 145/60 mm Hg. Crackles are heard at the lung bases. Cardiac examination shows a grade 3/6 early diastolic murmur loudest at the left sternal border in the third intercostal space. Further evaluation of this patient is most likely to show which of the following?

- A. Pulsus parvus et tardus
- B. Pulsus paradoxus
- C. Fixed splitting of S2
- D. Water hammer pulse

32. A previously healthy 52-year-old woman comes to the physician because of a 3-month history of chest pain on exertion. She takes no medications. Cardiopulmonary examination shows no abnormalities. Cardiac stress ECG shows inducible ST-segment depressions in the precordial leads that coincide with the patient's report of chest pain and resolve upon cessation of exercise. Pharmacotherapy with verapamil is initiated. This drug is most likely to have which of the following sets of effects?

- A. End diastolic volume (EDV) increase, BP decrease, Contractility decrease, HR decrease
- B. End diastolic volume (EDV) decrease, BP decrease, Contractility decrease, HR decrease
- C. End diastolic volume (EDV) increase, BP no change, Contractility increase, HR decrease
- D. End diastolic volume (EDV) decrease, BP increase, Contractility decrease, HR no change

33. A 52-year-old man with a history of type 2 diabetes mellitus managed with diet and exercise undergoes treadmill stress testing for complaints of intermittent fatigue. He reports no chest pain during the test but stops after 6 minutes due to exertional

- **Vitals:**

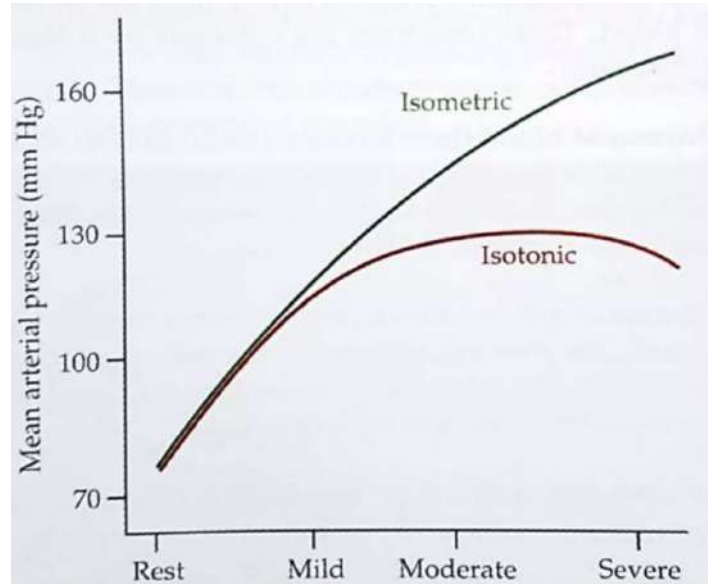
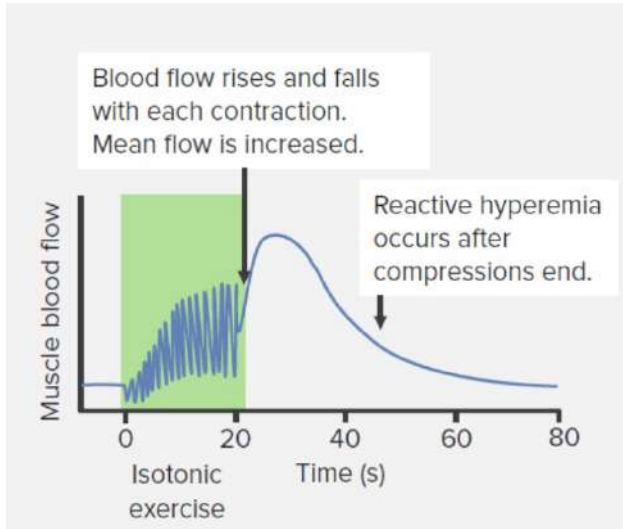
- Resting heart rate: 72/min; peak stress heart rate: 138/min
- Resting blood pressure: 120/75 mm Hg; peak stress: 135/82 mm Hg.

- **ECG shows normal sinus rhythm without ischemic changes.**

- **Physical exam and echocardiogram at rest are unremarkable.**

During exercise, which of the following hemodynamic parameters is most likely to be decreased compared to the resting state?

- A. Cardiac output
- B. Left ventricular end-diastolic pressure
- C. Systemic systolic blood pressure
- D. Total systemic vascular resistance



Isotonic exercise:

CO:

HR:

SV:

SBP:

TPR:

DBP:

MAP:

Isometric exercise:

CO:

HR:

SV:

SBP:

TPR:

DBP:

MAP:

34. A 60-year-old woman is brought to the emergency department due to severe central chest pain that started a few hours ago. ECG shows ST-segment elevation in leads I, aVL, and V1–V4, along with deep Q wave formation over the next several hours. Cardiac catheterization would most likely reveal which of the following?

- A. Atherosclerotic plaque obstructing 50% of the coronary artery lumen, no thrombus
- B. Atherosclerotic plaque obstructing 80% of the coronary artery lumen, no thrombus
- C. Ruptured atherosclerotic plaque with fully obstructive thrombus
- D. Significant coronary artery vasospasm causing flow obstruction

35. A 76-year-old man is admitted to the hospital due to worsening dyspnea and fatigue. He has a history of chronic atrial fibrillation and heart failure with reduced ejection fraction (HFrEF). The patient is started on oral digoxin for rate control. A week later, his serum digoxin level is measured and found to be markedly elevated, despite receiving an appropriate dose. Upon further questioning, it is discovered that the patient was recently started on amiodarone. Which of the following mechanisms best explains the interaction between the drugs?

Options:

- A. Blockade of biliary transport proteins
- B. Induction of cytochrome P-450 enzymes
- C. Inhibition of P-glycoprotein
- D. Stimulation of Na⁺/K⁺-ATPase

Amiodarone, verapamil, quinidine, cyclosporine, and clarithromycin

36. Below (proximal) the carotid sinus, carotid artery clamping is likely to result in:

- A. Increase in a vasomotor centre activity
- B. Increase in the discharge of carotid sinus afferent nerves
- C. Decreased heart rate and blood pressure
- D. Baroreceptor adaptation

37. Oxygen sensitive channels in peripheral chemoreceptors are for which of the following ion? (FMGE JULY 2024)

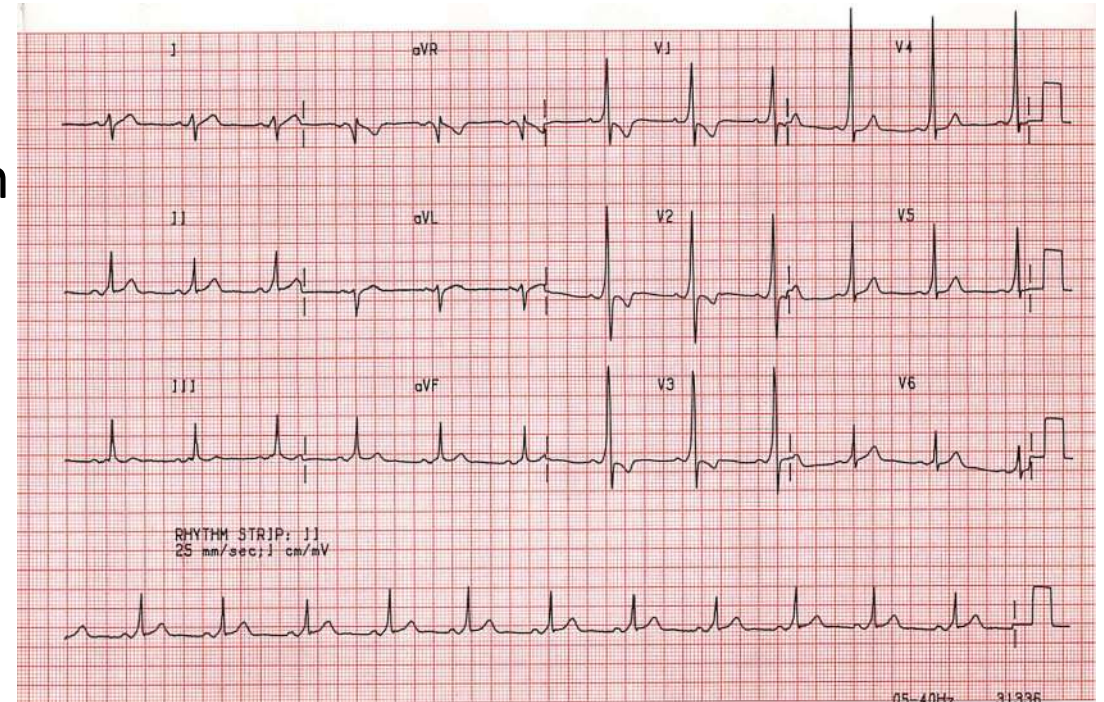
- A. K^+
- B. Na^+
- C. HCO_3^-
- D. Cl^-

38. A 65-year-old man with a long history of hypertension and type 2 diabetes presents to the clinic complaining of dizziness and weakness in his left arm when performing activities like playing table tennis. He has been a chronic smoker for over 40 years. ECG shows normal sinus rhythm, and orthostatic vital signs are normal. A Doppler ultrasound of the left vertebral artery shows retrograde flow instead of normal antegrade flow. Which of the following arteries is most likely stenosed or occluded to cause these findings?

- A. Left internal carotid artery
- B. Left vertebral artery
- C. Left subclavian artery
- D. Right subclavian artery

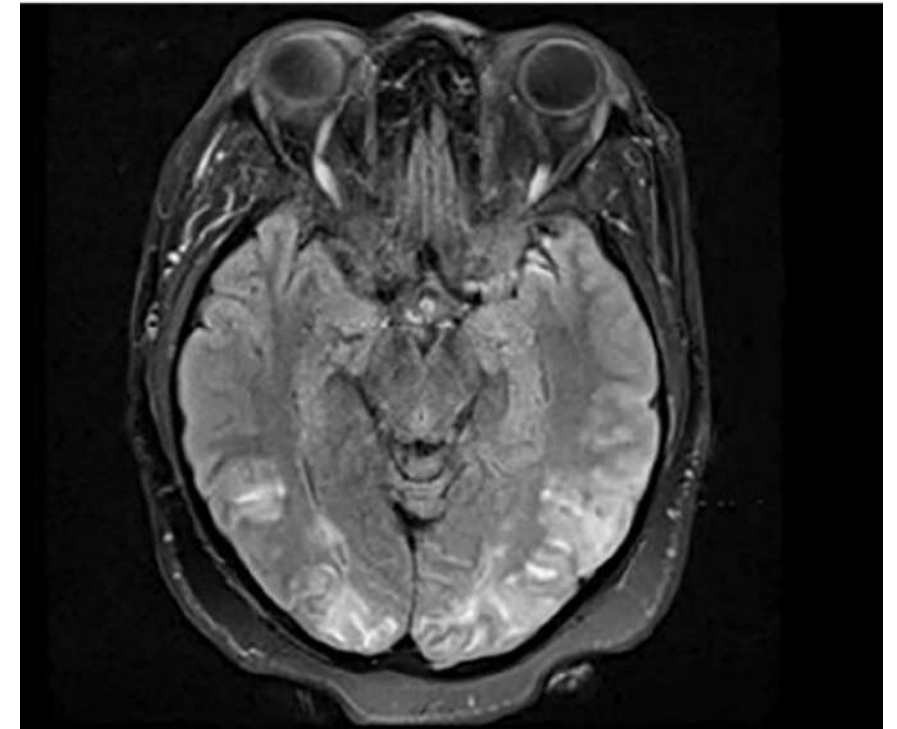
39. A 17-year-old boy presents with sudden-onset palpitations and lightheadedness while playing video games. He states this has occurred intermittently over the past year, but the episodes typically resolve spontaneously after a few minutes. He denies chest pain, shortness of breath, or syncope. ECG is shown below. Which of the following abnormalities is most likely present in this patient?

- A. Accessory pathway bypassing the AV node
- B. Degeneration of the atrioventricular conduction system
- C. Ectopic atrial pacemaker activity
- D. Dysfunction of the sinoatrial node



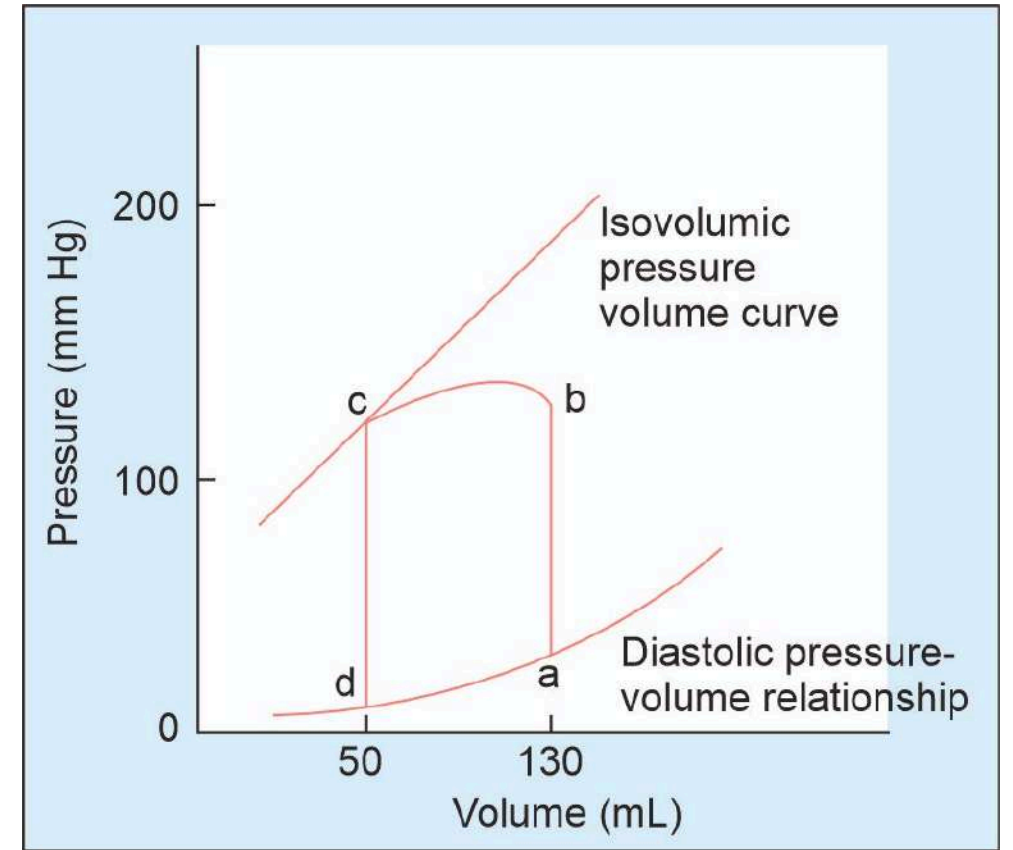
40. A 24-year-old G2 at 28 weeks is brought to the emergency after being found unconscious at home by her mother. She is disoriented on arrival and her BP is 180/110 mmHg and 4 + proteinuria. On arrival at the emergency, she has a tonic-clonic seizure which resolves with MgSO₄ administration. Once the patient is stabilized, she undergoes caesarean delivery for fetal distress. Post-partum, the below MRI is done. What is the most likely finding on imaging?

- A. Subdural hematoma
- B. Parenchymal hemorrhage
- C. Subarachnoid hemorrhage
- D. Posterior reversible encephalopathy syndrome



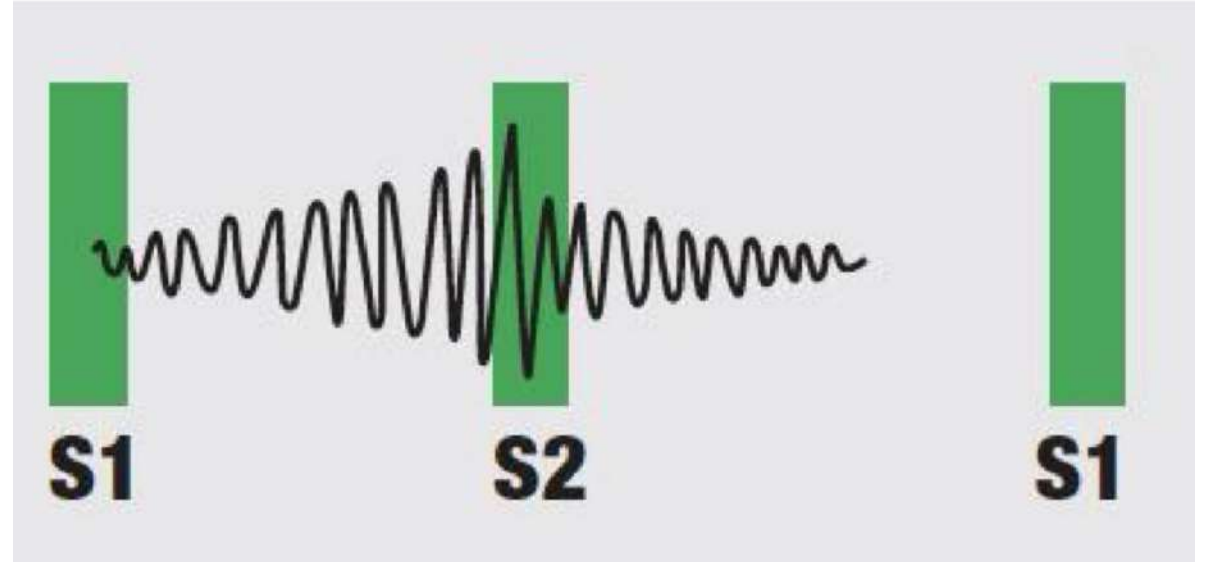
41. Which point in the following diagram indicates that the left ventricular pressure is equivalent to the diastolic blood pressure?

- A. a
- B. b
- C. c
- D. d



42. The following pattern of murmur is seen in all except:

- A. VSD with aortic regurgitation
- B. Coronary AV fistula
- C. Rupture of sinus of Valsalva aneurysm
- D. PDA



43. A 45-year-old female patient has NYHA class III heart failure, with dyspnea, pedal edema and K⁺ levels of 5.5mg% and creatinine 1.1 mg%. Which of the following drugs can be used in this patient? (AIIMS NOV 2017)

- A. Digoxin
- B. Spironolactone
- C. Enalapril
- D. Furosemide

K sparing diuretics

ACE-/ARB

B blockers

Calcineurin inhibitors

Digoxin

Pentamidine

NSAIDs

Sch

Heparin

Trimethoprim

44. Which of the following is not a component of Syndrome Z in a 45-year old Indian man?

- A. Blood pressure 145/89mmHg
- B. Obstructive sleep apnea
- C. Waist circumference of 88cm
- D. Fasting triglyceride 160 mg/dl

Metabolic syndrome: NCEP-ATP III

1. Central obesity:

>102 cm (India-90cm) in men

>88 cm (India-80cm) in women

2. Elevated triglycerides: >150 mg/dL

3. HDL

< 40 mg/dL in men

< 50 mg/dL in women.

4. Blood pressure: >130/85 mm Hg

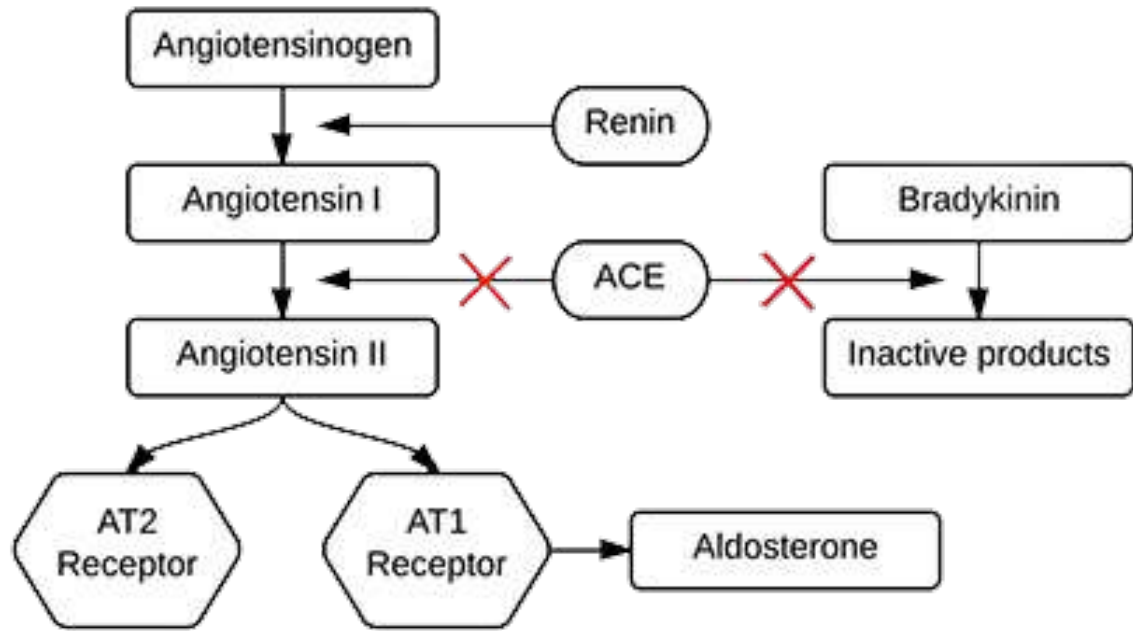
5. Fasting glucose: >100 mg/dL

45. Which of the following is responsible for the bradycardia seen in Cushing reflex?

- A. Heart failure
- B. Baroreceptor activation
- C. Cardiac conduction defect
- D. Increased activity of RVLM

46. A 56-year-old man with hypertension comes to the physician for a follow-up examination. His blood pressure is 165/92 mm Hg on the left arm and 162/90 mm Hg on the right arm. He reports that he is adherent with his medication and exercise regimen. The physician adds a drug to his antihypertensive medication regimen. This drug increases serum renin, angiotensin I, and angiotensin II levels, and decreases serum aldosterone levels, without affecting bradykinin levels. Which of the following drugs was most likely added to this patient's medication regimen?

- A. Candesartan
- B. Aliskiren
- C. Verapamil
- D. Lisinopril

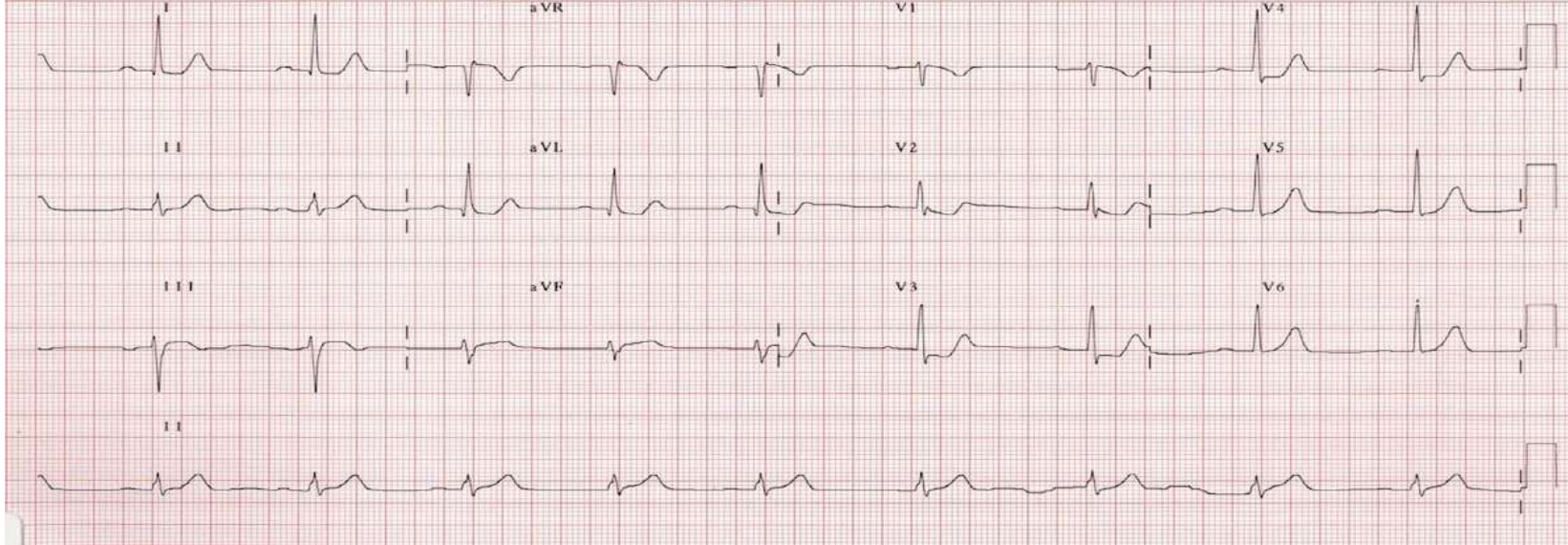


✗ = Site of ACEI Action

vasoconstriction, aldosterone secretion, renal sodium retention, and sympathetic nervous system activation.

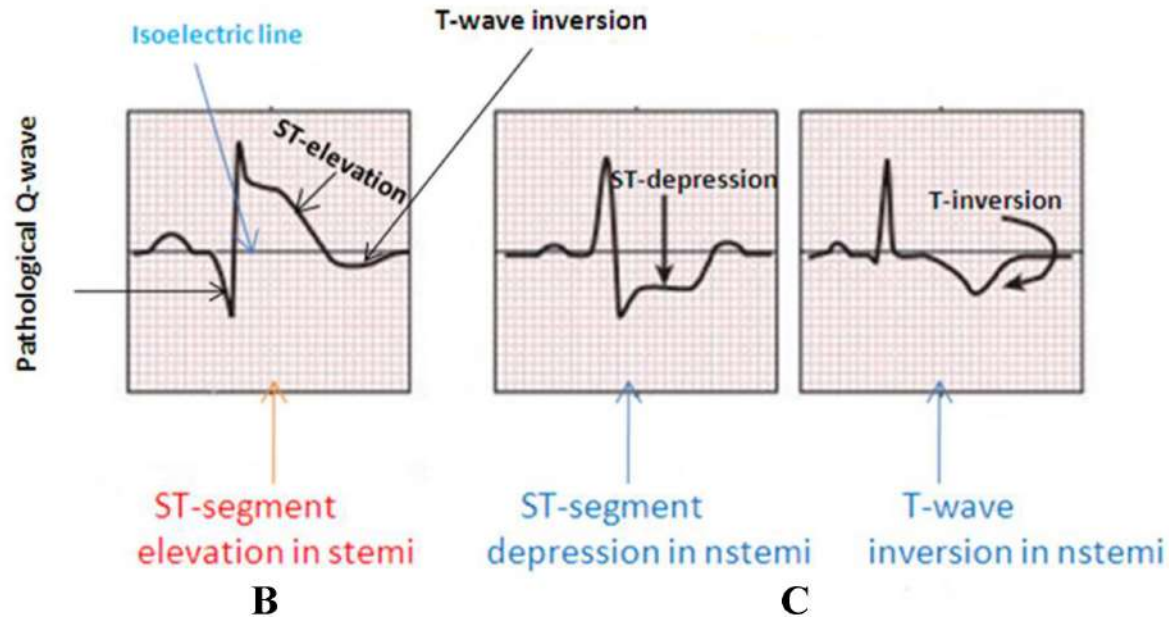
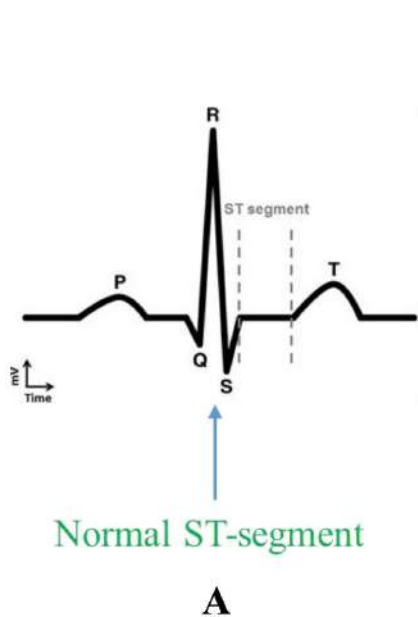
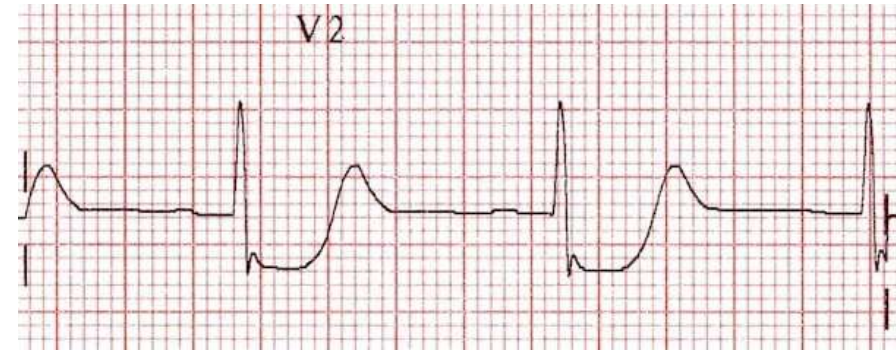
Fetal, reproductive, brain: Vasodilation, anti-proliferation, apoptosis, tissue repair

47. A 55-year-old man presented with chest pain and shortness of breath. An ECG was taken in the emergency and was shown. What is the likely diagnosis?



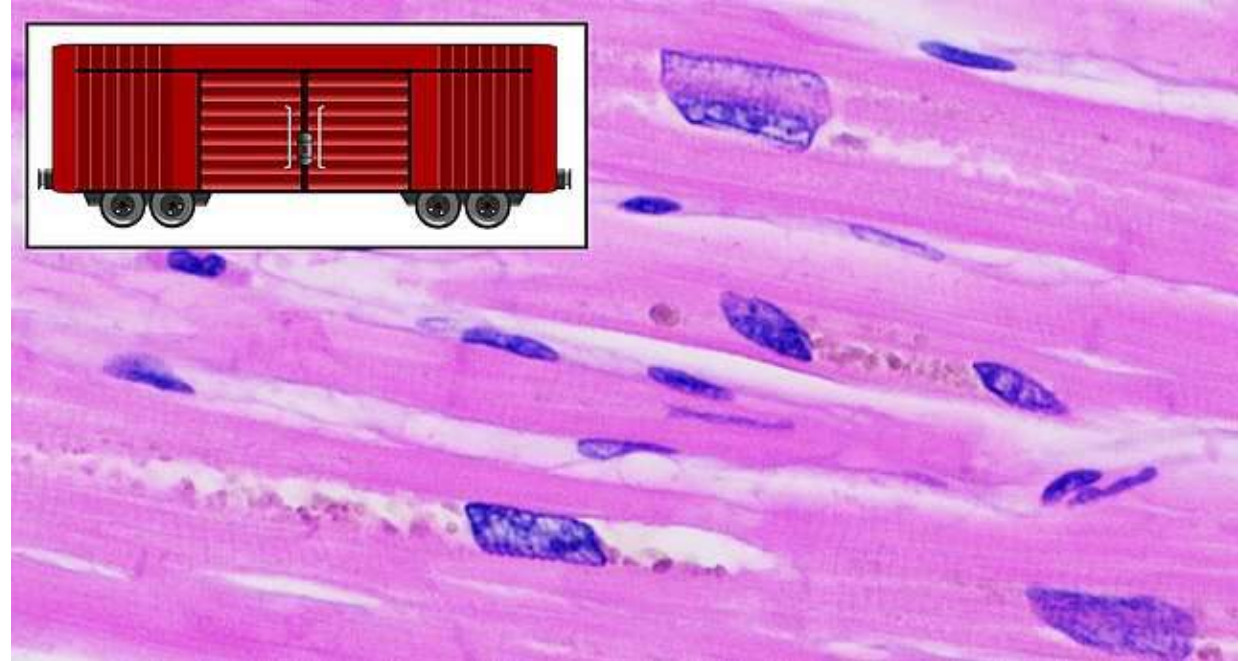- A. NSTEMI
- B. Unstable Angina
- C. Posterior MI
- D. Acute Myocarditis

- The ECG shows:
 - **ST segment depression** in leads V1 to V3
 - **Tall, broad R waves** in V1–V3
 - **Upright T waves** in these leads



48. Which of the following conditions is associated with box car nuclei seen on histopathological examination of the myocytes?

- A. Restrictive cardiomyopathy
- B. Hypertrophic cardiomyopathy
- C. Hypertensive cardiomyopathy
- D. Subendocardial ischemia



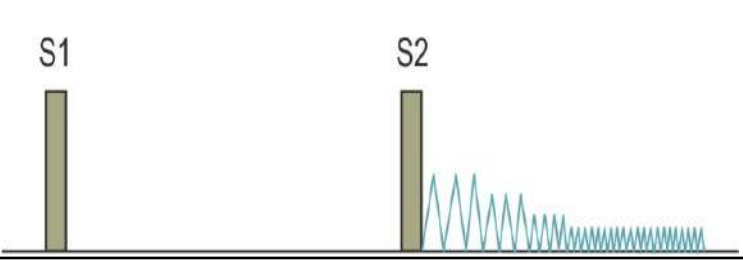
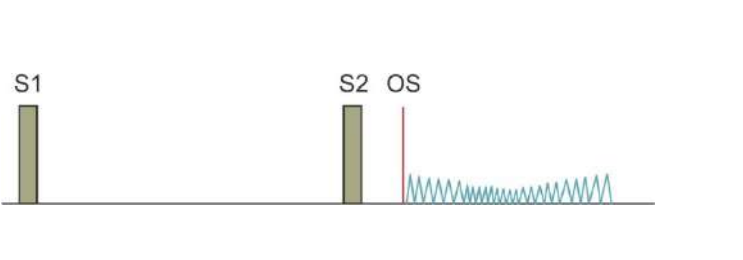
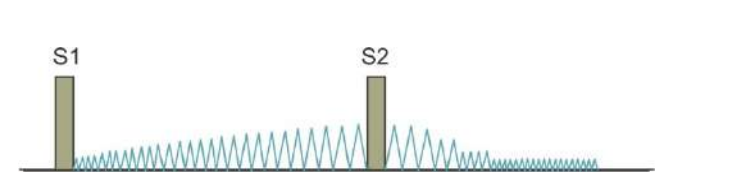
49. A 52-year-old male presents with headache, confusion, visual disturbances, nausea, vomiting and seizures. On examination blood pressure is 220/110 mm Hg. Which of the following treatments is most appropriate for managing his condition?

- A. Oral Nifedipine
- B. Oral Nicardipine capsules
- C. IV Nitroglycerine
- D. IV Labetalol

50. A 60-year-old man presents with complaints of breathlessness on walking a few metres. He adds that he has an uncomfortable awareness of his heartbeat, especially on lying down. Examination reveals widened pulse pressure and pulsating uvula. Which of the following would be the most likely auscultatory finding in this condition?

- A. Austin Flint murmur
- B. Carey Coomb murmur
- C. Gallavardin phenomenon
- D. Graham Steel murmur

Murmurs

Diastolic		
	Early diastolic, decrescendo, high-pitched “blowing” murmur	Early diastolic murmur in PAH
	Follows opening snap (OS) , Loud S1 Delayed rumbling mid-to-late murmur with presystolic accentuation Lost in: (↓ interval between S2 and OS correlates with ↑ severity)	Mid-diastolic, rumbling, low-pitched in AR
Continuous		
	Continuous machine like murmur, best heard at left infraclavicular area	Mid-diastolic, short, ARF

- **Gallavardin phenomenon: Murmur of aortic stenosis radiating to the apex, sometimes mistaken for mitral regurgitation.**

51. A 13-year-old boy collapsed while playing football. ECG showed V5, V6 inversion and prominent inverted T-waves. 2D echocardiography showed the septal anterior motion of mitral valve leaflet. Which of the following features will be seen on clinical examination and which of the following are true regarding the management?

Management

- 1. Beta-blockers are given**
- 2. Beta-blockers are contraindicated**
- 3. ICD is indicated**
- 4. ICD is contraindicated**

Clinical findings

- a. Pulsus bisferiens**
- b. Pulsus alternans**
- c. Ejection systolic murmur**
- d. Murmur increases on standing**
- e. Murmur decreases on standing**

- A. 1 & 3; a, c, d**
- B. 2 & 4; b, c, e**
- C. 1 & 3; a, e**
- D. 2 & 4; b, e**

52. A 49-year-old woman with poorly controlled diabetes presents with fever, dysuria, and right flank pain. BP is 80/44 mm Hg, pulse 134/min. Serum glucose is 72 mg/dL, urine ketones positive. Neck veins are flat. Which of the following hemodynamic parameters are most likely to be present in this patient?

- A. ↑ PCWP, ↓ CI (cardiac index), ↑ SVR, ↓ SvO₂
- B. ↑ PCWP, ↑ CI, ↓ SVR, ↑ SvO₂
- C. ↓ PCWP, ↓ CI, ↓ SVR, ↓ SvO₂
- D. ↓ PCWP, ↑ CI, ↓ SVR, ↑ SvO₂

53. Which of the following statements are true of the baroreceptor reflex pathway?

- 1. Rostral ventrolateral medulla (RVLM) is inhibited by CVLM.**
- 2. Caudal ventrolateral medulla (CVLM) releases GABA.**
- 3. Nucleus tractus solitarius (NTS) releases GABA.**
- 4. Stretch receptors are stimulated by increased blood pressure**

- A. 1, 2, 3, 4
- B. 1, 2, 4
- C. 3, 4
- D. 1, 2

88. Lipid profile of a patient who suffered from acute coronary syndrome is given. He has LDL 127 g/dl, HDL 32 mg/dl, and Triglycerides are 278 mg/dl. What drug can be used to treat this condition?

- A. Fenofibrate 160 mg
- B. Rosuvastatin + Fenofibrate
- C. Rosuvastatin 10 mg
- D. Atorvastatin 80 mg

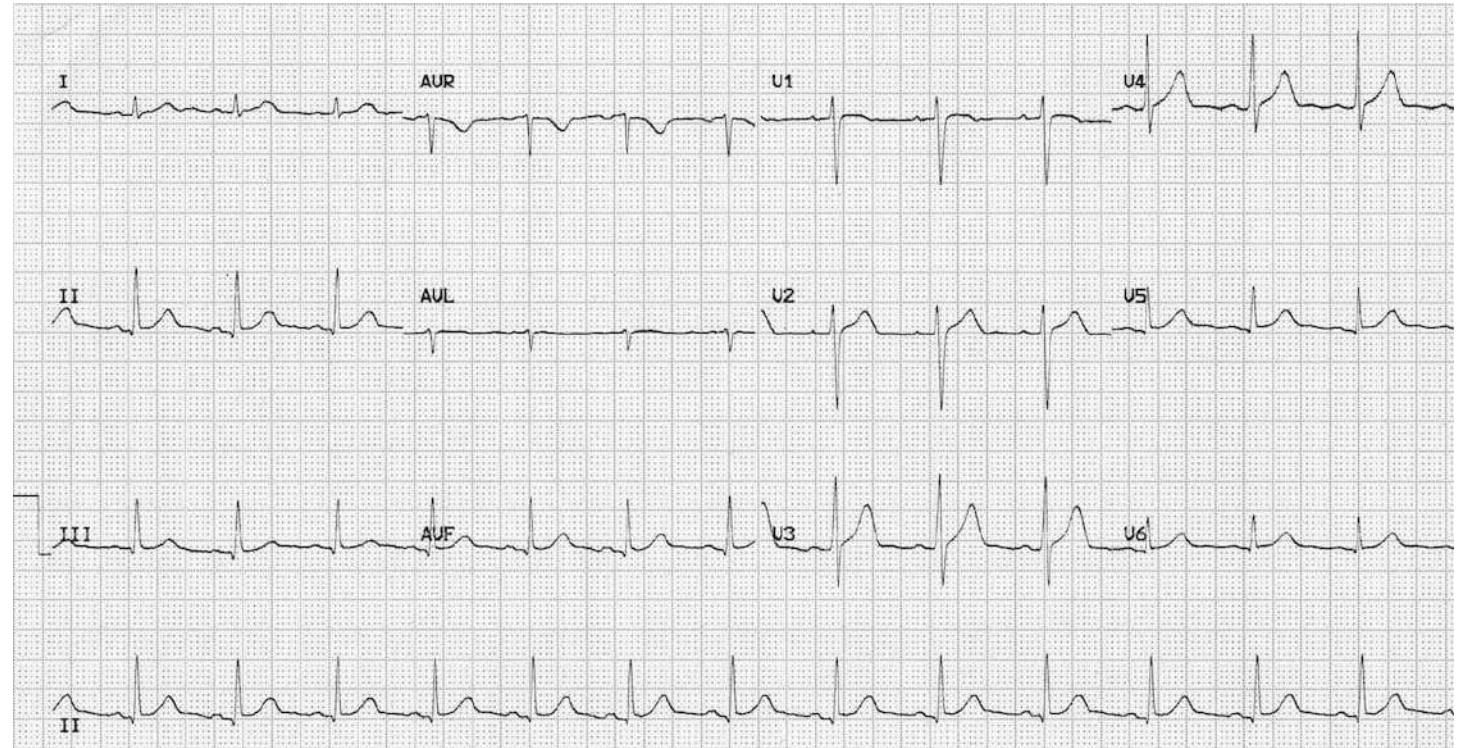
High intensity statins indications:

- Clinical ASCVD/Acute Coronary Syndrome
- Prophylaxis for patients with history of Angina/myocardial infarction/stroke
- LDL > 190 mg/dl
- Hypertriglyceridemia with ASCVD risk

Intensity	Atrovastatin	Rosuvastatin	Simvastatin	Pravastatin	Lovastatin
High (reduce LDL > 50 %)	40-80 mg	20-40 mg	-	-	-
Moderate (reduce LDL by 30-49 %)	10-20 mg	5-10 mg	20-40 mg	40-80 g	40 mg
Low (Reduce LDL by < 30 %)	-	-	10 mg	10-20 mg	20 mg

89. A 52-year-old man presents to the emergency with burning chest pain. Examine the ECG shown below. What does it indicate?

- A. Sinus tachycardia
- B. Irregular rhythm
- C. Normal sinus rhythm
- D. Sinus bradycardia



91. Which of the following methods can be used to calculate cardiac output?

- 1. Thermodilution**
- 2. ECHO**
- 3. Fick's principle**
- 4. Plethysmography**

A. 1,2,3,4

B. 1,2,3

C. 2,4

D. 1,3

92. How should adenosine be administered to a patient with supraventricular tachycardia (SVT) for pharmacological cardioversion?

- A. 6 mg IV bolus over 2–3 minutes followed by saline flush
- B. 6 mg IV bolus over 2–3 seconds followed by a rapid flush with 20 mL normal saline
- C. 6 mg slow IV infusion over 20–30 minutes
- D. 6 mg slow infusion over 20 minutes, followed by 12 mg over 40 minutes

93. A patient with chest pain and palpitations has BP 130/90 mmHg and pulse 101/min. Echocardiography shows right atrial collapse during diastole. What is the most appropriate management?

- A. Pericardiocentesis
- B. NSAIDs
- C. Steroids
- D. Chest tube insertion or thoracotomy

95. A 54-year-old male with a long history of alcohol use disorder presents to the primary care physician with shortness of breath and increasing fatigue over the past year. The patient has also experienced decreased exercise tolerance and mild lower extremity swelling. He denies chest pain, nausea, vomiting, abdominal pain, or changes in his bowel movements. Vital signs include a temperature of 37.1°C (98.8 °F), blood pressure of 118/78 mmHg, heart rate of 80 beats/min, and respiratory rate of 16 breaths/min. Physical exam reveals diffuse bibasilar crackles, abdominal distension, and 2+ pitting lower extremity edema. Doppler echocardiography shows reduced left and right ventricular wall motion with an ejection fraction of 33%. The patient is counseled on the importance of reducing his alcohol consumption. The physician also explains that he will start the patient on a new medication to reduce harmful cardiac remodeling due to the actions of an endogenous vasoconstricting peptide hormone. The next day, the patient calls complaining of lightheadedness and dizziness. His last at-home blood pressure reading was 95/60 mmHg. Which of the following medications was this patient most likely prescribed?

- A. Atorvastatin
- B. Spironolactone
- C. Budesonide
- D. Enalapril

96. A 66-year-old male with a past medical history of hypertension and a 40 pack-year cigarette smoking history comes to the cardiologist with intermittent chest pain. He previously had chest pain only when walking his dog, which subsided with rest; however, he now has pain while watching TV or reading the newspaper. The patient denies a correlation between his symptoms and eating. His family history includes coronary artery disease in his father at age 55. Temperature is 36.9°C (98.4°F), blood pressure is 138/82 mm Hg, pulse is 88 min, and respirations are 16/min. The patient is in no acute distress. Cardiopulmonary auscultation reveals a regular S1 and S2 with no rubs, murmurs, or gallops and clear breath sounds throughout. Extremities are warm and well-perfused. ECG shows normal sinus rhythm without ST-segment elevations, Q waves, or T wave inversions. Troponin levels are < 0.01 ng/mL. The patient undergoes evaluation by coronary angiography, revealing a partial occlusion of the posterior descending artery and codominant circulation. Which of the following vessels most likely supply the posterior descending artery in this patient?

- A. Left coronary and right marginal arteries
- B. Left anterior descending and right coronary arteries
- C. Right coronary and left circumflex arteries
- D. Right and left coronary arteries

99. A 64-year-old female with a past medical history of a right below-the-knee amputation with a transtibial prosthesis presents to the cardiologist for a cardiac stress test. She reports exertional chest pain and shortness of breath when walking to pick up her mail each afternoon. The pain is never present at rest. Due to her history of amputation and prosthesis, she is not a candidate for exercise stress testing. Therefore, the physician administers a medication that will induce a similar response. Following administration, the patient reports a crushing chest pain similar to her reported symptoms. Which of the following best describes the mechanism of action of the medication administered?

- A. agonist causing an increase in cGMP
- B. Gi antagonist causing an increase in cAMP
- C. Gq agonist causing an increase in IP3
- D. Gs agonist causing activation of adenylate cyclase

100. A 10-year-old female who recently moved to the area presents to the cardiologist to establish care. The patient's father reports his daughter has always been "on the shorter side" and had a genetic abnormality noted on karyotype analysis during prenatal screening, but he does not recall the details. On physical exam, the patient appears short with a broadened chest. Excess skin folds extend along the lateral aspect of her neck bilaterally, and her toenails appear dysplastic. A computed tomography angiogram (CTA) completed at the patient's previous healthcare facility shows a narrowing of the aorta at the isthmus. Which of the following findings will most likely be appreciated on this patient's physical exam?

- A. Abdominal bruit
- B. Biphasic pulses
- C. Bounding femoral pulses
- D. Brachial-femoral delay

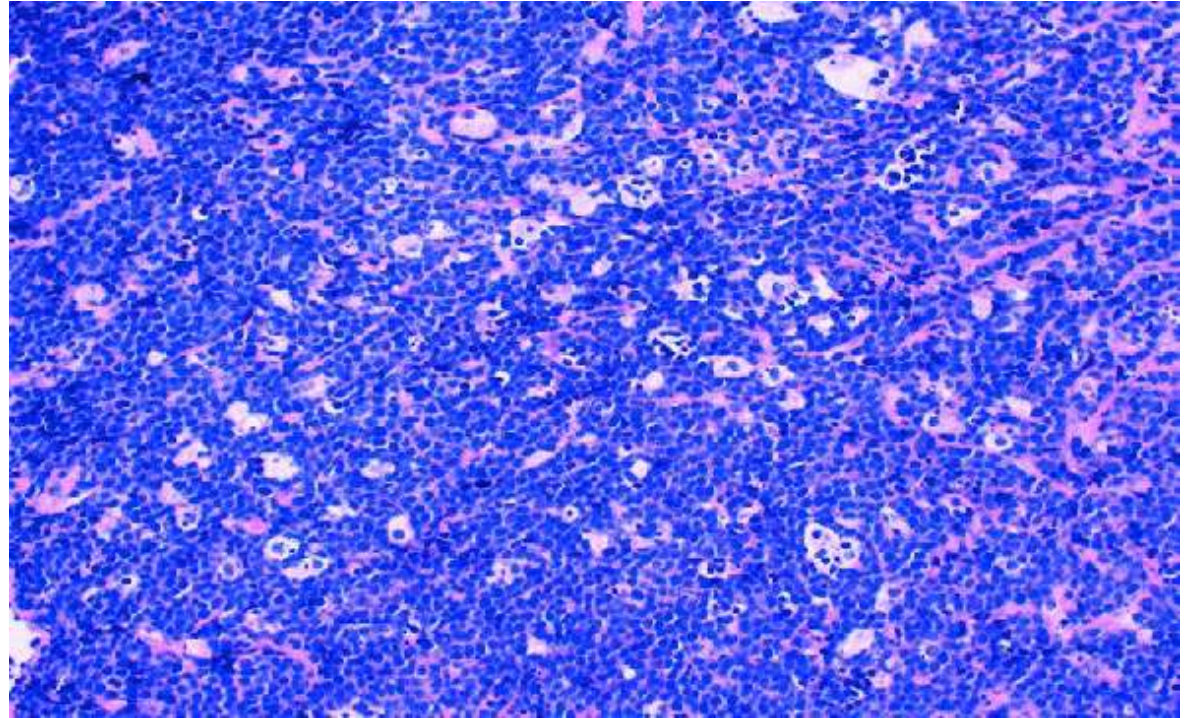
INTEGRATED HEMATOLOGY

54. All of the following are true regarding the management of Immune Thrombocytopenic Purpura (ITP) except:

- A. Splenectomy is considered after glucocorticoid therapy failure
- B. IVIG is a treatment option in life-threatening bleeding
- C. Romiplostim and eltrombopag are avoided post-splenectomy
- D. Rh(D) immune globulin is used in Rh-positive patients

55. A 18-year-old boy is brought to the hospital with a 2-week history of rapidly increasing swelling on his jaw, recurrent nosebleeds, weight loss, and generalized fatigue. Physical examination of the neck reveals firm, nontender lymph nodes. The mass is biopsied, the image is shown below. Which of the following best describes the genomic structure of the most likely causative virus?

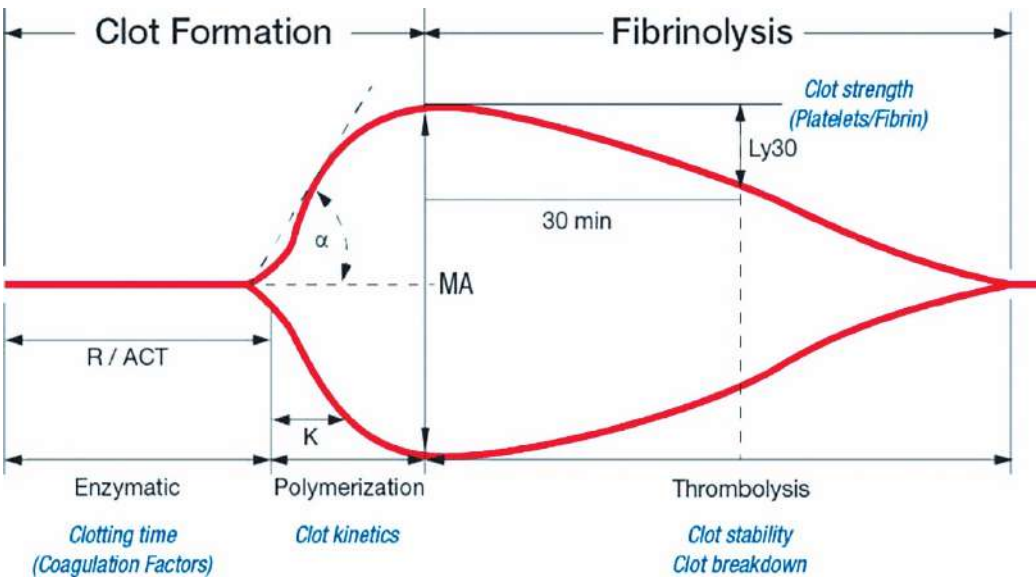
- A. Double-stranded circular DNA
- B. Double-stranded linear DNA
- C. Double-stranded linear RNA
- D. Single-stranded linear RNA



56. A 65-year-old male presents with sepsis and purpura fulminans. Thromboelastography (TEG) is ordered to assess the patient's clotting profile. Which of the following TEG tracings is most consistent with the patient's presentation?

- A. Reduced R-time, increased angle, increased MA, increased LY30
- B. Prolonged R-time, decreased angle, decreased MA, decreased LY30
- C. Prolonged R-time, decreased angle, decreased MA, increased LY30
- D. Reduced R-time, decreased angle, increased MA, decreased LY30

TEG



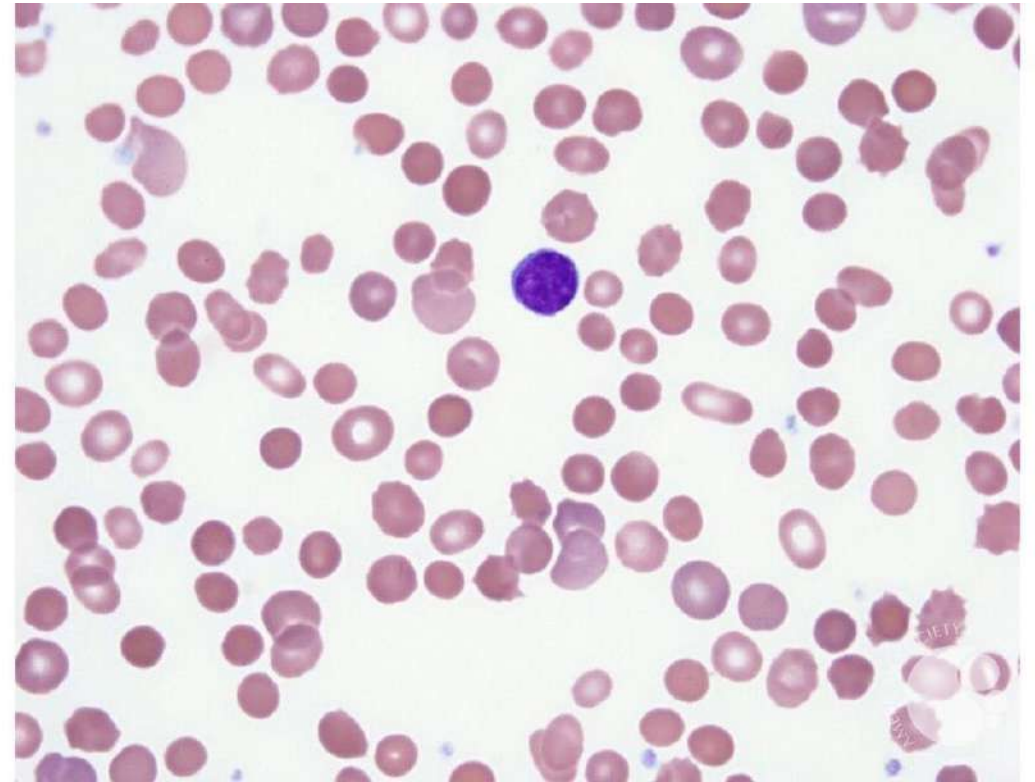
TEG	Normal	Abnormality / Cause	Treatment
Reaction Time (R value)	5–10 min	↑ R value: ↓ factors	FFP, protamine
K value	1–5 min	↑ K : ↓ fibrinogen	Cryoprecipitate, fibrinogen
α-angle	45–75°	↓ α-angle: ↓ fibrinogen	Cryoprecipitate, fibrinogen
Maximum Amplitude (MA)	50–75 mm	↓ MA / MCF: ↓ platelet count and/or function	Platelets, DDAVP
LY-30	0–10%	↑ LY-30 / CL: clot breakdown	TXA, Amicar

57. A 41-year-old woman with a long history of menorrhagia comes to the physician due to a low hemoglobin level identified on routine laboratory evaluation. She is diagnosed with iron deficiency anemia and started on oral ferrous sulfate. Which of the following cells secrete a substance that controls iron storage and release by other cells involved in iron homeostasis?

- A. Biliary lining cells
- B. Bone marrow macrophages
- C. Enterocytes
- D. Hepatic parenchymal cells

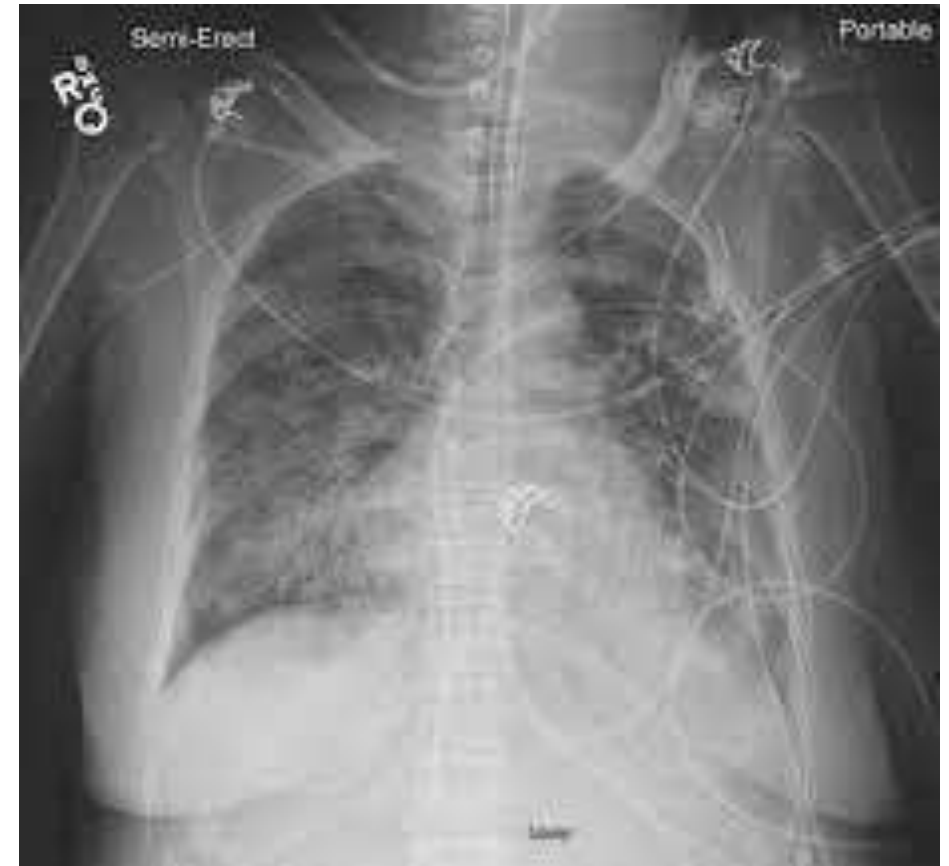
58. A 3-year-old boy is brought to the physician with jaundice and pallor. He was adopted and his family history is unknown. Laboratory studies show anemia, reticulocytosis, and increased indirect bilirubin. A peripheral blood smear is shown. This patient is most likely to have which of the following additional findings?

- A. Decreased lactate dehydrogenase
- B. Increased haptoglobin
- C. Increased MCHC
- D. Positive Coombs test



59. A 66-year-old woman with warfarin induced bleeding receives IV vitamin K, 4 U PRBCs and 4U FFP. 4h later, she begins to complain of shortness of breath. Vitals T - 39°C, RR 35/min, SpO2 84% on RA, and BP 88/52 mm Hg. Exam revealed B/L crackles and the patient was intubated for respiratory failure. CXR is as shown in the picture. What is the likely diagnosis?

- A. Anaphylaxis
- B. TACO
- C. TRALI
- D. Aspiration



60. 7-year-old boy is brought to the clinic for a routine health maintenance examination. He underwent a splenectomy a year ago for persistent anemia and jaundice. He has received the pneumococcal and meningococcal vaccinations and takes penicillin prophylaxis. Physical examination reveals a well-appearing child. The sclerae are anicteric. The abdomen is soft and nontender; no masses are palpable. Several well-healed laparoscopy scars are noted. Complete blood count is as follows:

Hemoglobin: 11.3 g/dL

Reticulocytes: 3%

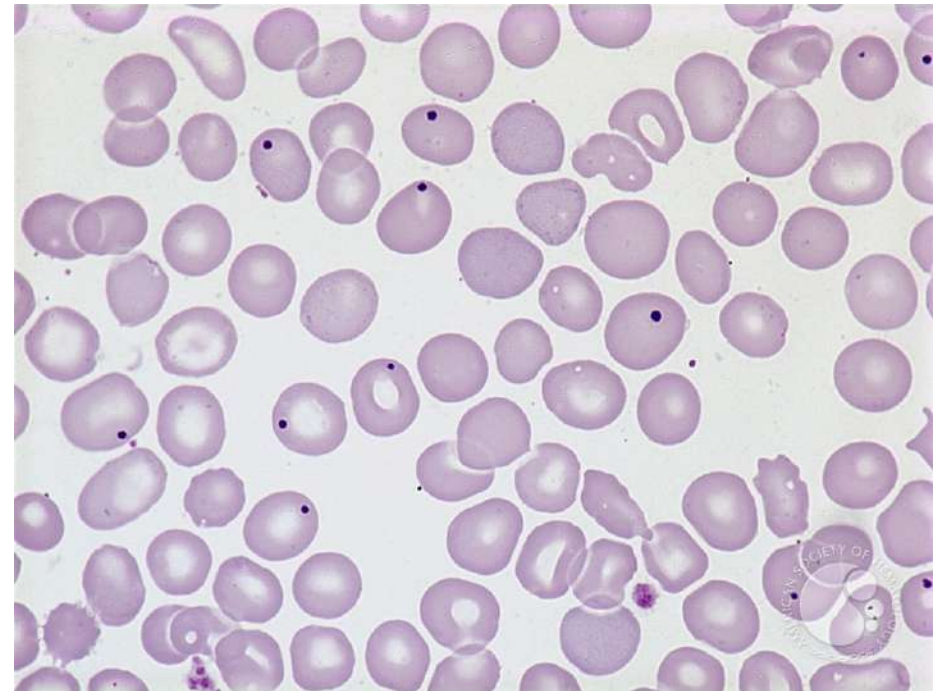
Platelets: 160,000/mm³

Leukocytes: 8,200/mm³

Peripheral blood smear with Wright stain is shown.

This patient's findings are most likely related to which of the following?

- A. Chronic Hb oxidation and precipitation
- B. Inability to produce beta globin chains
- C. Mechanical red-blood-cell membrane damage
- D. Persistence of red blood cell precursor nuclei



61. A 5-year-old girl is brought to the OPD by her mother due to leg pain. One week ago mother saw the patient fall onto the living room floor after climbing on a couch. Since the incident, she has had persistent leg pain that appears to be worse at night, and for the last 2 days she has been refusing to walk asking her mother to carry her. The patient has no chronic medical conditions but has had a mild, non-productive cough for the past month. Temperature is 38.3 C (100.9 F); all other vital signs are normal. Examination shows a pale child. The abdomen is nontender and moderate hepatosplenomegaly is noted. Palpation of the bilateral anterior proximal tibias elicits pain. There are a few scattered bruises across the chest and back. Complete blood count results are as follows:

Hemoglobin-8g/dL

Platelets-30,000/mm³

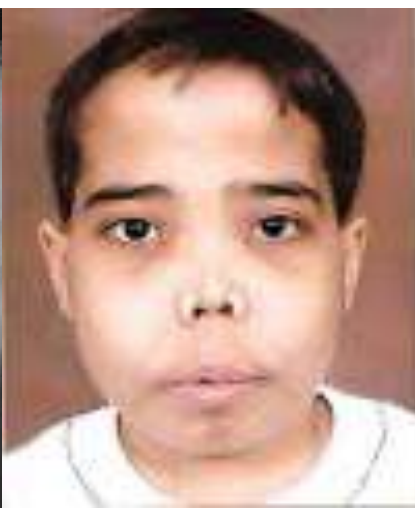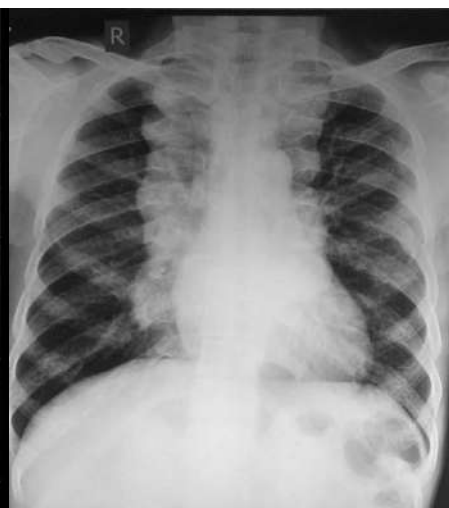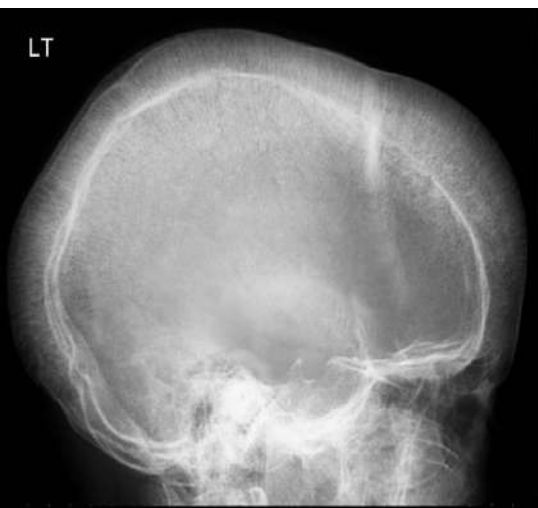Leukocytes-3,000/mm³

Which of the following is the most likely cause of this patient's symptoms?

- A. Acute lymphoblastic leukemia
- B. Aplastic anemia
- C. Immune thrombocytopenia
- D. Infectious mononucleosis

62. A 674-month-old boy is brought to the clinic by his mother due to concerns of appearing pale. Over the past few days, he has been sleeping more than usual and is less interactive. He continues to have good urine output. The patient was born at 40 weeks gestation and had a normal nursery course. However, the patient's newborn screen revealed an extra band representing gamma tetramers on haemoglobin electrophoresis. The patient takes a vitamin D supplement daily. Vital signs are normal. He appears tired and has mild scleral icterus. The remainder of the examination shows no abnormalities. What is the likely diagnosis?

- A. Beta thalassemia
- B. HbH disease
- C. Hb Barts
- D. Sickle cell anemia



Chr 16 deletion:

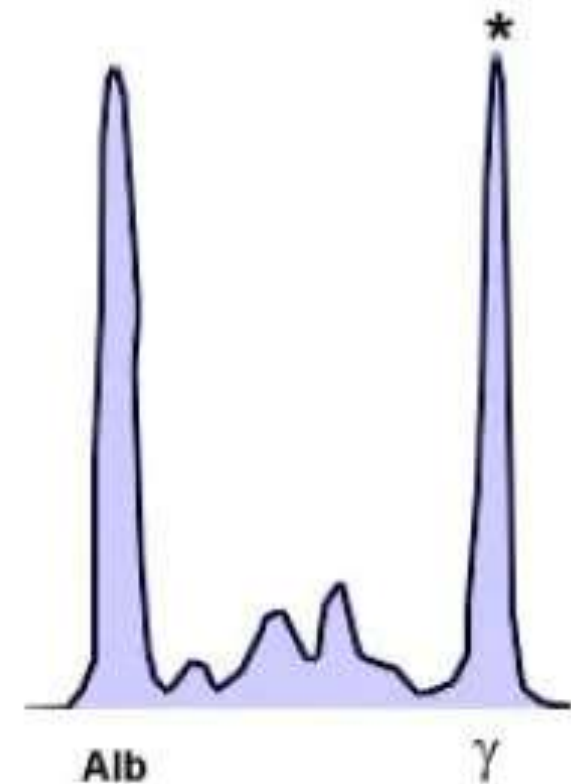
- 1-
- 2-
- 3-
- 4-

Chr 11 Splicing mutation:

- 1-
- 2-

63. A 67-year-old man is evaluated for persistent lower back pain and fatigue. Laboratory testing shows anemia and renal dysfunction. Serum electrophoresis of the serum proteins is shown below. A medication that blocks cellular proteasome action is administered. This treatment is most likely to cause which of the following effects on the abnormal cells?

- A. Augmented cytotoxic T-cell response
- B. Decreased DNA methylation
- C. Impaired RNA splicing
- D. Increased apoptosis



64. A 20-year-old woman comes to the emergency department due to bloody stools. For the past month, she has also had decreased energy. Skin examination shows pallor and scattered bruises in various stages of healing throughout the trunk. The abdomen is soft without organomegaly. Complete blood count results are as follows:

Hemoglobin: 7.2 g/dL

Mean corpuscular volume 90 μm^3

Platelets: 10,000/ mm^2

Leukocytes: 1050/ mm^3

Neutrophils: 5%

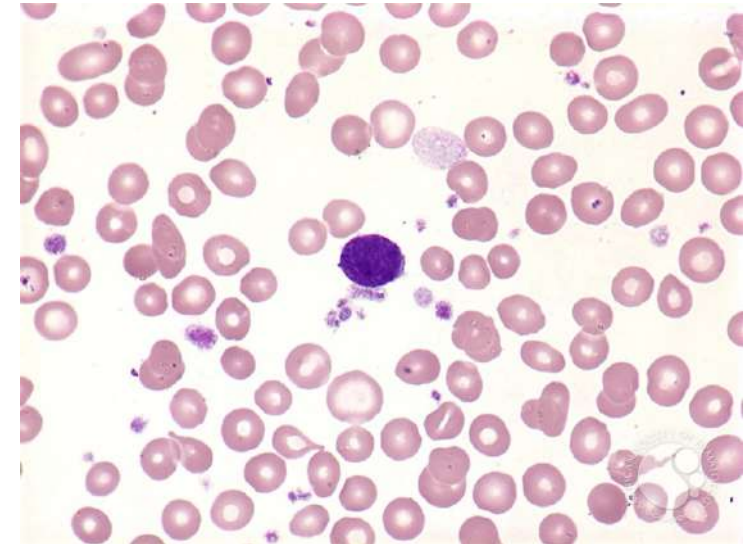
Lymphocytes: 95%

Which of the following is the most likely cause of this patient's condition?

- A. Autoimmune-induced loss of self-renewing hematopoietic stem cells
- B. Bone marrow replacement by constitutively active tyrosine kinase-stimulated cells
- C. Splenic hyperactivity with cell trapping by the reticuloendothelial system
- D. Ineffective hematopoiesis secondary to micronutrient deficiency

65. A 68-year-old man comes to the OPD with a few months of severe fatigue and a 6.8-kg unintentional loss in weight. Abdominal examination shows mild hepatomegaly and a markedly enlarged spleen. Stool guaiac testing is negative. Laboratory results show pancytopenia, and peripheral blood smear is shown below. Bone marrow aspiration is attempted but yields no marrow, and a bone marrow biopsy is subsequently performed. Which of the following findings is most likely to be observed in this patient's bone marrow?

- A. Diffusely fibrotic marrow with clusters of megakaryocytes
- B. Increased staining for storage iron in marrow macrophages
- C. Marrow replaced by dysplastic cells of all 3 lineages
- D. Severely hypocellular marrow replaced by adipose cells



66. 35-year-old woman comes to the physician complaining of weakness, fatigue, and pallor. Physical examination is unremarkable except for conjunctival pallor. Laboratory results are as follows:

Haemoglobin: 7.2 g/dL

Mean corpuscular volume: 90 fL

Reticulocytes: 0.1%

Platelets: 280,000 /uL

Leukocyte count: 6,700 cells/uL

Iron studies and serum B12 and folic acid levels are within normal limits. Bone marrow biopsy shows absence of erythroid precursors but preserved myeloid and megakaryocytic elements. Further workup would most likely show which of the following?

- A. Hepatocellular carcinoma
- B. Renal cell carcinoma
- C. Thymic tumor
- D. Cerebellar hemangioblastoma

67. Supravital stain of a peripheral smear of a patient is shown. What is the likely inheritance pattern of this condition?

- A. Autosomal dominant inheritance
- B. Autosomal recessive inheritance
- C. X-linked dominant inheritance
- D. X-linked recessive inheritance



68. Part 1 of 2

A 54-year-old previously healthy man comes to the OPD due to several weeks of leg swelling. He has had no fever, chest pain, or dyspnea. The patient has a 40-pack-year smoking history. The abdomen is soft and nondistended. A mobile left flank mass can be palpated. There are several vertically oriented tortuous veins on the lower abdominal wall. Which of the following structures is most likely obstructed in this patient?

- A. Femoral veins
- B. Iliac veins
- C. Inferior vena cava
- D. Portal vein

69. Part 2 of 2

Further evaluation of the patient reveals microscopic hematuria.

Laboratory results are as follows:

Leukocytes: 9,000/mm³

Hemoglobin: 19.2 g/dL

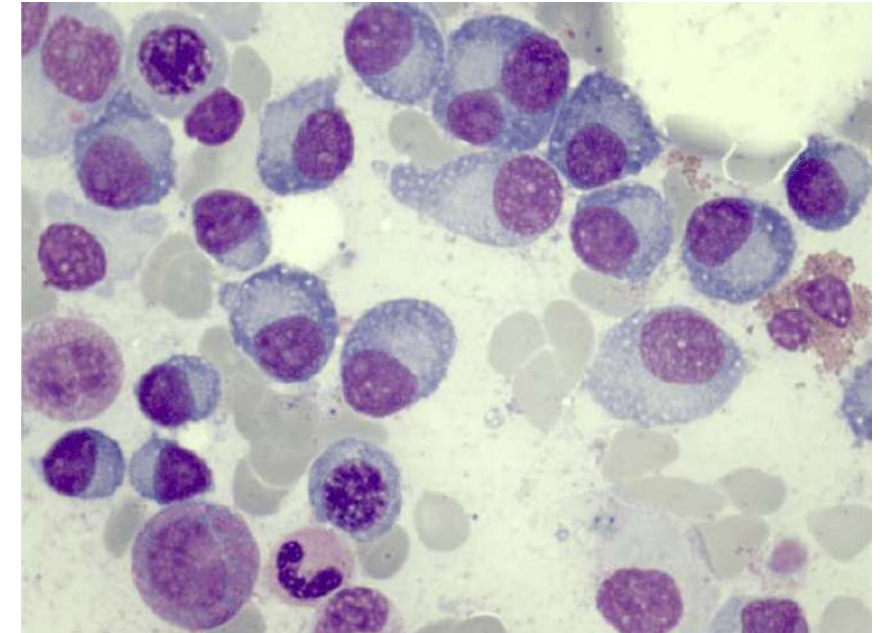
Platelets: 230,000/mm³

Which of the following is the most likely cause of this patient's hematologic findings?

- A. Arteriovenous malformation
- B. Excess erythropoietin production
- C. Extramedullary hematopoiesis
- D. Myeloproliferative disorder

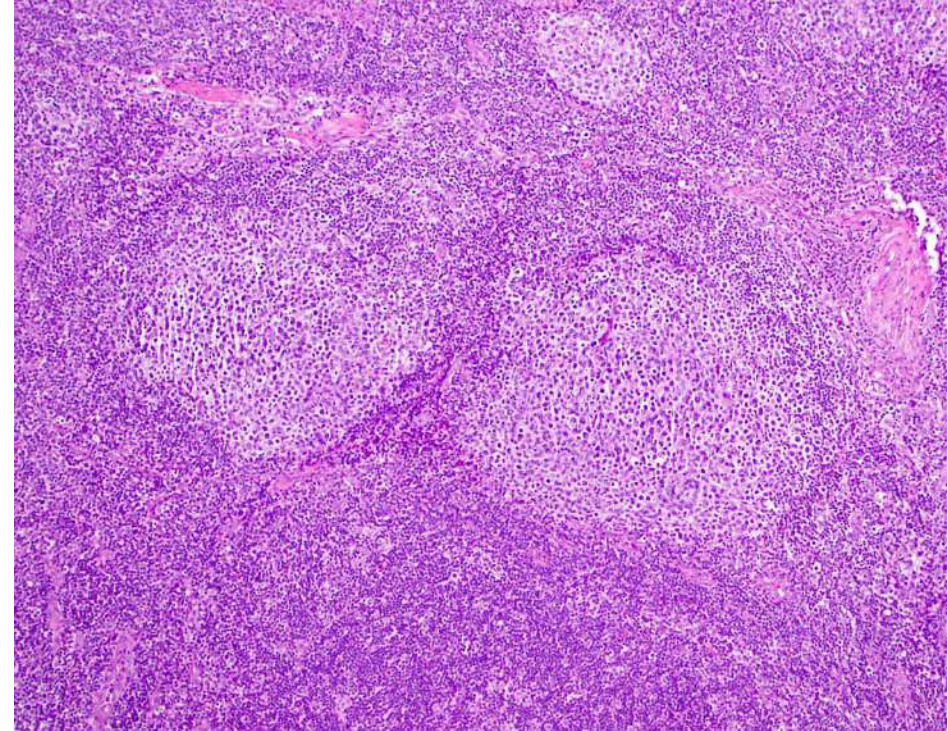
70. A 59-year-old man comes to the OPD due to 3 months of progressive fatigue and back pain. The back pain occurs mainly with movement or positional changes. Physical examination reveals midline tenderness over the middle and lower back. Laboratory evaluation shows a hemoglobin level of 10.2 g/dL and serum calcium level of 12 mg/dL. A bone marrow aspirate is performed, and the histopathologic findings are shown below. This patient is at greatest risk for developing which of the following conditions?

- A. Amyloidosis
- B. Cardiac tamponade
- C. Hepatic failure
- D. Hyperthyroidism



71. A 35-year-old man is being evaluated for nontender cervical lymphadenopathy that he first noticed while shaving. A biopsy is performed and is shown below. Cytogenetic analysis would most likely demonstrate which of the following patterns?

- A. BCL-2 overexpression
- B. BCR-ABL rearrangement
- C. C-MYC overexpression
- D. Constitutive tyrosine kinase activation



72. A 9-year-old girl is brought to the emergency department due to prolonged epistaxis. The girl says that she picked her nose immediately before the bleeding started. Her parents decided to take her to the emergency department after the epistaxis persisted for 20 minutes despite constant compression. The patient has had frequent nosebleeds that often last >10 minutes. Laboratory tests are ordered, and results are as follows:

Hematocrit: 43%

Bleeding time: prolonged

Partial thromboplastin time (PTT): prolonged

Prothrombin time (PT): normal

Thrombin time (TT): normal

D-dimer: normal

Which of the following is the most likely diagnosis?

- A. Factor XIII deficiency
- B. Hemophilia A
- C. Vitamin K deficiency
- D. von Willebrand disease

73. Which of the following is useful for a patient having Haemophilia B?

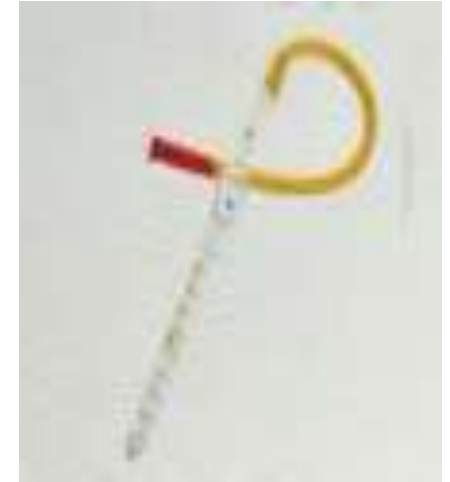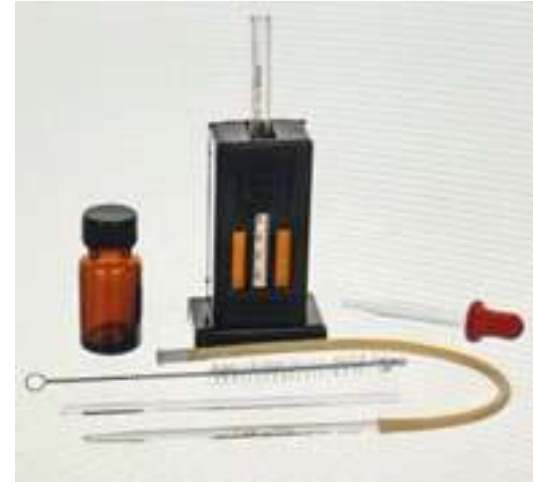- A. Cryoprecipitate
- B. Fresh frozen plasma
- C. Recombinant factor 8
- D. Cryo poor plasma

74. A 71-year-old woman comes to the physician because of palpitations and shortness of breath that started 3 days ago. She has hypertension and congestive heart failure. An ECG shows a narrow-complex tachycardia without P waves. The patient is prescribed a prophylactic medication that can be reversed with idarucizumab. The expected beneficial effect of the prescribed drug is most likely due to which of the following effects?

- A. Induction of conformational change in antithrombin III
- B. Direct inhibition of factor Xa
- C. Reduced activation of clotting factors II, VII, IX, and X
- D. Direct inhibition of thrombin

75. Which of the following is not useful for hemoglobin estimation by the calorimetric test?

- A. RBC pipette
- B. Sahli graduated hemoglobin tube
- C. Comparator with brown glass standard
- D. Hemoglobin pipette



76. An investigator is studying the changes that occur in the oxygen-hemoglobin dissociation curve of different types of hemoglobin under various conditions. The blood obtained from a male infant shows decreased affinity for 2,3-bisphosphoglyceric acid. Which of the following is the most likely composition of the hemoglobin molecule in this sample?

- A. $\alpha_2\beta_2$
- B. $\alpha_2\gamma_2$
- C. β_4
- D. $\alpha_2\delta_2$

77. A 25 yr old women G2P1L1 is brought to the emergency at 30 weeks gestation in active labor. The patient had severe anemia during pregnancy and received multiple blood transfusions during past months. An uncomplicated Vaginal delivery is performed and 2.5kg infant is delivered. Post operatively she continues to bleed and receives a transfusion of 1 unit of packed RBC. One hour later, the patient appears to have flank pain and in acute distress. Temperature is 101° F, pulse 115/min and BP is 92/66 mmHg. Foley catheter shows dark brown urine. Further evaluation is most likely to show:

- A. Serum antibodies against Class 1 HLA
- B. Positive Direct Coomb's
- C. B/L pulmonary infiltrates on CXR
- D. Low levels of serum IgA

78. Which of the following is correctly matched:

- A. FFP: Hemophilia A
- B. Saline washed RBC: Increased risk of allergic reaction
- C. Cryoprecipitate: Hemophilia B
- D. Cryo-poor plasma: TTP

79. Splenectomy is contraindicated in which of the following conditions? (FMGE JULY 2024)

- A. Splenic rupture
- B. Thrombocytopenia
- C. Hairy cell leukemia
- D. Bone marrow failure

80. A 7-year-old boy is brought to the office by his parents due to fatigue, easy bruising, and frequent nosebleeds for 2 weeks. On physical examination, the child appears pale with scattered petechiae. Laboratory studies show:

Hemoglobin: 8.9 g/dL

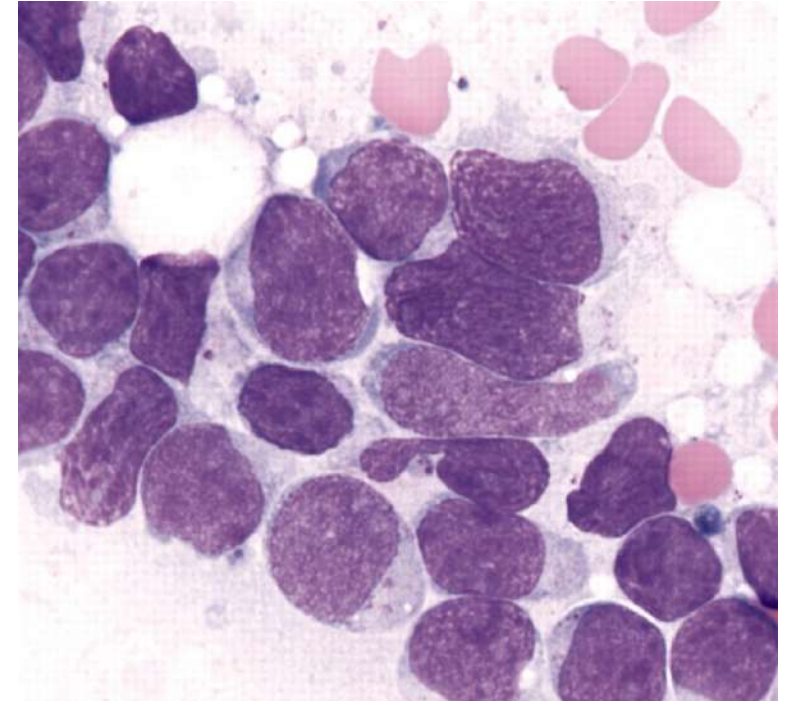
Platelet count: 21,000/mm³

Leukocyte count: 15,500/mm³

A bone marrow aspirate reveals the findings shown in the image below. The cells are positive for terminal deoxynucleotidyl transferase (TdT) and express CD19 and CD10.

Which of the following is the most likely diagnosis?

- A. Precursor B-cell leukemia
- B. Precursor T-cell leukemia
- C. Mature B-cell leukemia
- D. Mature T-cell leukemia



A 69-year-old woman comes to the physician for a routine health maintenance examination. She feels well. Physical examination shows nontender cervical and axillary lymphadenopathy. The spleen is palpated 5 cm below the costal margin. Her leukocyte count is $12,000/\text{mm}^3$ and platelet count is $217,000/\text{mm}^3$. Further evaluation is most likely to show which of the following findings?

- A. Ringed sideroblasts
- B. Teardrop cells
- C. Smudge cells
- D. Rouleaux formation

82. A 21-year-old man comes to the physician because of a 3-day history of yellowing of his eyes. He has also noticed a decrease in his exercise capacity and gets quickly exhausted after minor physical activity. Examination shows scleral icterus and pale mucous membranes. He has splenomegaly. His hemoglobin concentration is 7.9 mg/dL, leukocyte count 8500/mm³ and platelet count is 1.8 lakhs/mm³. Direct antiglobulin and heterophile antibody tests are positive. Which of the following additional laboratory findings are most likely present in this patient?

- A. Decreased reticulocyte count
- B. Decreased haptoglobin levels
- C. Decreased mean corpuscular volume
- D. Increased direct to total bilirubin ratio

83. A 66-year-old woman presents to the clinic with 2 months of worsening fatigue and persistent lower back pain that is aggravated by movement. Physical examination shows pallor and tenderness over the lower spine. Radiographic imaging reveals lytic bone lesions.

Laboratory findings include:

Hemoglobin: 8.5 g/dL

Serum creatinine: 2.8 mg/dL

Serum calcium: 11.0 mg/dL

Urine dipstick is negative for protein, but 24-hour urine protein quantification shows elevated protein levels. Urine electrophoresis is most likely to detect which of the following?

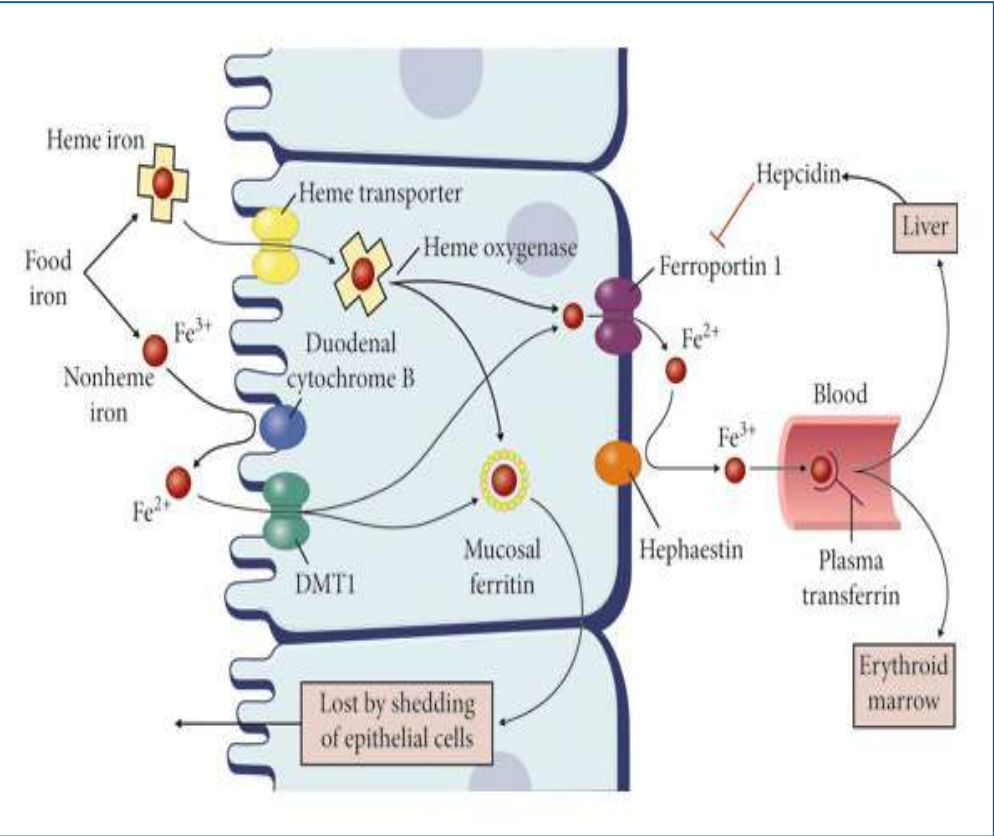
Options:

- A. Gamma heavy chains
- B. Immunoglobulin G
- C. Immunoglobulin M
- D. Lambda light chains

84. Which of the following are reduced in Iron Deficiency Anemia ?

- 1. Ferritin**
- 2. TIBC**
- 3. Transferrin saturation**
- 4. RDW**
- 5. Hepcidin**
- 6. Soluble transferrin receptor**

- A. 1, 3, 5
- B. 1, 3, 4, 6
- C. 2, 4, 5
- D. 1, 3, 5, 6



85. A 65-year-old male patient comes to the clinic with unbearable itching while taking a shower which has been present for many months. Physical examination shows the presence of facial plethora. Laboratory examination shows a hemoglobin of 20 g/dL. What would be the best match for this patient?

- A. RBC mass increased, O₂ saturation increased, EPO decreased
- B. RBC mass increased, O₂ saturation normal, EPO decreased
- C. RBC mass increased, O₂ saturation increased, EPO normal
- D. RBC mass normal , O₂ saturation normal, EPO increased

86. Which of the following is not associated with poor prognosis in a patient with multiple myeloma?

- A. t(4;14)
- B. High serum beta-2 microglobulin
- C. Low serum albumin
- D. t(11;14)

Poor Prognosis	Good Prognosis
t(4;14), t(14;16), t(14;20), del(17p), aneuploidy, hypodiploidy	Hyperdiploid,
↑ beta-2 macroglobulin	t(11;14)
Plasmablastic morphology	t(6;14)
Low serum albumin	cyclin D1/D3+

87. All of the following anticoagulants inhibit both Factor Xa and Factor IIa, except:

- A. Unfractionated heparin
- B. LMWH
- C. Fondaparinux
- D. None of the above

90. Which of the following is not compatible with a diagnosis of chronic myelomonocytic leukemia (CMML)?

- A. More than 20% blasts in blood or bone marrow
- B. Absence of Philadelphia chromosome
- C. Peripheral blood monocytosis $>1 \times 10^9/L$
- D. Minimal or absent dysplasia in myeloid lineages

94. Which of the following is false about acquired hemophilia A?

- A. Autoantibodies are formed against factor VIII
- B. Associated with lymphoproliferative malignancies
- C. Presents in childhood or early adulthood
- D. Bethesda assay confirms the diagnosis

97. A previously healthy 37-year-old female, gravida 0 para 0, presents to the gynecology office with cyclic pelvic pain and bloating. She has been experiencing these symptoms for the past three years but has been unable to seek care due to insurance issues. She describes her menstrual cycles as "heavy" and states they occur every 28 days and last seven to ten days. She denies significant pain or cramping associated with her periods. Vital signs and physical exam are unremarkable. The physician orders a pelvic ultrasound, which shows the presence of multiple uterine leiomyomas, with the largest measuring 10 cm by 8 cm. A complete blood count reveals a hemoglobin of 9.0 g/dL. Peripheral blood smear shows the presence of several large cells with bluish-tinted cytoplasm. Dark blue dots and curved linear structures are observed in the cytoplasm with the Romanowsky stain. Which of the following best describes these inclusions?

- A. Denatured hemoglobin
- B. Iron deposits
- C. Nuclear remnants
- D. Ribosomal genetic material

98. A 39-year-old female with a past medical history of hypothyroidism, HIV, and psoriasis presents to the emergency department with a one-month history of weight loss and night sweats. She unintentionally lost 13 lbs (5.9 kg) over the previous month. The patient complains of significant fatigue, requiring naps throughout the day. Her current medications include levothyroxine, lamivudine, efavirenz, maraviroc, and topical hydrocortisone cream. She denies tobacco and alcohol use but admits to using intravenous heroin regularly over the past eight years. Vital signs include a blood pressure of 122/82 mmHg, heart rate of 68 beats/ min, respiratory rate of 17 breaths/min, and temperature of 38.2°C (100.8 °F). Physical exam reveals multiple enlarged, nontender cervical lymph nodes. A dermatologic exam reveals multiple erythematous lesions and needle track marks on both arms. Her abdomen is nontender and nondistended. A lymph node biopsy is scheduled for the following week. Which of the following will most likely be observed on this biopsy if a t(8;14) translocation is detected?

- A. Eosinophilic Cowdry inclusion bodies
- B. Monoclonal plasma cells
- C. Myeloblasts with Auer rods
- D. Tingible body macrophages



Cerebellum

Get the balance right

Thank you

Best wishes!



Integrated Test Online CVS + HEMAT

25-08-2025

INTEGRATED CVS

1. Which of the following is not included as a major component of Jones criteria for diagnosing acute rheumatic fever?

A. Chorea

B. Increased PR interval

C. Erythema marginatum

D. Arthralgia

E marginatum
migrans
multiforme mycoplasma ^{HSV}

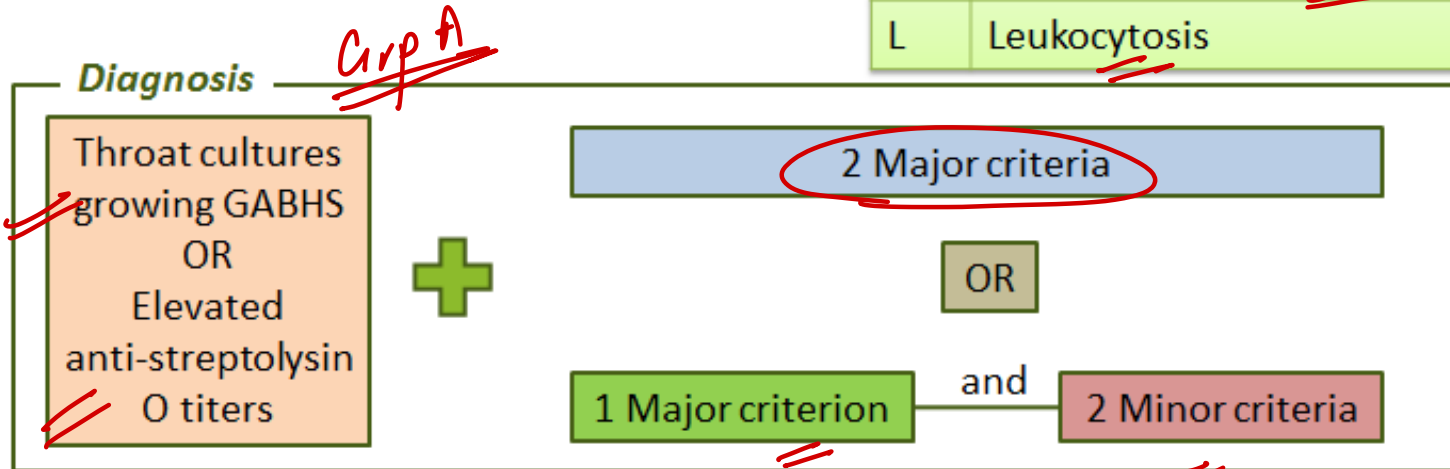
Major Criteria

<u>J</u>	Joint Involvement
<u>O</u>	O looks like a heart = myocarditis
<u>N</u>	Nodules, subcutaneous
<u>E</u>	Erythema marginatum
<u>S</u>	Sydenham chorea

Minor Criteria

C	CRP Increased
A	Arthralgia
F	Fever
E	Elevated ESR
P	Prolonged PR Interval
A	Anamnesis of Rheumatism
L	Leukocytosis

Diagnosis

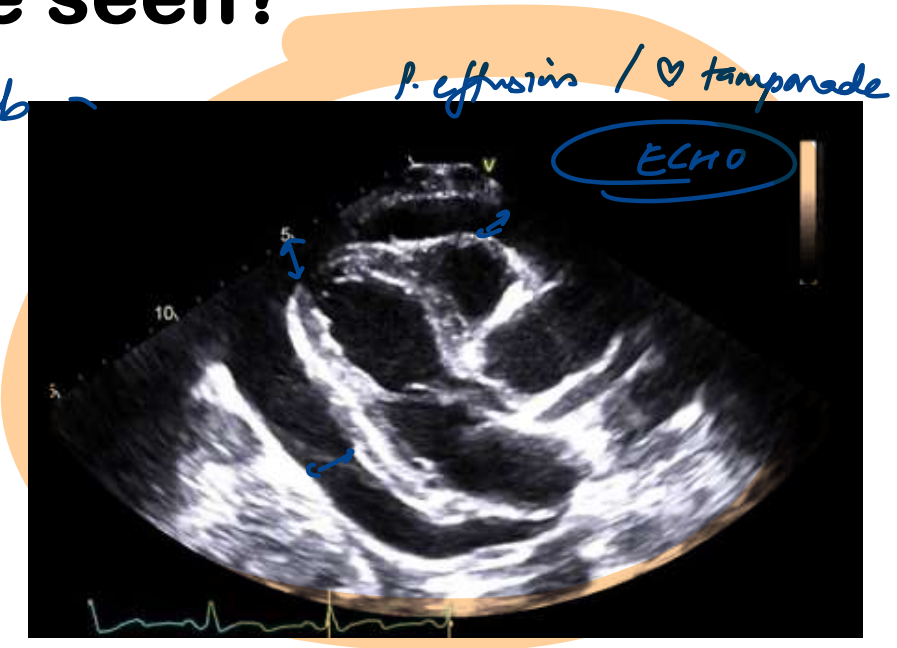


2. Choose the cardiac event that corresponds to the phase of isovolumetric contraction:

- A. S3 heart sound *early diastole*
- B. S2 heart sound *diastole*
- C. QRS wave of ECG *late diastole*
- D. c wave of JVP

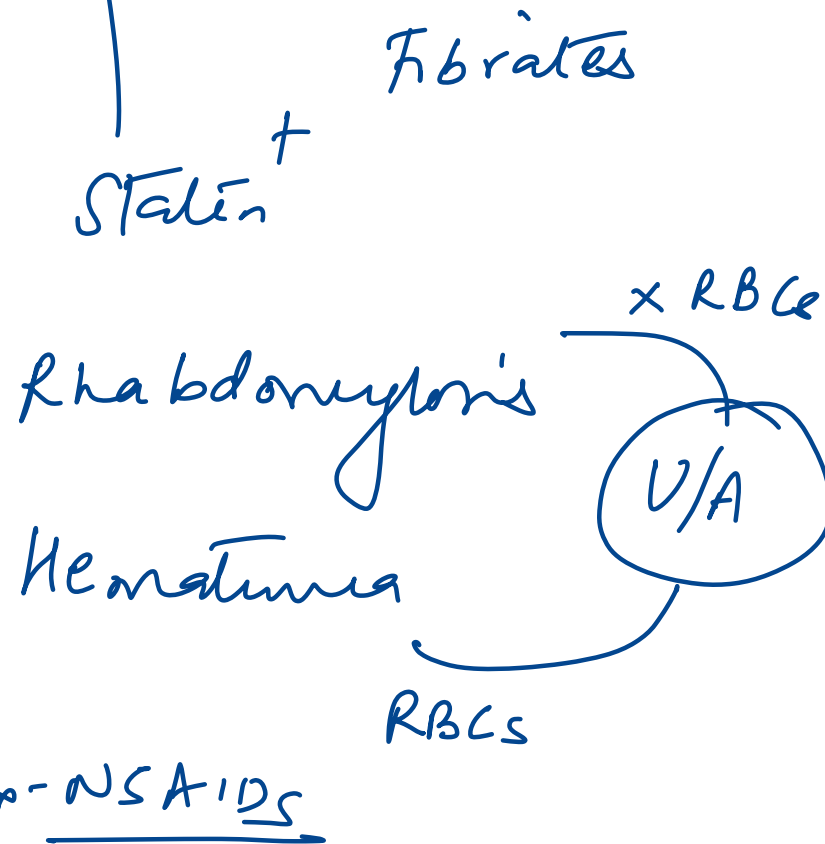
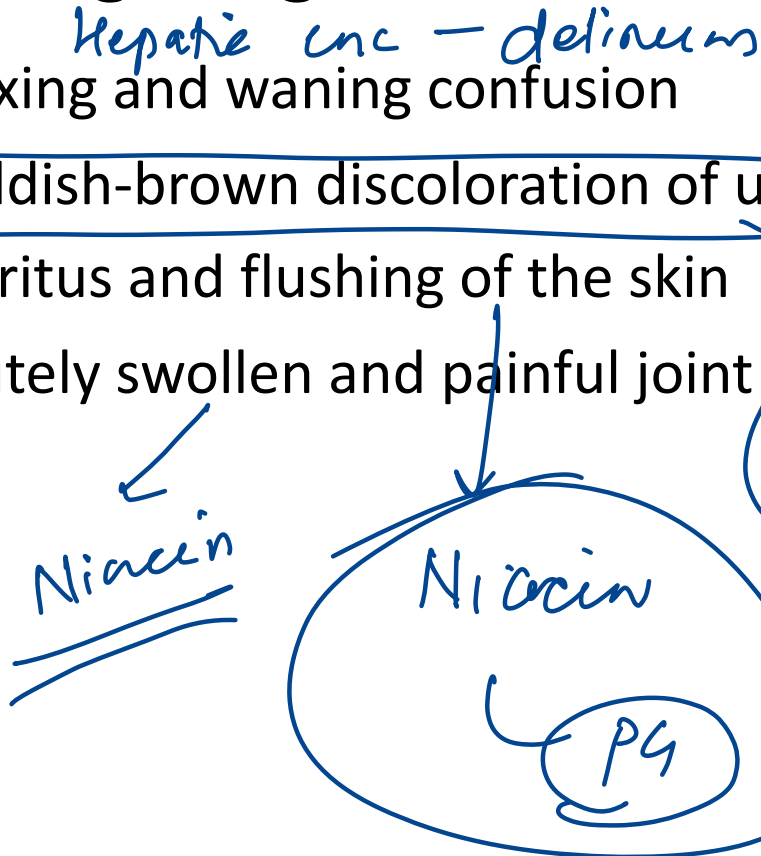
3. A 46-year-old man complains of dyspnoea and chest discomfort. He believes that the symptoms are due to a respiratory infection he had 4 weeks ago, but he did not see a doctor at that time. ECHO is shown below. Which of the following additional findings may be seen?

- A. ~~High-pitched, early diastolic sound~~ → Pericardial rub
- B. Systolic anterior motion of mitral valve / HOCM
- C. Delta wave on ECG wPW
- D. Inferonasal ectopia lentis Homocystinuria



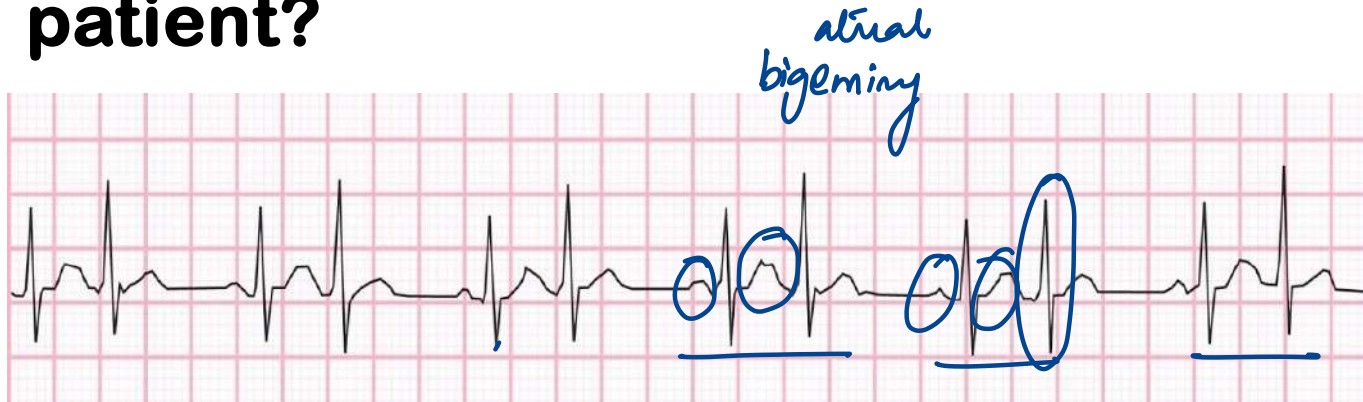4. A 53-year-old man with hyperlipidemia comes to the physician for a follow-up examination. His home medications include acetaminophen and atorvastatin. Serum studies show elevated total cholesterol and triglyceride concentrations. A drug that activates the peroxisome proliferator-activated receptor alpha is added to his existing therapy. This patient is most likely to develop which of the following drug-related adverse effects?

- A. Waxing and waning confusion
- B. Reddish-brown discoloration of urine
- C. Pruritus and flushing of the skin
- D. Acutely swollen and painful joint



- Atorvastatin
- Opioids
- Vancomycin
- Contrast
- Histamine

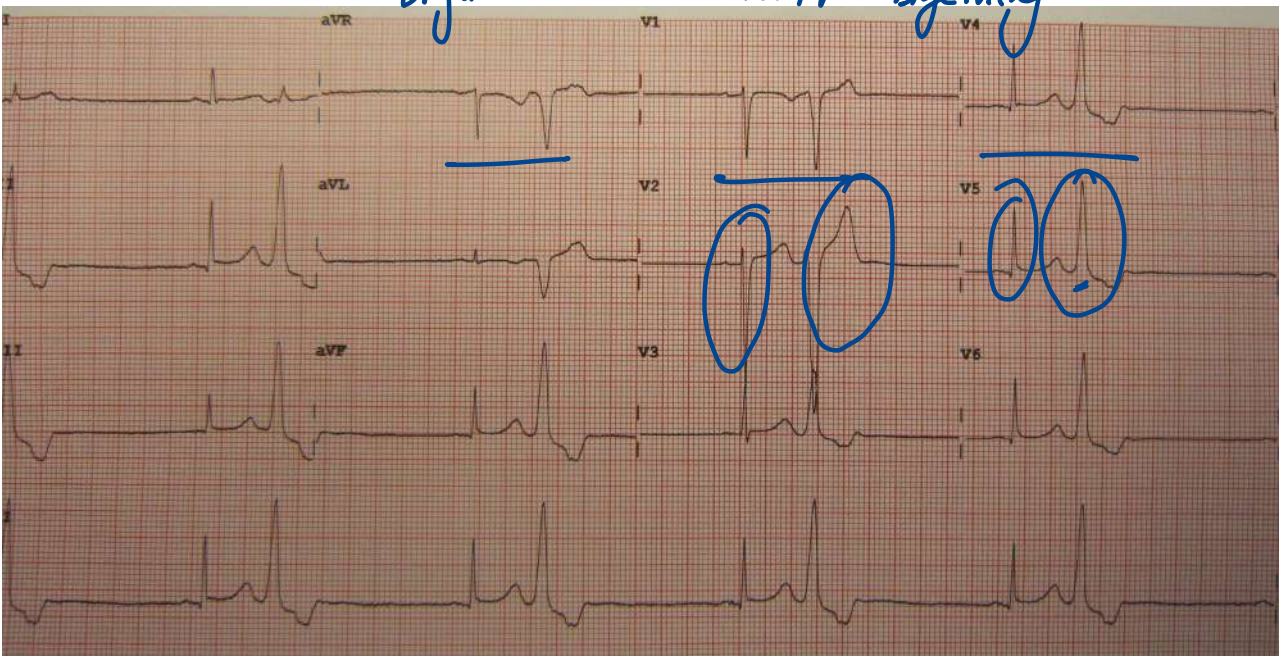
5. A 17-year-old boy presents with sudden-onset palpitations and light headedness while playing video games. He states this has occurred intermittently over the past year, but the episodes typically resolve spontaneously after a few minutes. He denies chest pain, shortness of breath, or syncope. ECG is shown below. Which of the following abnormalities is most likely present in this patient?



- A. Accessory pathway bypassing the AV node *x WPW*
- B. Degeneration of the atrioventricular conduction system *♡ block*
- C. Ectopic atrial pacemaker activity
- D. Dysfunction of the sinoatrial node *sick sinus sx*

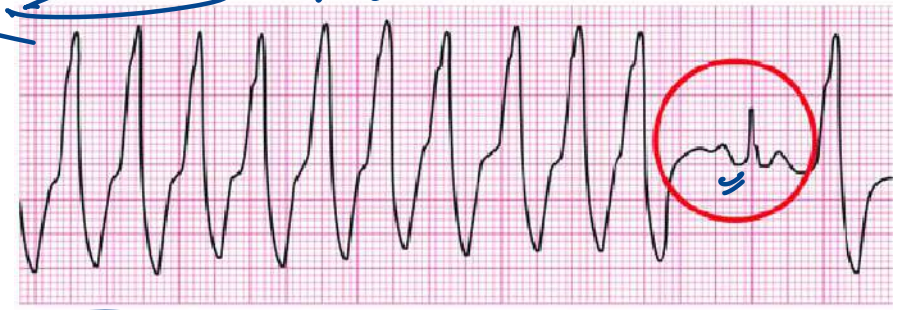
Digoxin

ventr bigeminy

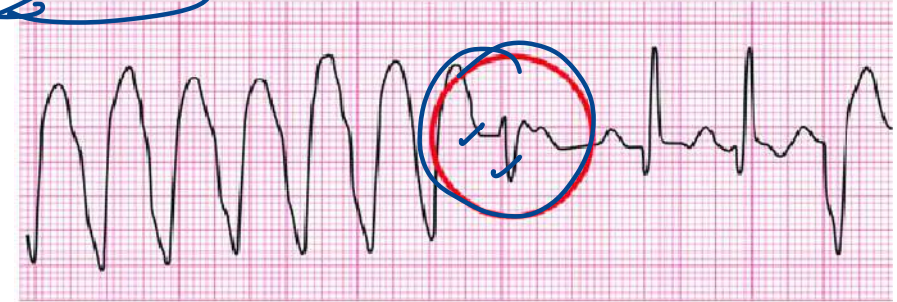


Capture beat:

V. tach



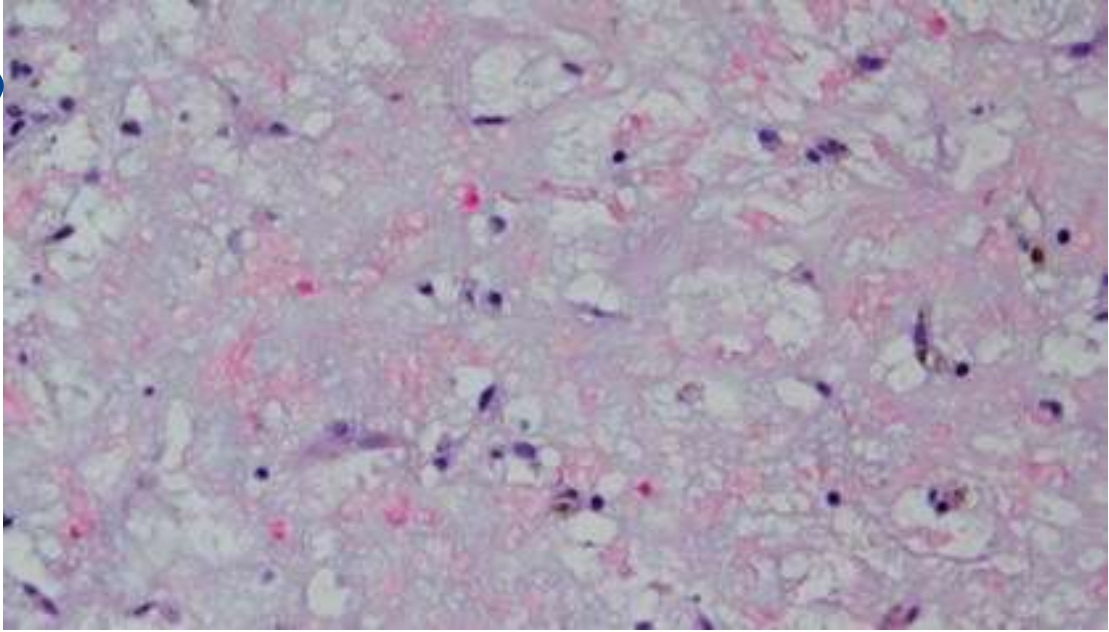

Fusion beat:



6. A 35-year-old woman is brought to the emergency department due to severe right leg pain. Right-sided dorsalis pedis and posterior tibial pulses are absent, and the popliteal pulse is barely palpable. Emergency embolectomy is performed and a gelatinous mass causing arterial occlusion is successfully removed. Histopathologic section of the mass is shown in the image below. Which of the following is the most likely origin of this patient's embolus?

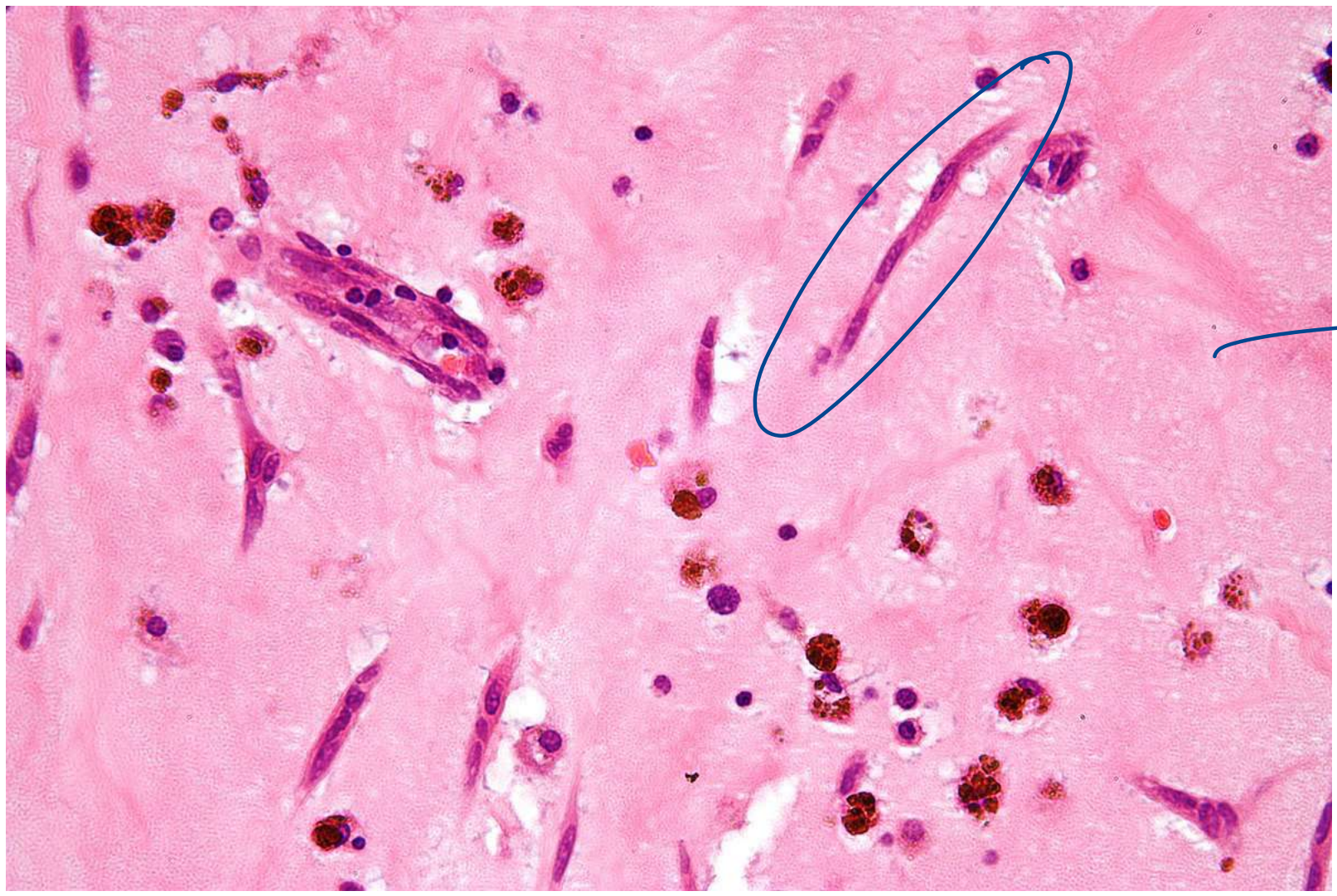- A. Femoral vein
- B. Descending aorta
- ~~C. Left atrium~~
- D. Left ventricle

children
Rhabdomyoma
C & spider cells
TSC



Lepidic

mesenchymal



gelatinous matrix.

7. Which of the following statements is true about beta blockers:

1. Carvedilol is the most widely used beta blocker. CF BMC
2. These are drug of choice in acute decompensated heart failure. ~~XX~~
3. Pindolol would be less likely to induce severe bradycardia in comparison to the other β -blockers. ISA
4. Sotalol can prolong the AP duration leading to torsade's de pointes. ✓

A. 1, 2, 3, ~~4~~

B. 3, 4

C. 1, 3, 4

D. ~~2, 4~~

ATD(S) - K^+ ⊖

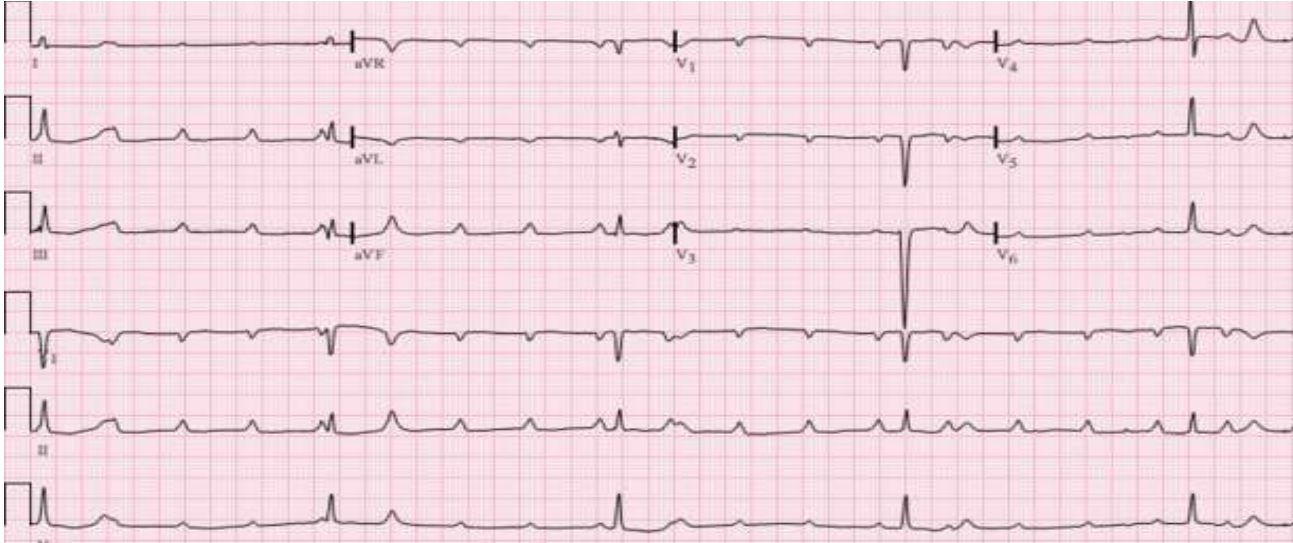
Class III
Ia

ISA—Acebutolol, Celiprolol, Pindolol, Carteolol, Labetalol (A+B)

Cardioselective

nonselective

8. 67-year-old man comes to the emergency department with light-headedness and generalized weakness for the last 2 days. He has chronic stable angina with exertion. However, over the last 2 days he has also had occasional chest discomfort at rest. The patient's medical problems include hypertension and bronchial asthma. He has no shortness of breath, cough, or peripheral edema. His only medications are aspirin and isosorbide dinitrate. Blood pressure is 105/66 mmHg. Electrocardiogram obtained in the emergency department is shown here.



AV dissociation
complete heart block

Which of the following is the best next step in management of this patient?

A. Adenosine X

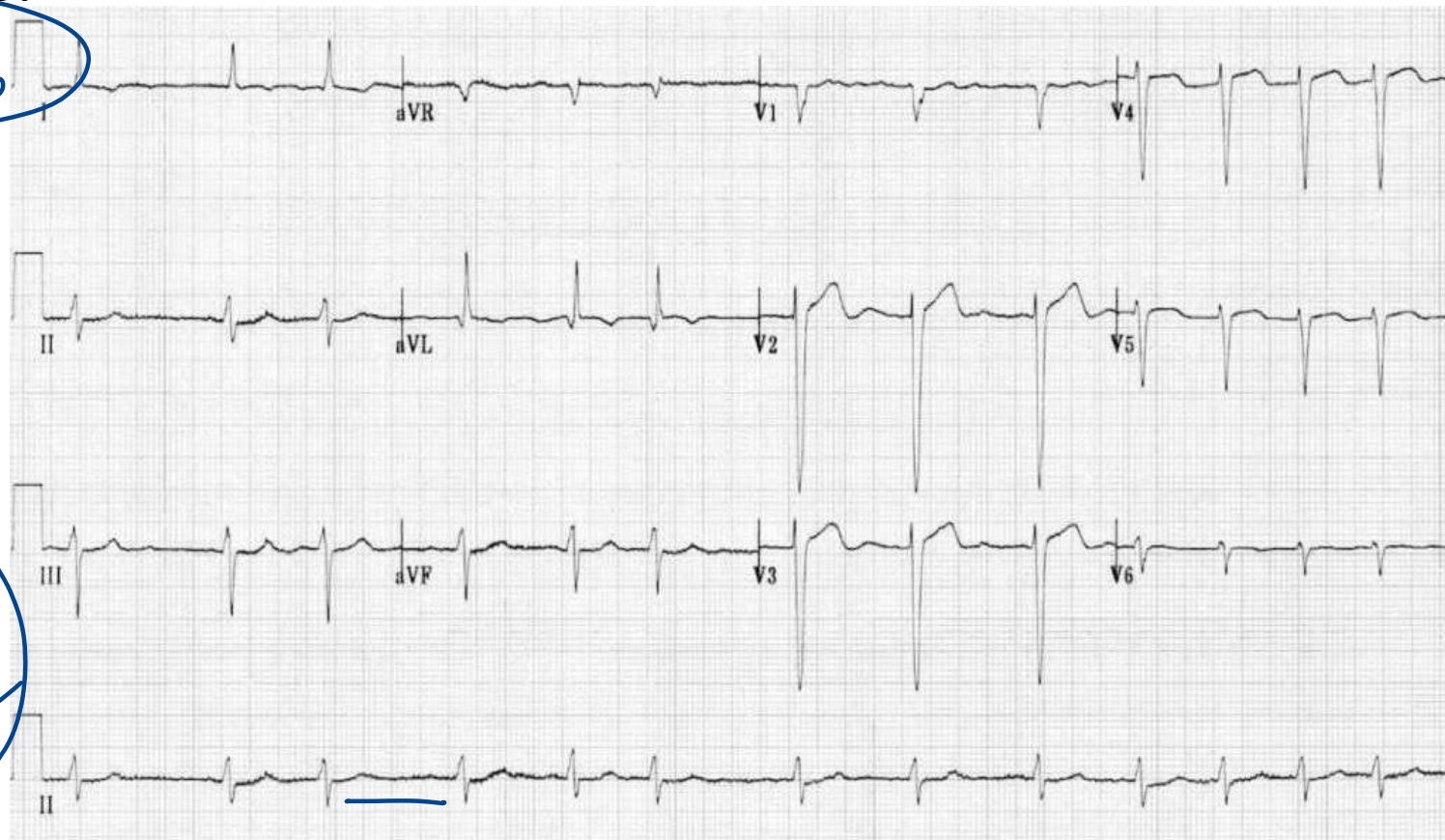
B. Cardiac pacing

C. Digoxin

D. Fibrinolytic therapy

Mobitz type 2 / type 3
AFib + CHF
STEMI

9. 64-year-old man with a history of hypertension and diet-controlled type 2 diabetes mellitus comes to the office due to generalized malaise and palpitations for the past 2 weeks. An echocardiogram last year showed mild left atrial dilation and left ventricular hypertrophy. The patient's medications include lisinopril and hydrochlorothiazide. Blood pressure is 170/90 mmHg. ECG is shown. Which of the following is the most appropriate next step in management of this patient?



A. Adenosine

B. Electric cardioversion

C. Diltiazem

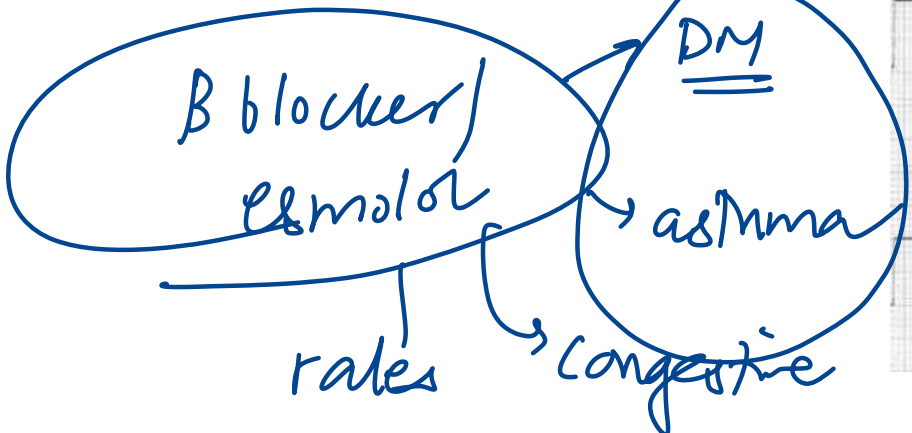
D. Lidocaine

→ P&VT

A.Fib

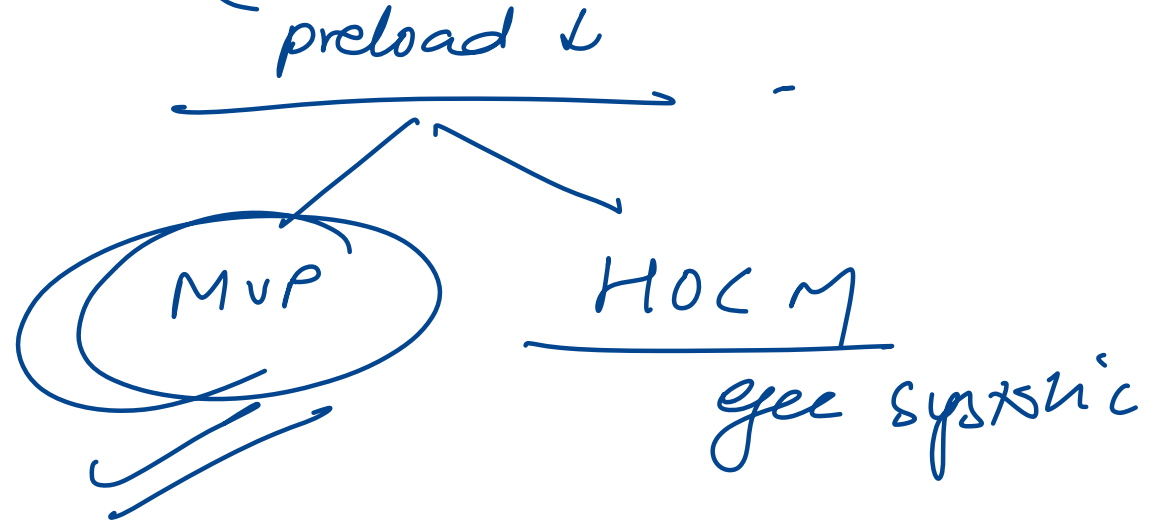
CCB

vFib / v.t. ca



10. 35-year-old woman comes to the OPD for a routine physical examination. The patient reports occasional palpitations but has no other chronic medical problems. She has caries of right upper molar tooth and is due to have an extraction next week. She has no significant medical history but had been told that she has "a murmur." The patient's only medication is a daily oral contraceptive. She lives a sedentary lifestyle and reports no dyspnea on routine activity. She developed hives with use of trimethoprim-sulfamethoxazole in the past. Blood pressure is 120/70 mmHg and pulse is 70/min. Physical examination shows no jugular venous distension in the upright position. Normal vesicular breath sounds are heard on chest auscultation. A late systolic murmur heard over the apex prolongs with the Valsalva manoeuvre. Which of the following is recommended for this patient prior to the procedure?

- A. Intravenous ampicillin
- B. Intravenous cefazolin
- C. No antibiotics
- D. Oral amoxicillin



Indications of prophylaxis required before dental procedures at high risk of endocarditis:

1. Prosthetic heart valve
2. Prior endocarditis
3. Unrepaired congenital heart disease
4. Completely repaired congenital heart disease (<6month)
5. Incomplete repaired congenital heart disease
6. Valvulopathy after cardiac transplant

11. A 34-year-old woman comes to the office due to exertional dyspnea. The patient has a history of IgA nephropathy; she received hemodialysis for 2 years before undergoing kidney transplantation last month. Chest x-ray reveals cardiomegaly and pulmonary congestion. Further evaluation determines that her symptoms are likely due to persistence of the arteriovenous fistula that was used for hemodialysis. Which of the following physiologic changes in 1) cardiac output, 2) systemic vascular resistance and 3) venous return respectively are present in this patient due to the fistula?

- A. Decreases, increases, decreases
- B. Decreases, increases, increases
- C. Increases, increases, decreases
- D. Increases, decreases, increases

AVF

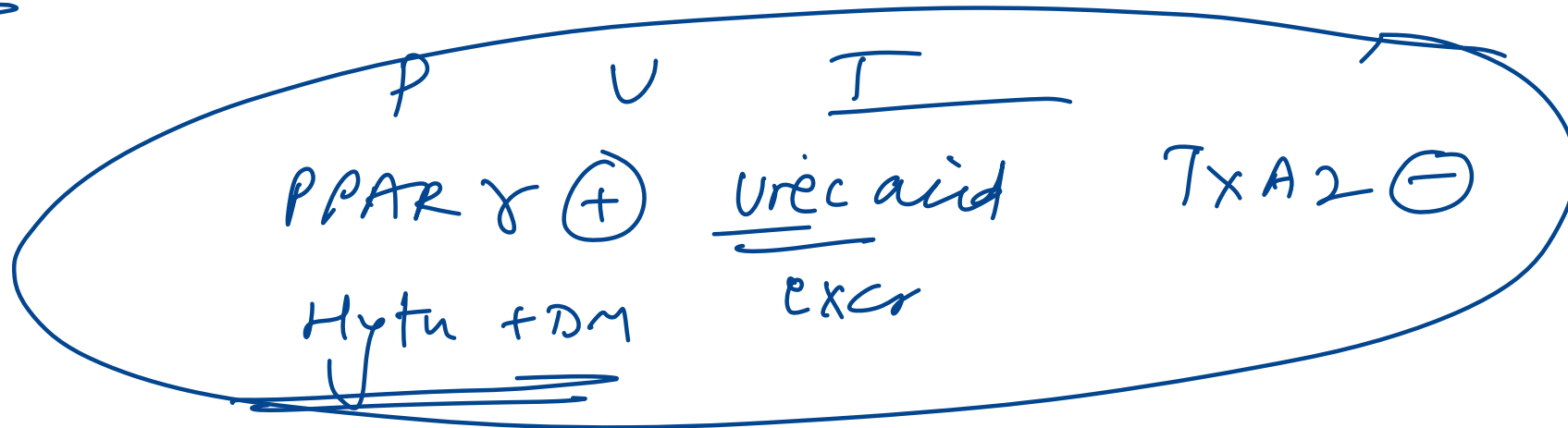
preload ↑

VR ↑

CO ↑

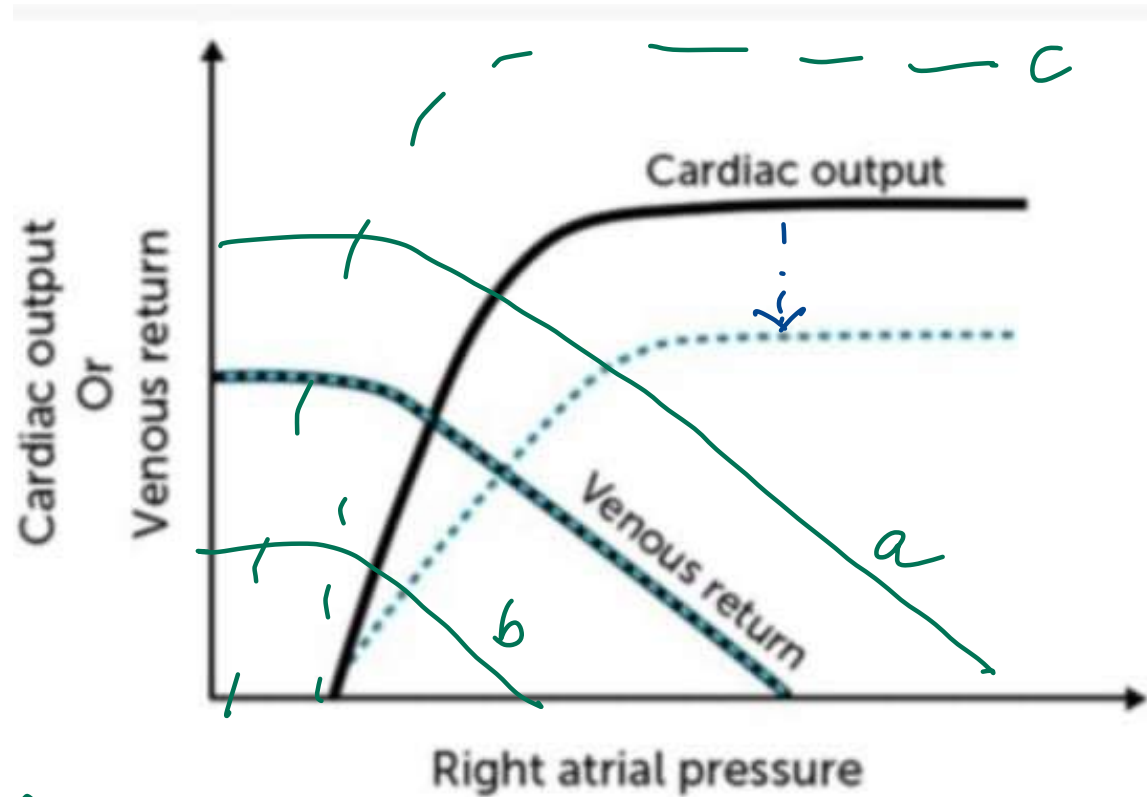
12. The true statement among the following is: PYQ.

- A. The dose of telmisartan should be reduced in renal ~~failure~~ but not in hepatic failure. *hepatic*
- B. The dose of irbesartan should be reduced in case of mild-moderate ~~hepatic~~ failure and renal failure. *severe*
- C. The dose of candesartan should be reduced in mild-moderate liver ~~failure~~ but not in renal failure. *renal*
- D. Losartan acts as thromboxane A₂ antagonist and inhibits platelet aggregation.

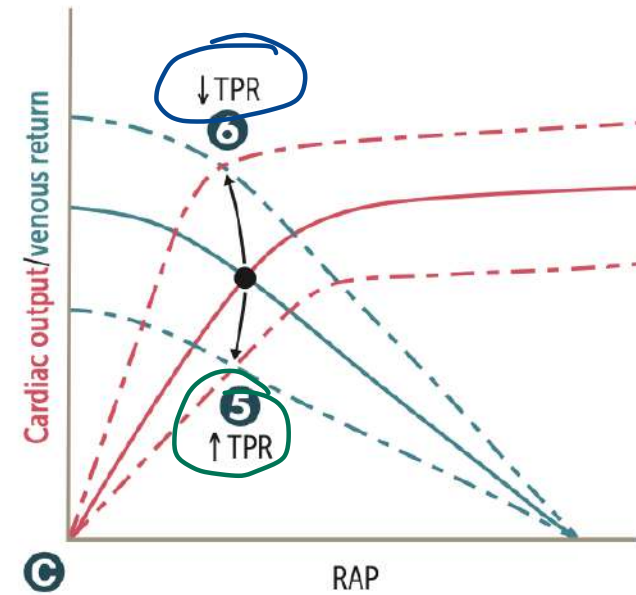
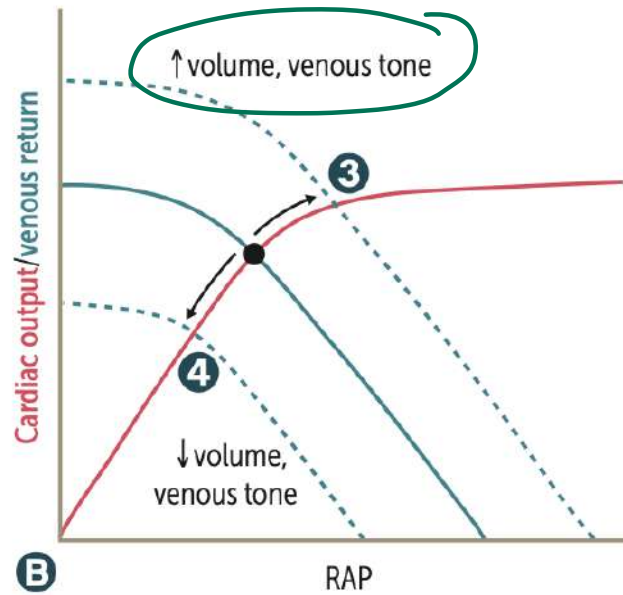
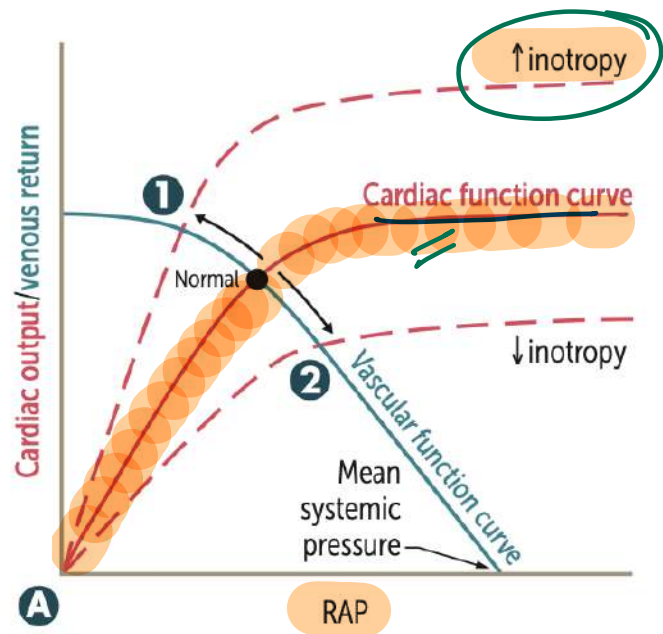


13. The cardiac output and venous return curves of a healthy person are shown below with solid lines. Which of the following is the most likely cause of the change depicted by the dashed lines?

- A. Excessive hydration
- B. Acute hemorrhage
- C. Chronic anemia
- ~~D. Myocardial infarction~~



HOCHF
 ANF AR Myocarditis
 pregn Beri Beri



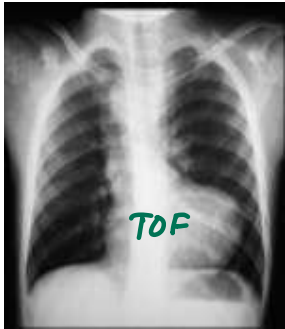
- 1 Catecholamines, dobutamine, digoxin, exercise ⊕
- 2 HF with reduced EF, narcotic overdose, sympathetic inhibition ⊖

- 3 Fluid infusion, sympathetic activity, arteriovenous shunt ⊕
- 4 Acute hemorrhage, spinal anesthesia ⊖

- 5 Vasopressors ⊕
 - 6 Exercise, arteriovenous shunt ⊖
- SVR ↓

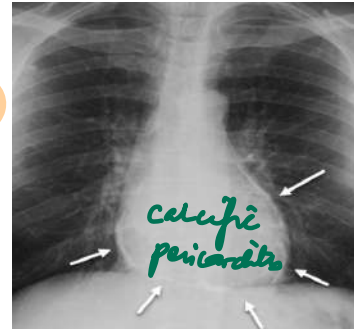
14. A 28-year-old man comes to the emergency department with a 3-day history of increasing chest tightness and intermittent sharp chest pains. The patient has no prior chronic medical conditions but had an upper respiratory illness a week ago that resolved without treatment. ECG reveals sinus tachycardia and low voltage QRS complexes that vary in the amplitude from beat to beat. Which of the following is the most likely chest x-ray finding in this patient?

A.



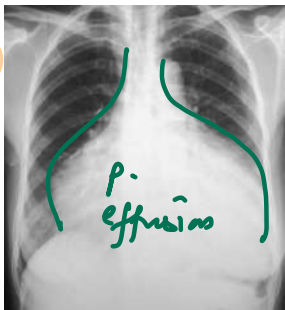electrical alternans
tamponade

C.


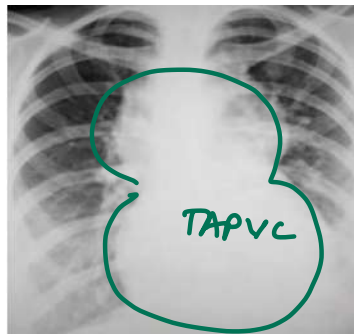


chronic pericarditis

B.



D.



15. A 68-year-old man comes to the OPD due to several weeks of progressive exertional dyspnea and lower extremity edema. Echocardiography shows biventricular dilation and a left ventricular ejection fraction of 35%. After initial stabilization, long-term use of which of the following medications will most likely improve survival in this patient?

- A. Furosemide
- B. Amlodipine *CCB*
- C. Carvedilol
- D. Digoxin
- E. ACE \ominus

\downarrow \ominus remodeling

CHF

β -blocker

ARNi

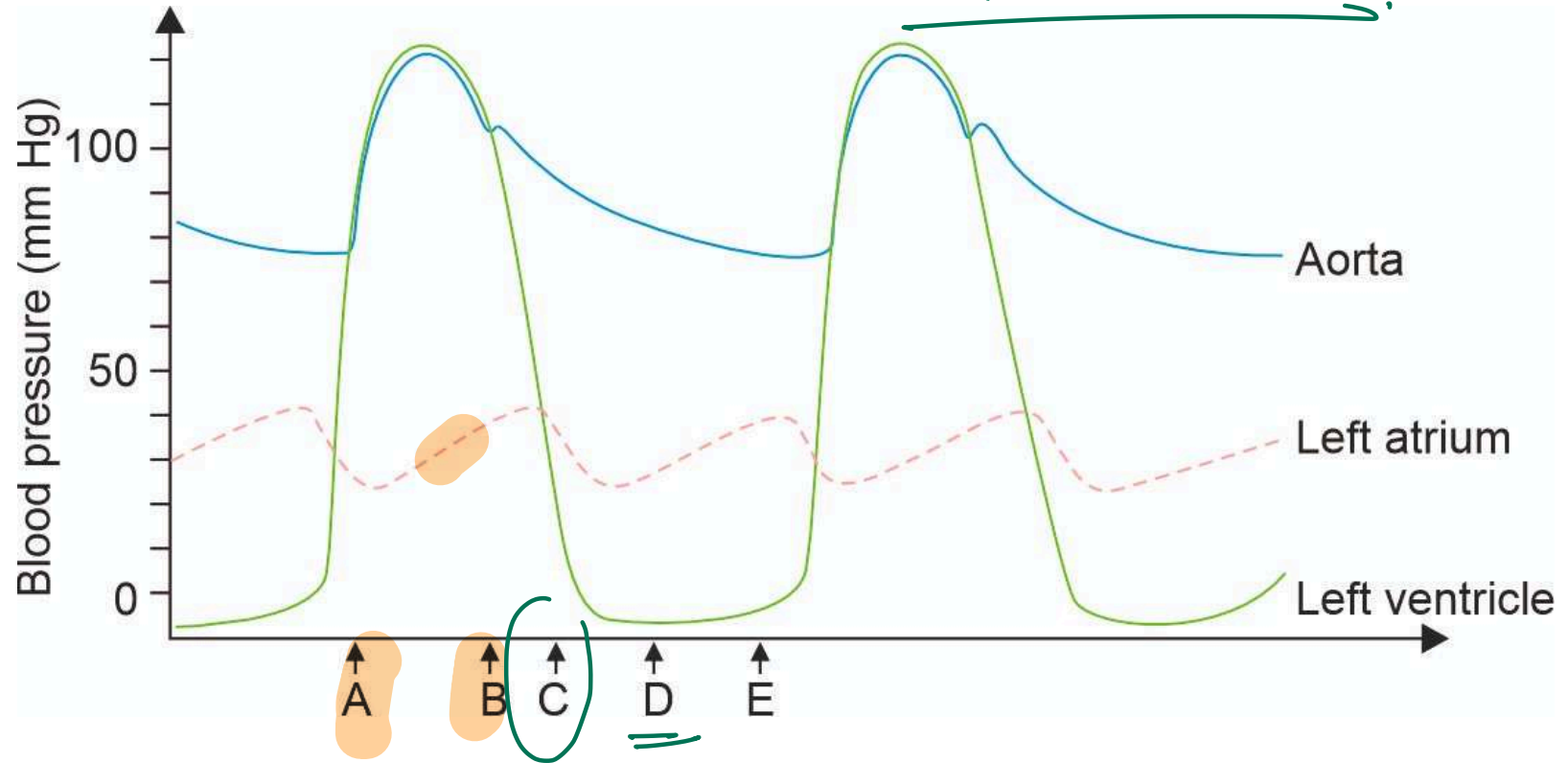
β blocker

MRA

SGLT 2 \ominus

16. 32-year-old woman with a history of mitral stenosis comes to the OPD. Cardiac auscultation reveals an opening snap and a rumbling murmur heard best in the left fifth intercostal space at the midclavicular line. Timing of these sounds best corresponds to which of the following letters?

- A. A
- B. B
- C. C
- D. E



17. An elderly man with diabetic nephropathy presented to the emergency department with palpitations and chest discomfort. The ECG is shown below. What is the next step?

A. Epinephrine $2 + B$

B. Glucagon XX

C. Atropine XX

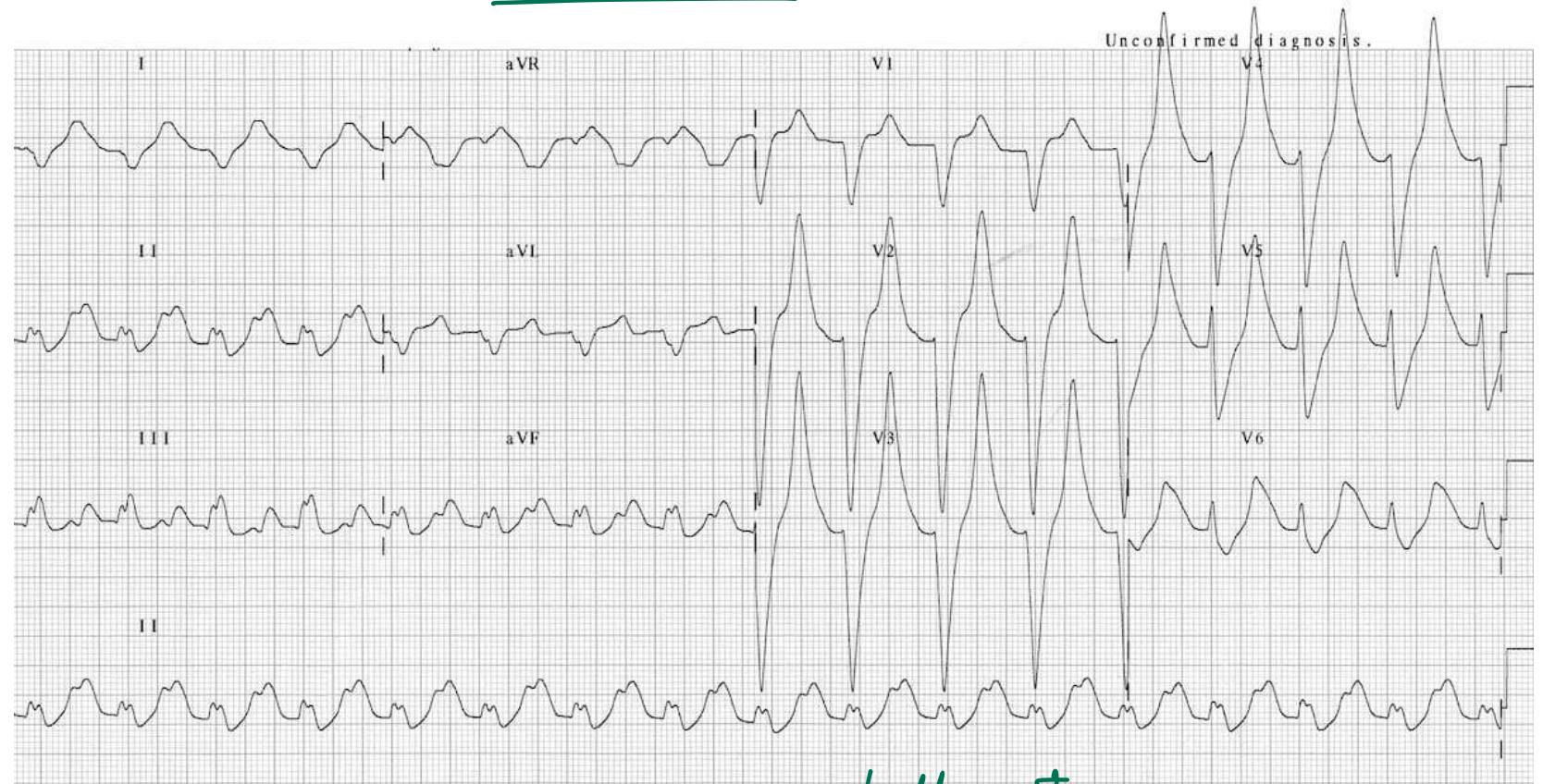
D. Lactic acid XX

~~E. Ca gluconate~~

1st \rightarrow

o Insulin + glc

o β -agonist



tall T waves

$\uparrow K^+$

18. 44-year-old man reports exertional shortness of breath and palpitations. On examination, he has a systolic murmur at the left sternal border and cardiac apex, which gets louder when he stands up. He is diagnosed with obstructive hypertrophic cardiomyopathy and paroxysmal atrial fibrillation and is started on a medication. Changes in the action potential of ventricular muscle cells before and after administration of medication are shown in the image below. The patient is most likely being treated with which of the following medications?

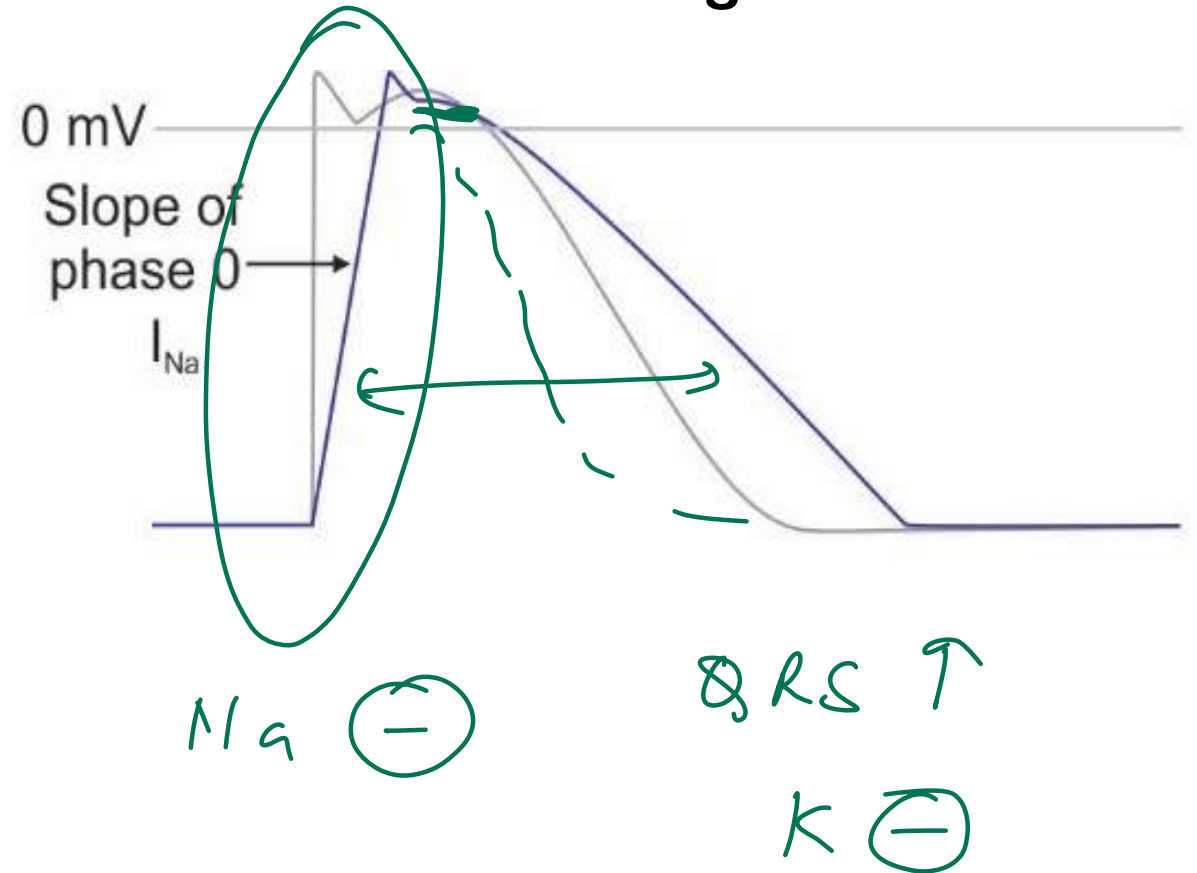
A. Lignocaine *Ib*

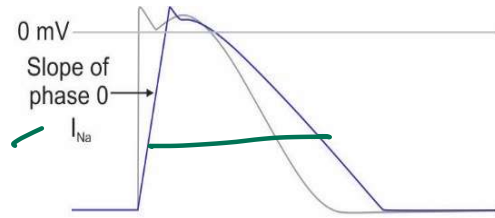
B. Digoxin *XX*

C. Diltiazem *CCB XX*

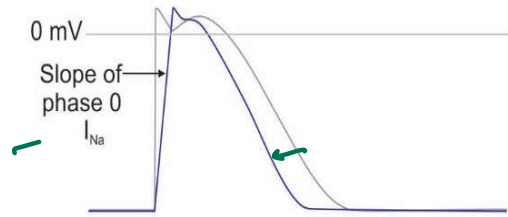
D. Disopyramide

Ia

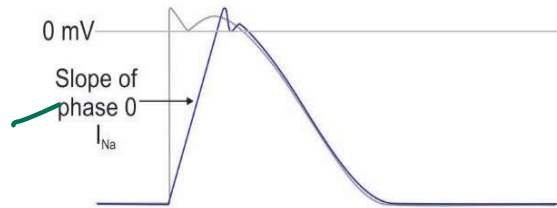




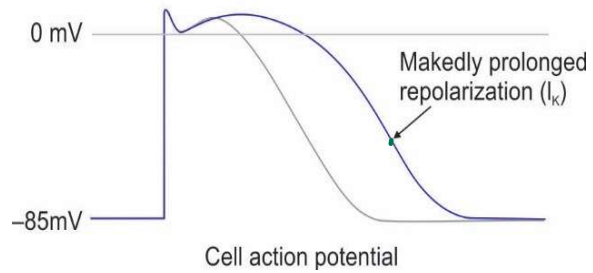
I_a



I_b



I_c



K^{\ominus}

III

AIDS



19. Deep y descent in JVP is seen in all except:

- A. Cardiac tamponade
- B. RCM
- C. Constrictive pericarditis
- D. Tricuspid regurgitation


emptying rapid

par

tax

prominent

y blunted



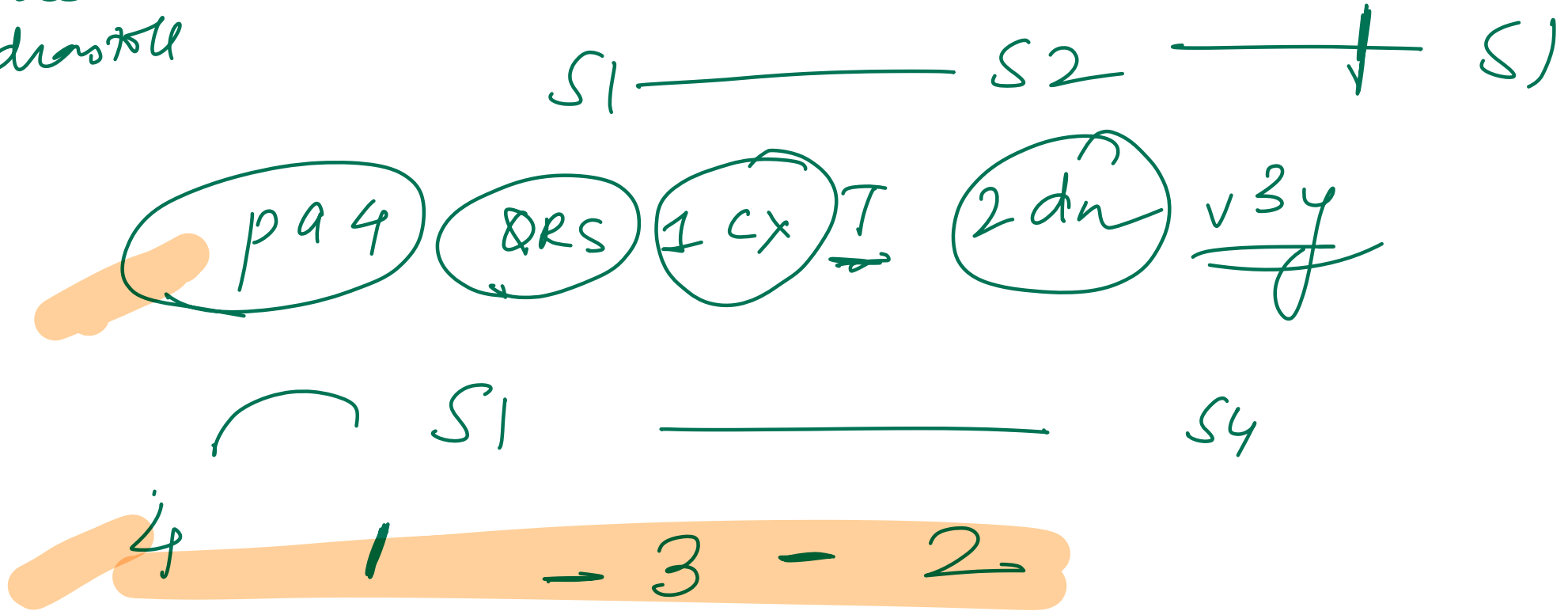
RV
compliance ↓

20. Arrange the following phases of cardiac cycle in sequential order from systole to diastole:

1. S1 - systole
2. S4 - late diastole
3. y descent - diastole
4. R wave

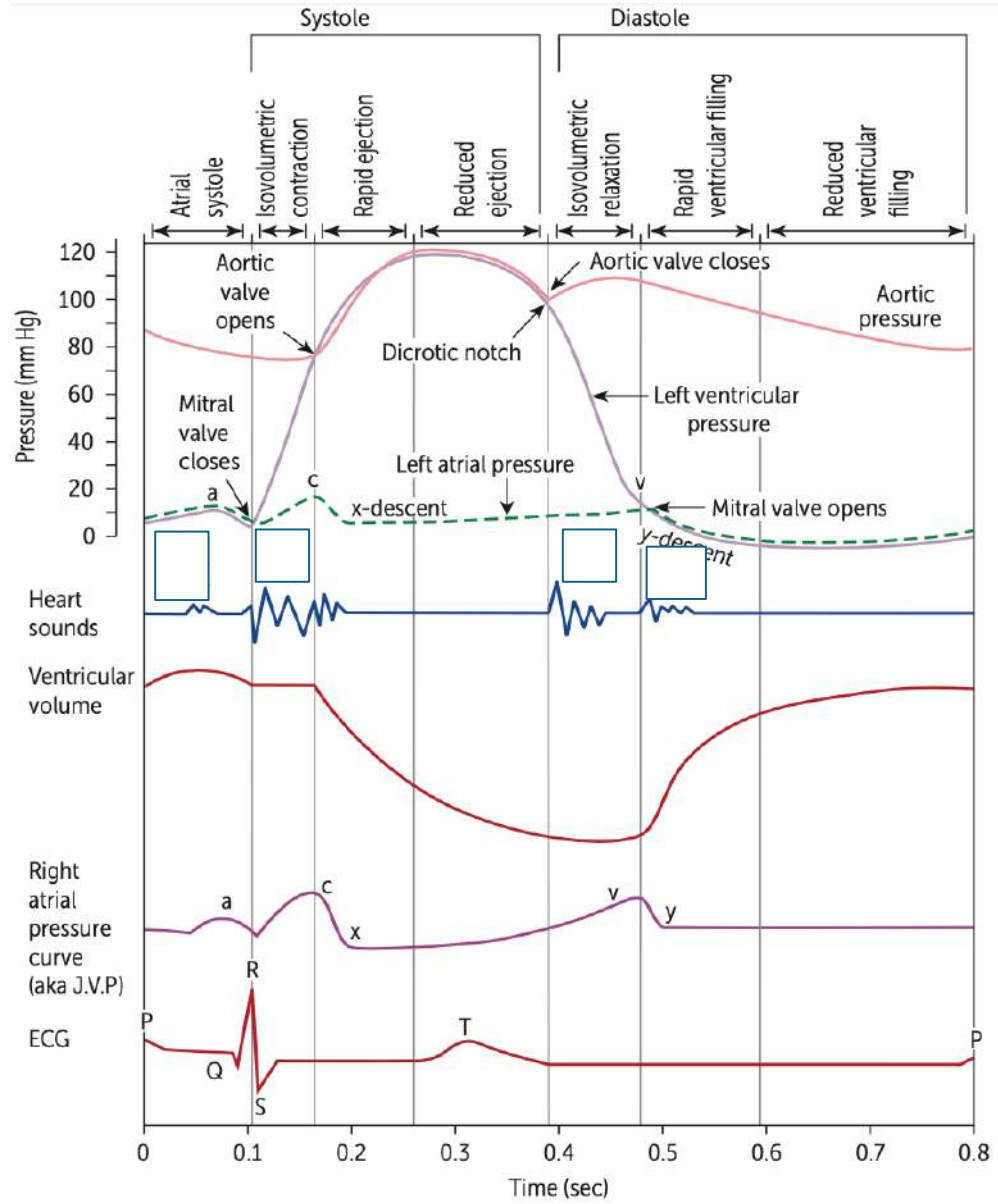
Options;

- A. 1-2-3-4
- B. 4-1-3-2
- C. 2-3-4-1
- D. 3-1-2-4



Wiggers diagram

P a4 QRS 1 cx T 2dn v 3y



21. A 34-year-old man develops severe chest and abdominal pain while shopping in a mall. Paramedics arrive and find him in severe distress. Several minutes later, he suffers a cardiac arrest with pulseless electrical activity and cannot be resuscitated. Postmortem examination reveals an internal hemorrhage as the cause of death. Histochemical evaluation of the patient's tissues reveals a defect affecting a large extracellular glycoprotein. This protein is normally found abundantly in large blood vessels, periosteum, and zonular fibers of the lens and functions to form microfibrils by surrounding elastin. This patient most likely suffered from which of the following conditions?

- A. Ehlers-Danlos syndrome
- B. Homocystinuria
- C. Marfan syndrome
- D. Osteogenesis imperfecta

Fibrillin

Marfan

22. The absence of loud S1 in mitral stenosis would indicate all of the following, except:

- A. Calcified valve ✓
- B. Aortic regurgitation ✓
- C. First degree heart block ✓
- D. Mild mitral stenosis

Pyg

Loud S1: MS, Reduced PR (WPW-Child), Hyperdynamic circulation

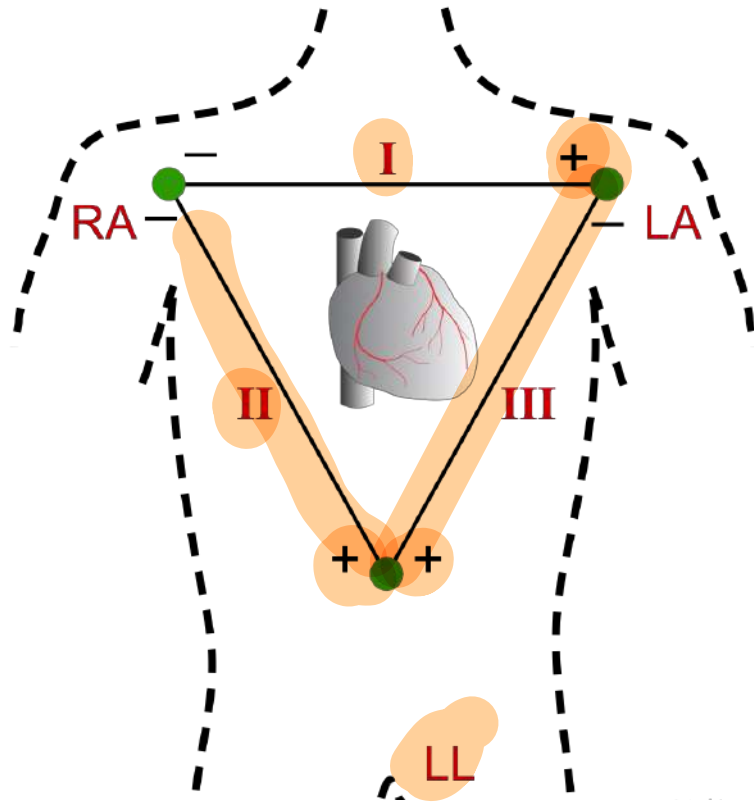
Soft S1: MR/TR, CHF, Calcified valves, Prolonged PR (1st degree heart block)

AR →

23. Which of the following is true regarding the placement of ECG leads?

Pyq.

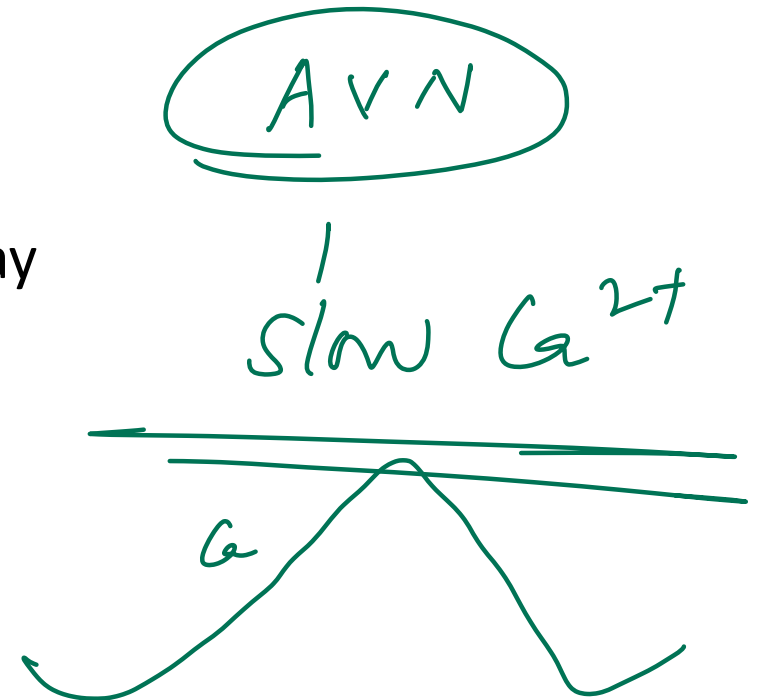
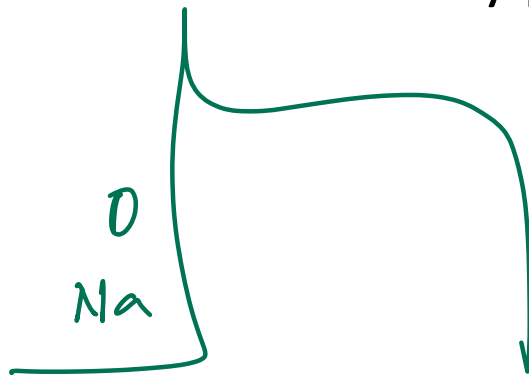- A. The earth to all leads is in the right leg
- B. Lead I: Positive pole to the right and negative pole towards the left
- C. Lead II: Positive pole on the left and negative pole towards the right
- D. Lead II: Positive pole on the right and negative pole towards the left



$$\text{III} + \text{I} = \text{II}$$

24. A 62-year-old woman comes to the emergency department due to palpitations and shortness of breath that began an hour ago. Medical history includes hypertension, coronary artery disease, and paroxysmal atrial flutter. Blood pressure is 108/76 mm Hg and pulse is rapid. ECG shows atrial flutter with a ventricular rate of approximately 150/min. The estimated atrial rate based on ECG flutter waves is 300/min. Which of the following is most likely responsible for the rate difference between the atria and the ventricles?

- A. Calcium current within the atrioventricular node
- B. Calcium current within the sinoatrial node
- C. Sodium current within an atrioventricular accessory pathway
- D. Sodium current within the atria



25. A 65-year-old man is admitted to the hospital with an acute ST-segment elevation myocardial infarction. The patient undergoes coronary angiography with stent placement in the left circumflex artery, and he is started on therapy with a beta blocker and antiplatelet agents. On day 3 of hospitalization he experiences chest pain. The pain, described as sharp and radiating to his neck and shoulders, is exacerbated by coughing and swallowing. Temperature is 37.5 C (99.5 °F), blood pressure is 130/80 mmHg, pulse is 90/min and regular, and respirations are 20/min. The lungs are clear on auscultation. There is no peripheral edema. Which of the following is the most likely cause of this patient's chest pain?

- A. Pericardial inflammation due to autoimmune reaction to necrotic tissue
- B. Pericardial inflammation due to concomitant viral infection
- C. Pericardial inflammation overlying the necrotic segment of myocardium
- D. Recurrent thrombosis of the culprit coronary vessel

Dressler delayed

MI

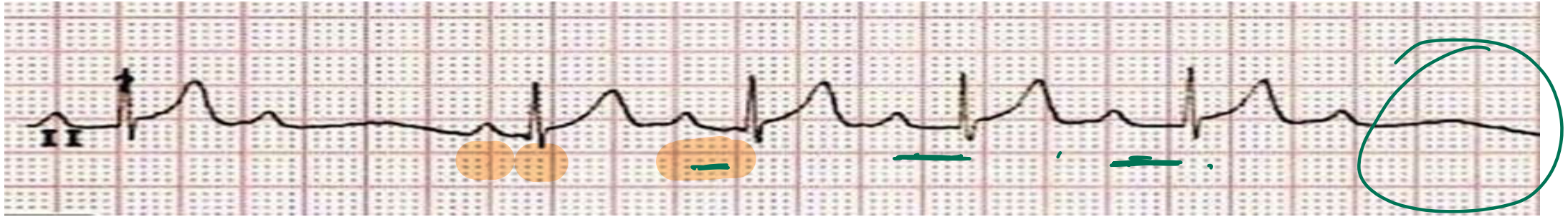→ pericarditis

< 1 wk

> 1 wk

Dressler &

26. Identify the conduction abnormality from the ECG given below:



A. First degree heart block *PR ↑*

B. Mobitz type 1

C. Third degree heart block

D. Mobitz type 2

PR (N)

He disappear



27. A 55-year-old man comes to the OPD due to recurrent episodes of retrosternal chest pain. The episodes occur during physical activity, usually when he climbs stairs or walks uphill, and resolve after he rests for a few minutes. He is prescribed sublingual nitroglycerin to take as needed when the chest pain occurs. This drug is most likely to relieve this patient's symptoms by causing which of the following hemodynamic changes?

- A. Decrease in heart rate ~~XX~~ HR ↑
- B. Decrease in left ventricular end-diastolic volume
- C. Decrease in peripheral arteriolar resistance venous
- D. Increase in coronary blood flow

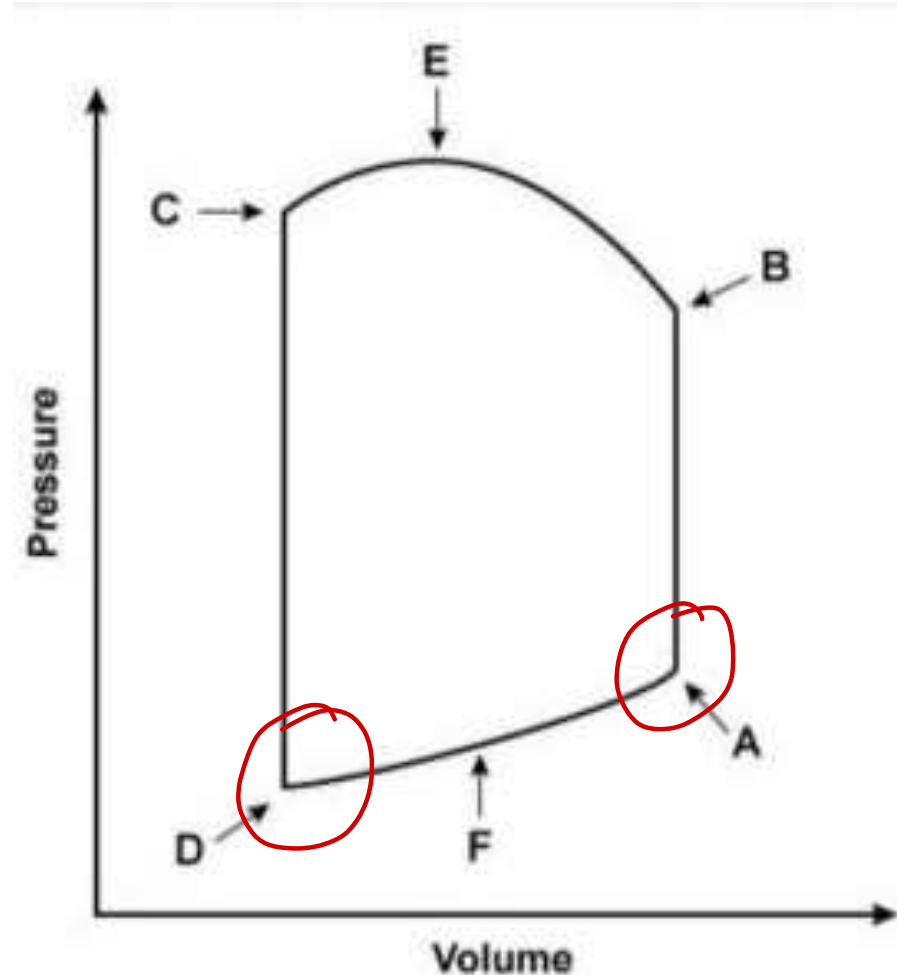
~~↓ cbf ↑ epicardial~~
Hydralazine

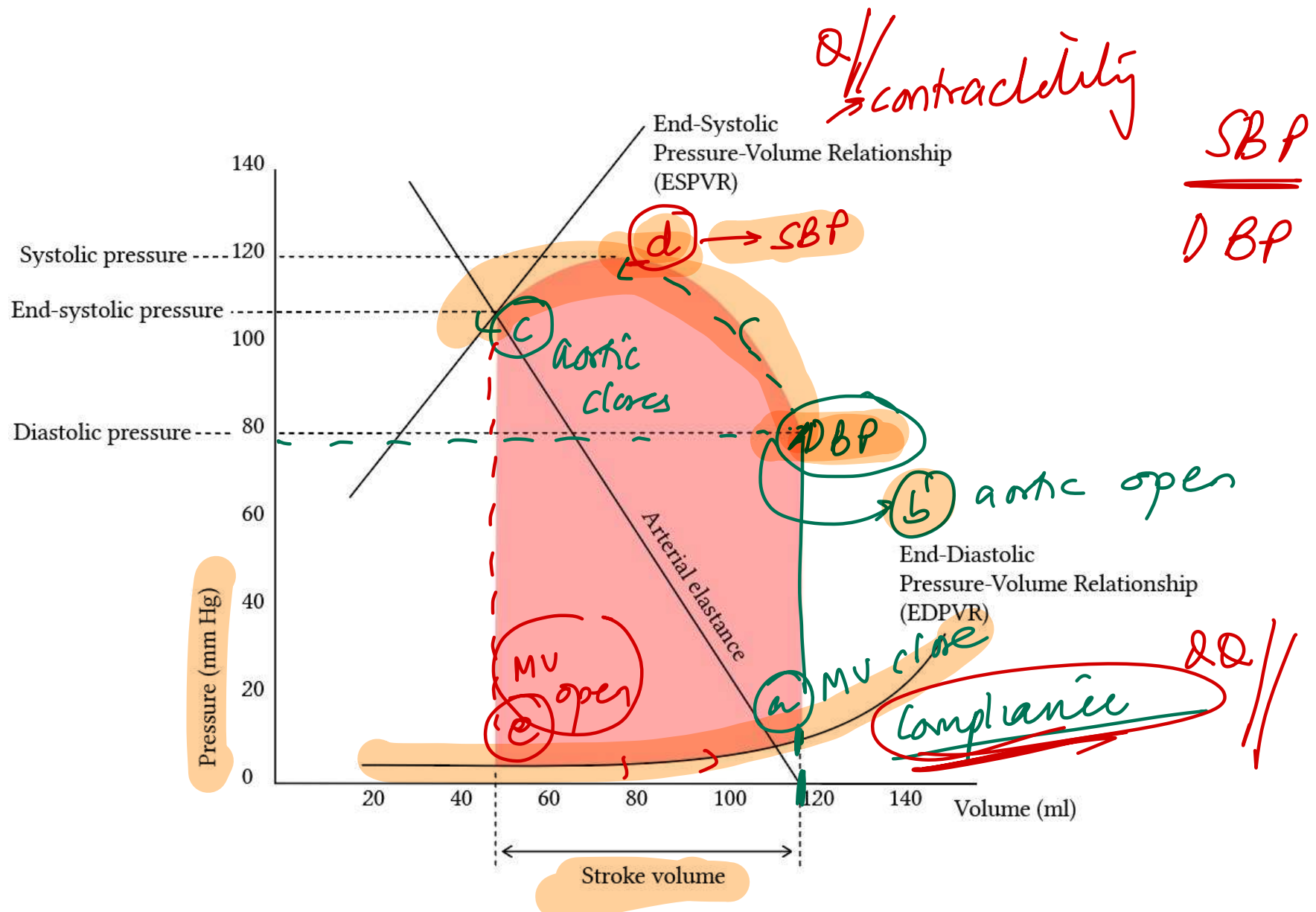
venodilator
CGMP ↑
↓ preload

28. 34-year-old woman comes to the physician due to weakness, exertional dyspnea, and orthopnea. On cardiac auscultation, a snap followed by a rumbling diastolic murmur is heard over the cardiac apex. The snap most likely occurs nearest to which of the following points on the cardiac pressure-volume loop?

- A. A
- B. B
- C. C
- ~~D. D~~

M/S





29. A 66-year-old man comes to the emergency department because of shortness of breath. His temperature is 37.2°C (99°F) and pulse is 105/min. When the blood pressure cuff is inflated to 140 mm Hg, the patient's pulse is audible and regular. However, upon inspiration, the pulse disappears and does not reappear until expiration. Only when the blood pressure cuff is inflated to 125 mm Hg is the pulse audible throughout the entire respiratory cycle. Which of the following underlying conditions is most likely responsible for this patient's physical examination findings?

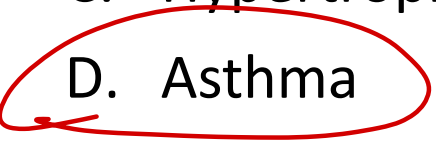
- A. Mitral regurgitation
- B. Lobar pneumonia
- C. Hypertrophic cardiomyopathy

D. Asthma

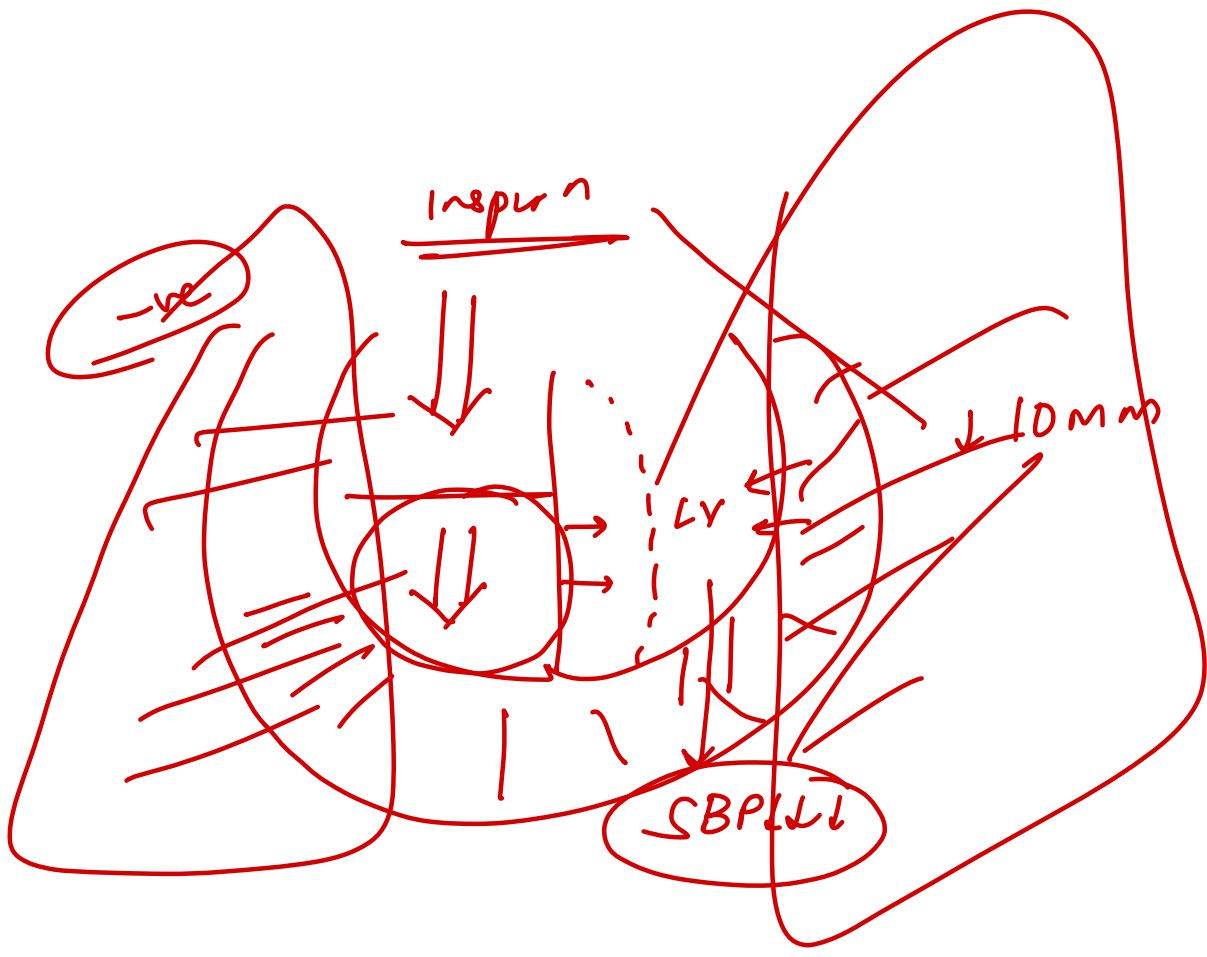
Pulsus paradoxus

fall >10mm Δ SBP

during inspiration



/ COPD / CP / tamponade



A 60-year-old man with a known history of diabetes mellitus presents with a BP of 150/90 mmHg and dizziness. What is the best way to manage this patient?

- A. Diet, Exercise, Lifestyle modification + Metoprolol
- B. Diet, Exercise, Lifestyle modification
- C. Diet + Prazosin
- D. Diet, Exercise, Lifestyle modification + Amlodipine

Hypertension

Category	SBP	DBP
Normal	<130	<85
High-normal	130-139	85-89
Grade 1 hypertension	140-159	90-99
Grade 2 hypertension	>160	>100

AHA 2025

Blood Pressure Category	Systolic BP (mm Hg)	Diastolic BP (mm Hg)
Normal	Less than 120	Less than 80
Elevated	120-129	Less than 80
Stage 1 Hypertension (High BP)	130-139	80-89
Stage 2 Hypertension (High BP)	140 or higher	90 or higher
Severe Hypertension	Higher than 180	and/or higher than 120

Emergency: Severely elevated BP with acute hypertension mediated organ damage (HMOD) → \hat{N}

Urgency: Severely elevated BP without acute hypertension mediated organ damage (HMOD) → oral

→ R_p → LMO
 → R_1 - Drug ← Comorbidity

Hypertension with:
 DM / CKD / Scleroderma- ACE ⊖ / ARBs
 Osteoporosis / Renal stones- Thiazides
 Raynaud / Cyclosporine induced- CCB
 BPH- α ⊖
 Migraine / Thyrotoxicosis / Angina / Tremor- Propranolol

31. A 74-year-old man comes to the physician for a 6-month history of progressively worsening fatigue and shortness of breath on exertion. His pulse is 89/min and blood pressure is 145/60 mm Hg. Crackles are heard at the lung bases. Cardiac examination shows a grade 3/6 early diastolic murmur loudest at the left sternal border in the third intercostal space. Further evaluation of this patient is most likely to show which of the following?

- A. Pulsus parvus et tardus
- B. Pulsus paradoxus
- C. Fixed splitting of S2
- ~~D. Water hammer pulse~~

AR / PR
E/D'S

32. A previously healthy 52-year-old woman comes to the physician because of a 3-month history of chest pain on exertion. She takes no medications. Cardiopulmonary examination shows no abnormalities. Cardiac stress ECG shows inducible ST-segment depressions in the precordial leads that coincide with the patient's report of chest pain and resolve upon cessation of exercise. Pharmacotherapy with verapamil is initiated. This drug is most likely to have which of the following sets of effects?

- A. End diastolic volume (EDV) increase, BP decrease, Contractility decrease, HR decrease
- B. End diastolic volume (EDV) decrease, BP decrease, Contractility decrease, HR decrease
- C. End diastolic volume (EDV) increase, BP no change, ~~Contractility increase~~, HR decrease
- D. End diastolic volume (EDV) decrease, BP increase, Contractility decrease, ~~HR no change~~

CCB

B

33. A 52-year-old man with a history of type 2 diabetes mellitus managed with diet and exercise undergoes treadmill stress testing for complaints of intermittent fatigue. He reports no chest pain during the test but stops after 6 minutes due to exertional

• Vitals:

- Resting heart rate: 72/min; peak stress heart rate: 138/min
- Resting blood pressure: 120/75 mm Hg; peak stress: 135/82 mm Hg.

• ECG shows normal sinus rhythm without ischemic changes.

• Physical exam and echocardiogram at rest are unremarkable.

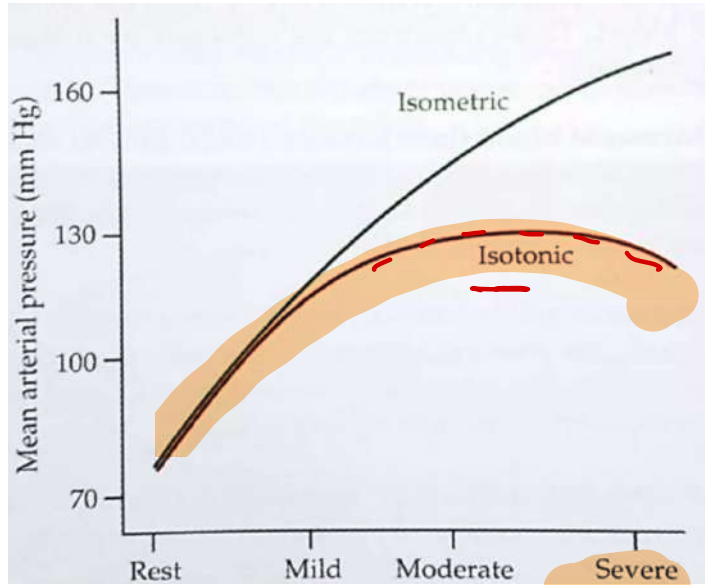
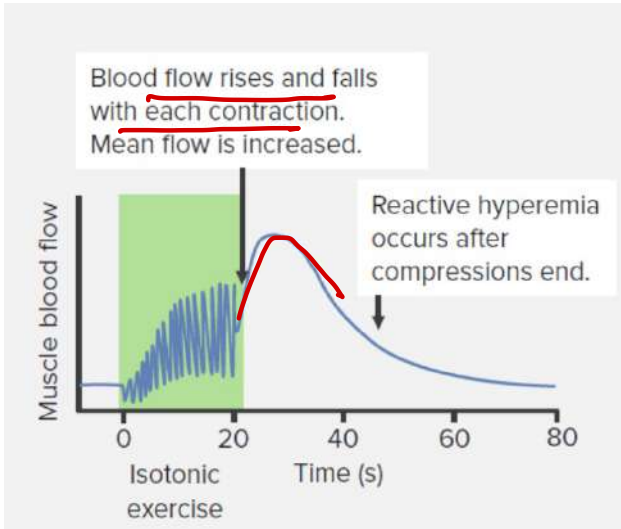
During exercise, which of the following hemodynamic parameters is most likely to be decreased compared to the resting state?

- A. Cardiac output \uparrow
- B. Left ventricular end-diastolic pressure
- C. Systemic systolic blood pressure \uparrow
- D. Total systemic vascular resistance \downarrow

Preload \uparrow

exercise

SVR \downarrow \leftarrow vasodilation
fever



Isotonic exercise:

CO: ↑

HR: ↑

SV: ↑

SBP: ↑

TPR: ↓

DBP: ↓

MAP: ↓

2/3 DBP

1/3 SBP

Isometric exercise:

CO:

HR:

SV:

SBP:

TPR:

DBP:

MAP:

34. A 60-year-old woman is brought to the emergency department due to severe central chest pain that started a few hours ago. ECG shows ST-segment elevation in leads I, aVL, and V1–V4, along with deep Q wave formation over the next several hours. Cardiac catheterization would most likely reveal which of the following?

- A. Atherosclerotic plaque obstructing 50% of the coronary artery lumen, no thrombus
- B. Atherosclerotic plaque obstructing 80% of the coronary artery lumen, no thrombus
- C. Ruptured atherosclerotic plaque with fully obstructive thrombus**
- D. Significant coronary artery vasospasm causing flow obstruction

Stable
Angina
>70%
Stenosis
Fragmental

35. A 76-year-old man is admitted to the hospital due to worsening dyspnea and fatigue. He has a history of chronic atrial fibrillation and heart failure with reduced ejection fraction (HFrEF). The patient is started on oral digoxin for rate control. A week later, his serum digoxin level is measured and found to be markedly elevated, despite receiving an appropriate dose. Upon further questioning, it is discovered that the patient was recently started on amiodarone. Which of the following mechanisms best explains the interaction between the drugs?

Options:

- A. Blockade of biliary transport proteins
- B. Induction of cytochrome P-450 enzymes
- C. Inhibition of P-glycoprotein
- D. Stimulation of Na⁺/K⁺-ATPase

(-)

P-gp

Amiodarone, verapamil, quinidine, cyclosporine, and clarithromycin

⊖ P-gp

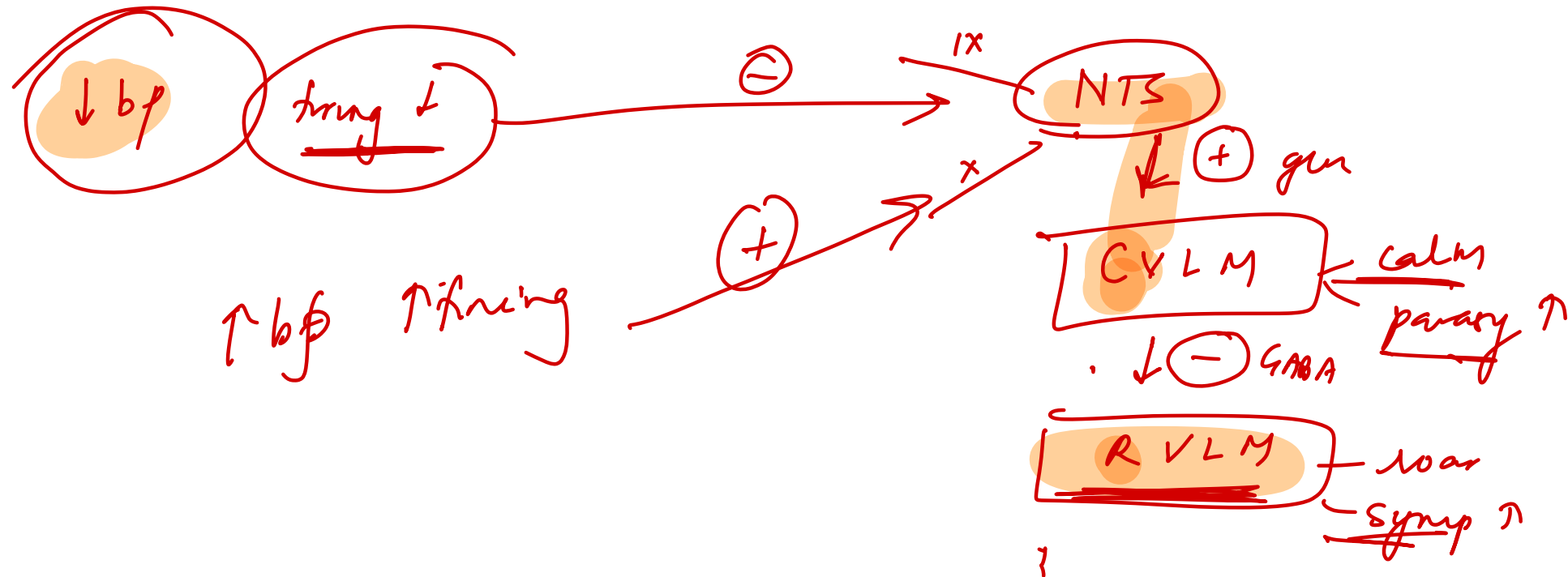
36. Below (proximal) the carotid sinus, carotid artery clamping is likely to result in:

- A. Increase in a vasomotor centre activity
- B. Increase in the discharge of carotid sinus afferent nerves
- C. Decreased heart rate and blood pressure
- D. Baroreceptor adaptation

↓

↑

be
feedback



37. Oxygen sensitive channels in peripheral chemoreceptors are for which of the following ion? (FMGE JULY 2024)

A. K^+

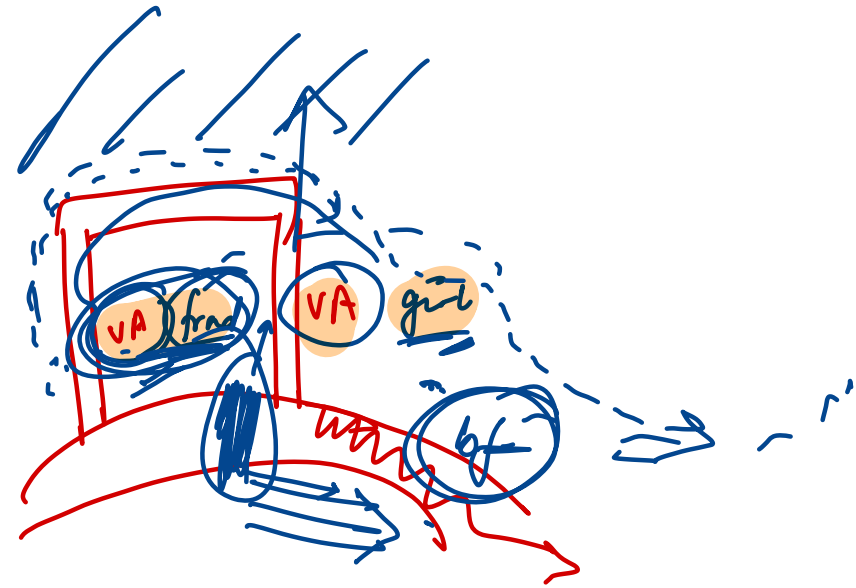
B. Na^+

C. HCO_3^-

D. Cl^-

38. A 65-year-old man with a long history of hypertension and type 2 diabetes presents to the clinic complaining of dizziness and weakness in his left arm when performing activities like playing table tennis. He has been a chronic smoker for over 40 years. ECG shows normal sinus rhythm, and orthostatic vital signs are normal. A Doppler ultrasound of the left vertebral artery shows retrograde flow instead of normal antegrade flow. Which of the following arteries is most likely stenosed or occluded to cause these findings?

- A. Left internal carotid artery
- B. Left vertebral artery
- C. Left subclavian artery
- D. Right subclavian artery

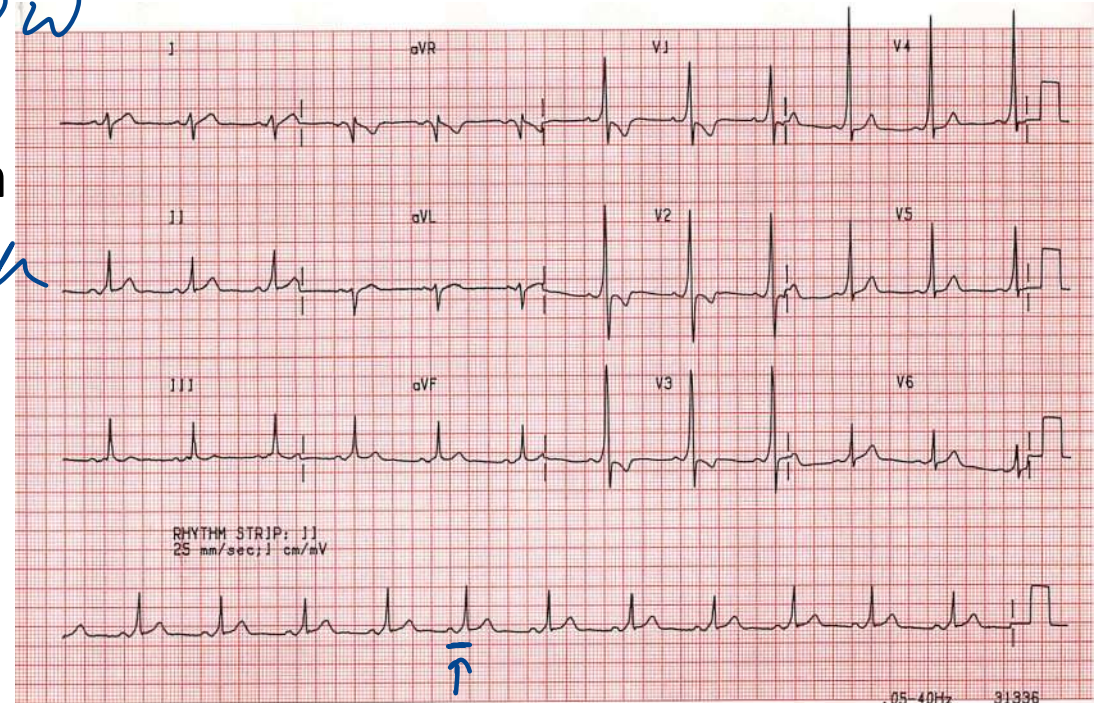


39. A 17-year-old boy presents with sudden-onset palpitations and lightheadedness while playing video games. He states this has occurred intermittently over the past year, but the episodes typically resolve spontaneously after a few minutes. He denies chest pain, shortness of breath, or syncope. ECG is shown below. Which of the following abnormalities is most likely present in this patient?

- A. Accessory pathway bypassing the AV node
- B. Degeneration of the atrioventricular conduction system
- C. Ectopic atrial pacemaker activity
- D. Dysfunction of the sinoatrial node

WPW

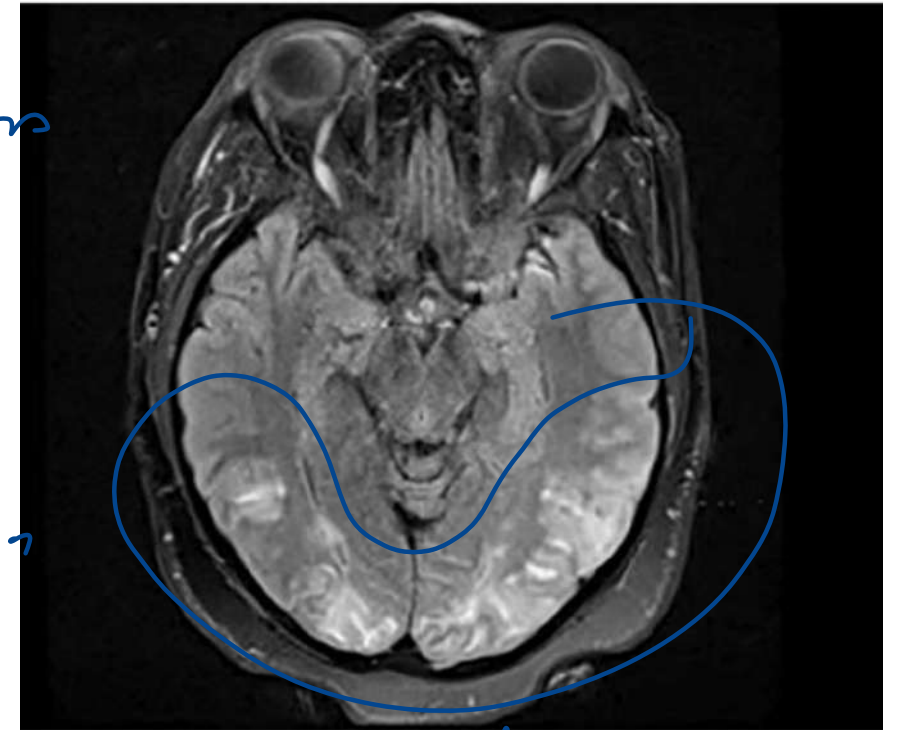
AV block



40. A 24-year-old G2 at 28 weeks is brought to the emergency after being found unconscious at home by her mother. She is disoriented on arrival and her BP is 180/110 mmHg and 4+ proteinuria. On arrival at the emergency, she has a tonic-clonic seizure which resolves with MgSO4 administration. Once the patient is stabilized, she undergoes caesarean delivery for fetal distress. Post-partum, the below MRI is done. What is the most likely finding on imaging?

- A. Subdural hematoma
- B. Parenchymal hemorrhage
- C. Subarachnoid hemorrhage
- D. Posterior reversible encephalopathy syndrome

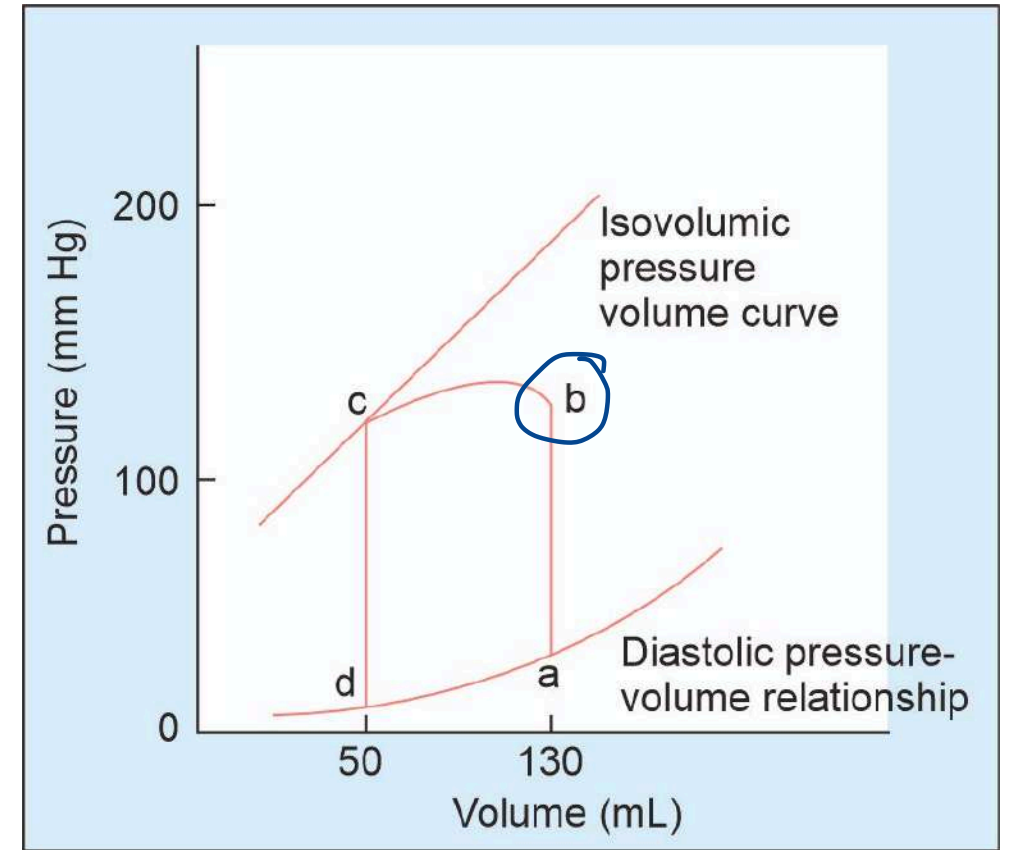
ICA
antoregns
post
post
crust



edema

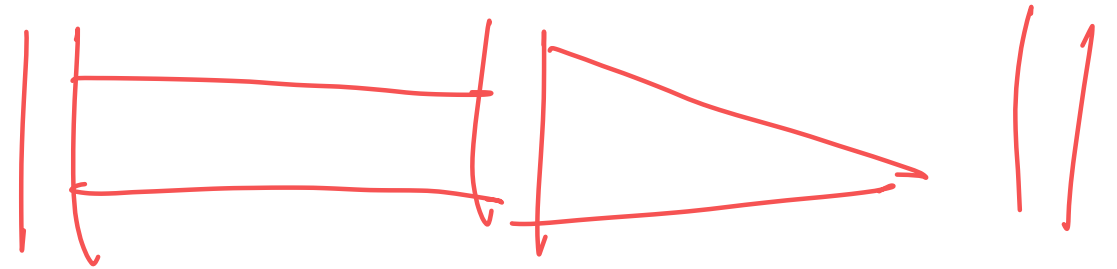
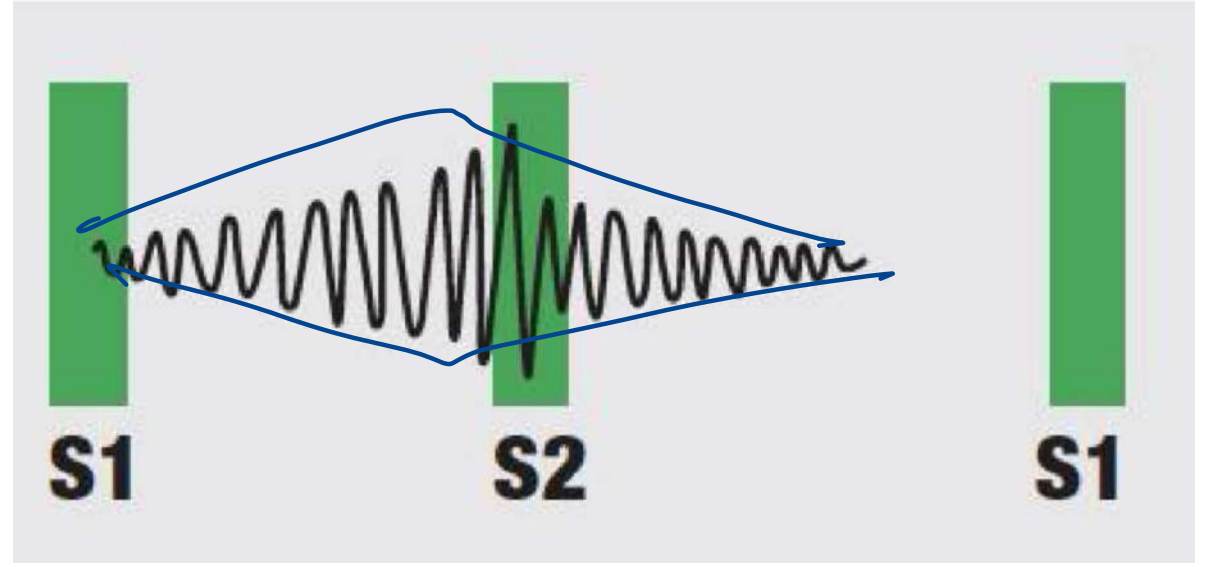
41. Which point in the following diagram indicates that the left ventricular pressure is equivalent to the diastolic blood pressure?

- A. a
- B. b
- C. c
- D. d



42. The following pattern of murmur is seen in all except:

- A. ^{*pan-systolic*} VSD with aortic regurgitation ^{*early diast*}
- B. Coronary AV fistula
- C. Rupture of sinus of Valsalva aneurysm
- D. PDA



43. A 45-year-old female patient has NYHA class III heart failure, with dyspnea, pedal edema and K⁺ levels of 5.5mg% and creatinine 1.1 mg%. Which of the following drugs can be used in this patient? (AIIMS NOV 2017)

- A. Digoxin X
- B. Spirolactone X
- C. Enalapril
- D. ~~Furosemide~~

3.5-5

K sparing diuretics
ACE-/ARB
B blockers
Calcineurin inhibitors
Digoxin
Pentamidine
NSAIDs
Sch
Heparin
Trimethoprim



$\uparrow K^+$

44. Which of the following is not a component of Syndrome Z in a 45-year old Indian man?

- A. Blood pressure 145/89mmHg
- B. Obstructive sleep apnea
- C. Waist circumference of 88cm
- D. Fasting triglyceride 160 mg/dl

Syndrome X
+ OSA

Metabolic syndrome: NCEP-ATP III

1. Central obesity:

>102 cm (India-90cm) in men

>88 cm (India-80cm) in women

2. Elevated triglycerides: >150 mg/dL

3. HDL

< 40 mg/dL in men

< 50 mg/dL in women.

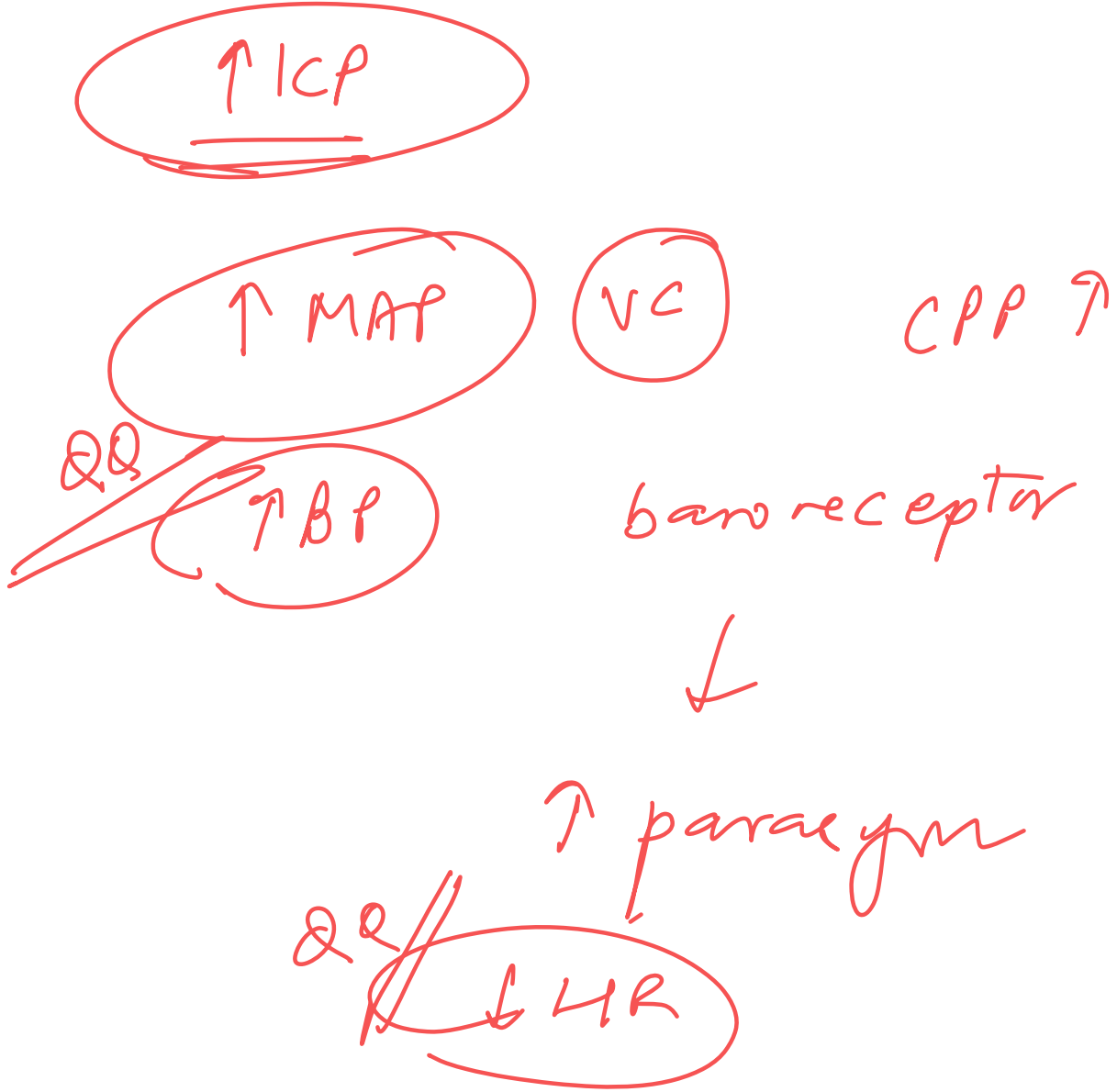
4. Blood pressure: >130/85 mm Hg

5. Fasting glucose: >100 mg/dL

YES

45. Which of the following is responsible for the bradycardia seen in Cushing reflex?

- A. Heart failure
- B. Baroreceptor activation
- C. Cardiac conduction defect
- D. Increased activity of RVLM



46. A 56-year-old man with hypertension comes to the physician for a follow-up examination. His blood pressure is 165/92 mm Hg on the left arm and 162/90 mm Hg on the right arm. He reports that he is adherent with his medication and exercise regimen. The physician adds a drug to his antihypertensive medication regimen. This drug increases serum renin, angiotensin I, and angiotensin II levels, and decreases serum aldosterone levels, without affecting bradykinin levels. Which of the following drugs was most likely added to this patient's medication regimen?

~~A. Candesartan~~

ARB

B. Aliskiren

Renin ⊖

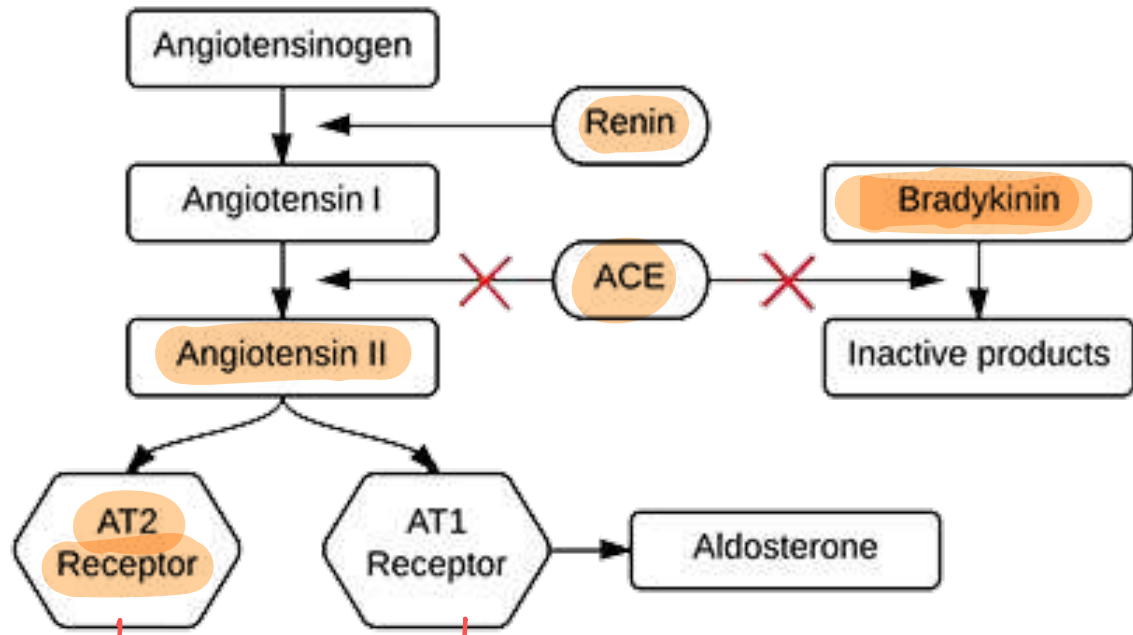
C. Verapamil

CCB

D. Lisinopril

XX

ACE ⊖

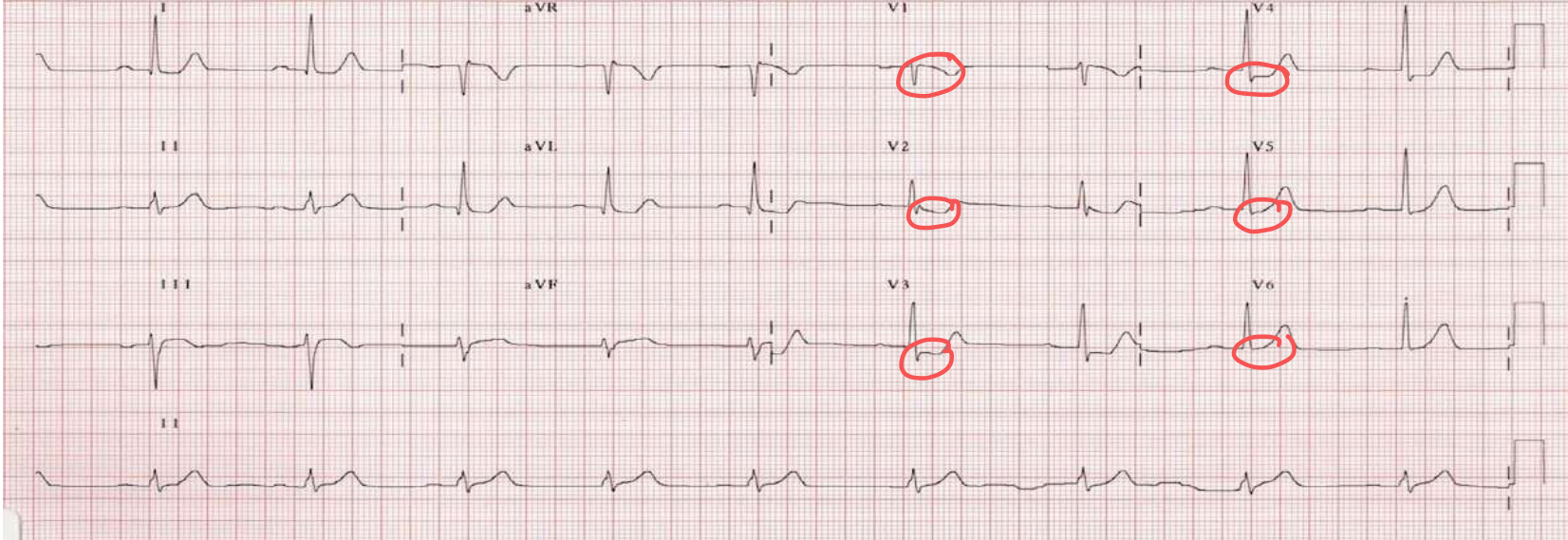


✗ = Site of ACEI Action

vasoconstriction, aldosterone secretion, renal sodium retention, and sympathetic nervous system activation.

Fetal, reproductive, brain: Vasodilation, anti-proliferation, apoptosis, tissue repair

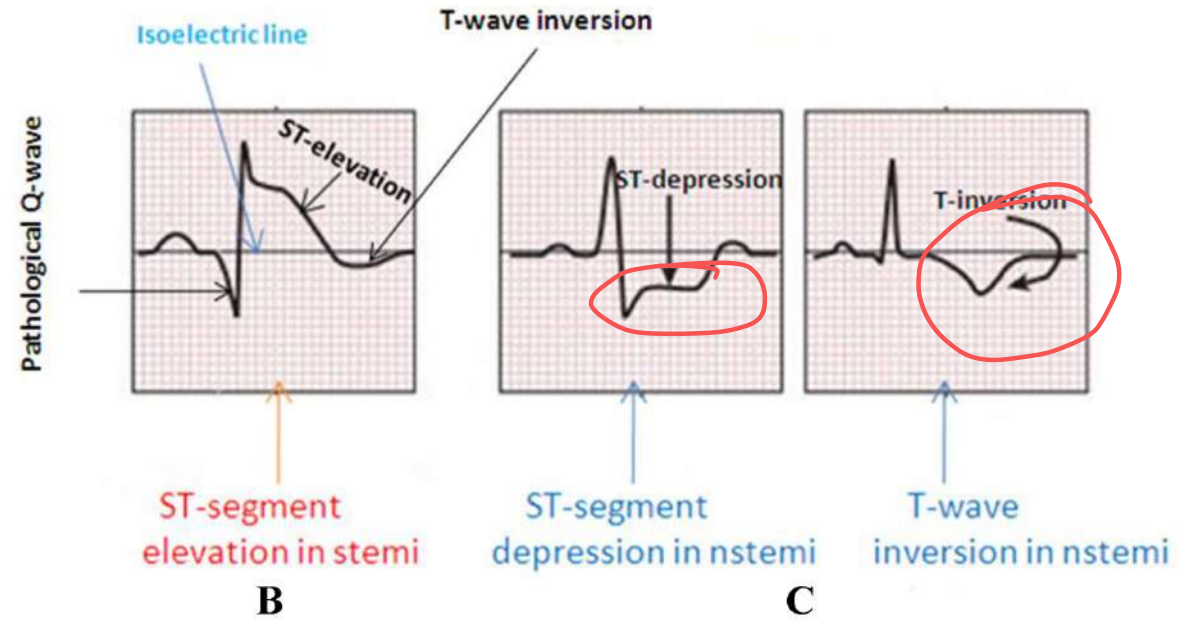
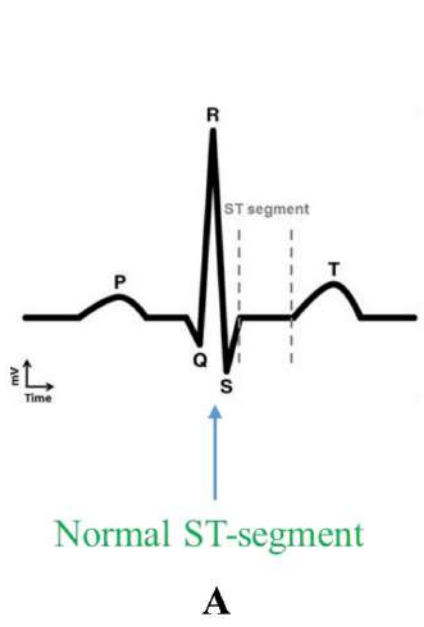
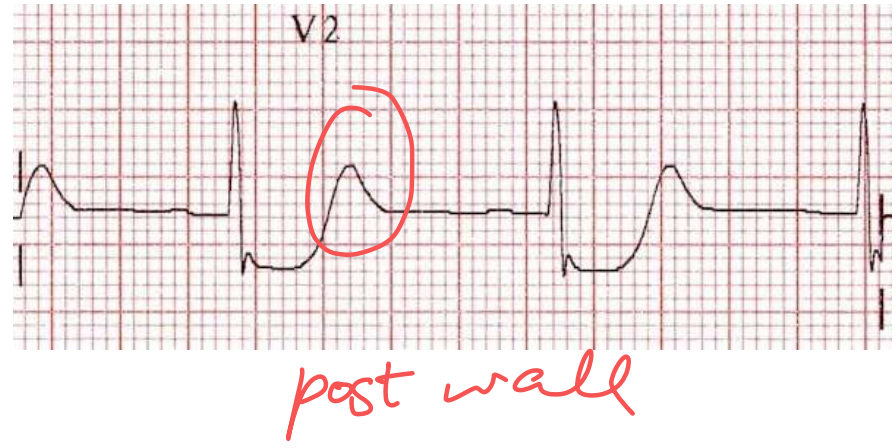
47. A 55-year-old man presented with chest pain and shortness of breath. An ECG was taken in the emergency and was shown. What is the likely diagnosis?



ST ↓

- A. NSTEMI
- B. Unstable Angina
- ~~C. Posterior MI~~
- D. Acute Myocarditis

- The ECG shows:
 - ST segment depression** in leads V1 to V3
 - Tall, broad R waves** in V1–V3
 - Upright T waves** in these leads



NSTEMI

48. Which of the following conditions is associated with box car nuclei seen on histopathological examination of the myocytes?

- A. Restrictive cardiomyopathy
- B. Hypertrophic cardiomyopathy
- C. Hypertensive cardiomyopathy**
- D. Subendocardial ischemia



49. A 52-year-old male presents with headache, confusion, visual disturbances, nausea, vomiting and seizures. On examination blood pressure is 220/110 mm Hg. Which of the following treatments is most appropriate for managing his condition?

- A. Oral Nifedipine
- B. Oral Nicardipine capsules
- C. IV Nitroglycerine
- D. IV Labetalol

Hytn emergency

DDC

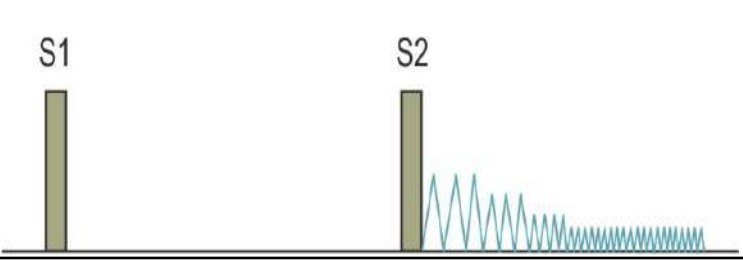
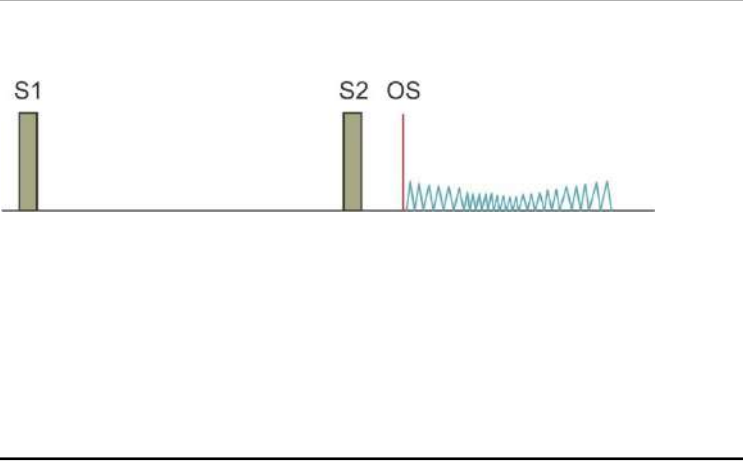
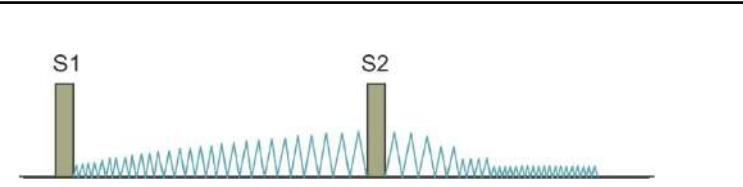
*♥ HF /
p. edema*

50. A 60-year-old man presents with complaints of breathlessness on walking a few metres. He adds that he has an uncomfortable awareness of his heartbeat, especially on lying down. Examination reveals widened pulse pressure and pulsating uvula. Which of the following would be the most likely auscultatory finding in this condition?

- A. Austin Flint murmur
- B. Carey Coomb murmur
- C. Gallavardin phenomenon
- D. Graham Steel murmur

AR

Murmurs

Diastolic	
	<p>Early diastolic, decrescendo, high-pitched “blowing” murmur</p>
	<p>Follows opening snap (OS) , Loud S1 Delayed rumbling mid-to-late murmur with presystolic accentuation Lost in: (↓ interval between S2 and OS correlates with ↑ severity)</p>
Continuous	
	<p>Continuous machine like murmur, best heard at left infraclavicular area</p>

Early diastolic murmur in PAH

Graham Steell

Mid-diastolic, rumbling, low-pitched in AR

↓ Austin Flint

→ Carey Coomb

Mid-diastolic, short, ARF

- Gallavardin phenomenon: Murmur of aortic stenosis radiating to the apex, sometimes mistaken for mitral regurgitation.

51. A 13-year-old boy collapsed while playing football. ECG showed V5, V6 inversion and prominent inverted T-waves. 2D echocardiography showed the septal anterior motion of mitral valve leaflet. Which of the following features will be seen on clinical examination and which of the following are true regarding the management?

Management

1. Beta-blockers are given ✓
2. Beta-blockers are contraindicated
3. ICD is indicated ✓
4. ICD is contraindicated

Clinical findings

- ~~a. Pulsus bisferiens~~
- ~~b. Pulsus alternans~~
- ~~c. Ejection systolic murmur~~
- ~~d. Murmur increases on standing~~
- e. Murmur decreases on standing

M HOCM / AS + AOR
LVA

preload ↓

- ~~A. 1 & 3; a, c, d~~
- B. 2 & 4; b, c, e
- C. 1 & 3; a, e
- D. 2 & 4; b, e

HOCM

Contractility
worsen

52. A 49-year-old woman with poorly controlled diabetes presents with fever, dysuria, and right flank pain. BP is 80/44 mm Hg, pulse 134/min. Serum glucose is 72 mg/dL, urine ketones positive. Neck veins are flat. Which of the following hemodynamic parameters are most likely to be present in this patient?

A. \uparrow PCWP, \downarrow CI (cardiac index), \uparrow SVR, \downarrow SvO₂

B. \uparrow PCWP, \uparrow CI, \downarrow SVR, \uparrow SvO₂

C. \downarrow PCWP, \downarrow CI, \downarrow SVR, \downarrow SvO₂

~~D. \downarrow PCWP, \uparrow CI, \downarrow SVR, \uparrow SvO₂~~

PN
DM
urinary sepsis

septic shock

vasodilation

CO \uparrow

mVO₂ \uparrow

53. Which of the following statements are true of the baroreceptor reflex pathway?

1. Rostral ventrolateral medulla (RVLM) is inhibited by CVLM. (T)
2. Caudal ventrolateral medulla (CVLM) releases GABA. (T)
3. Nucleus tractus solitarius (NTS) releases ~~GABA~~.
4. Stretch receptors are stimulated by increased blood pressure (T)

A. 1, 2, 3, 4

~~B. 1, 2, 4~~

C. 3, 4

D. 1, 2

88. Lipid profile of a patient who suffered from acute coronary syndrome is given. He has LDL 127 g/dl, HDL 32 mg/dl, and Triglycerides are 278 mg/dl. What drug can be used to treat this condition?

Pyq

A. Fenofibrate 160 mg

B. Rosuvastatin + Fenofibrate

C. Rosuvastatin 10 mg ~~10 mg~~ 20-40mg

~~D. Atorvastatin 80 mg~~

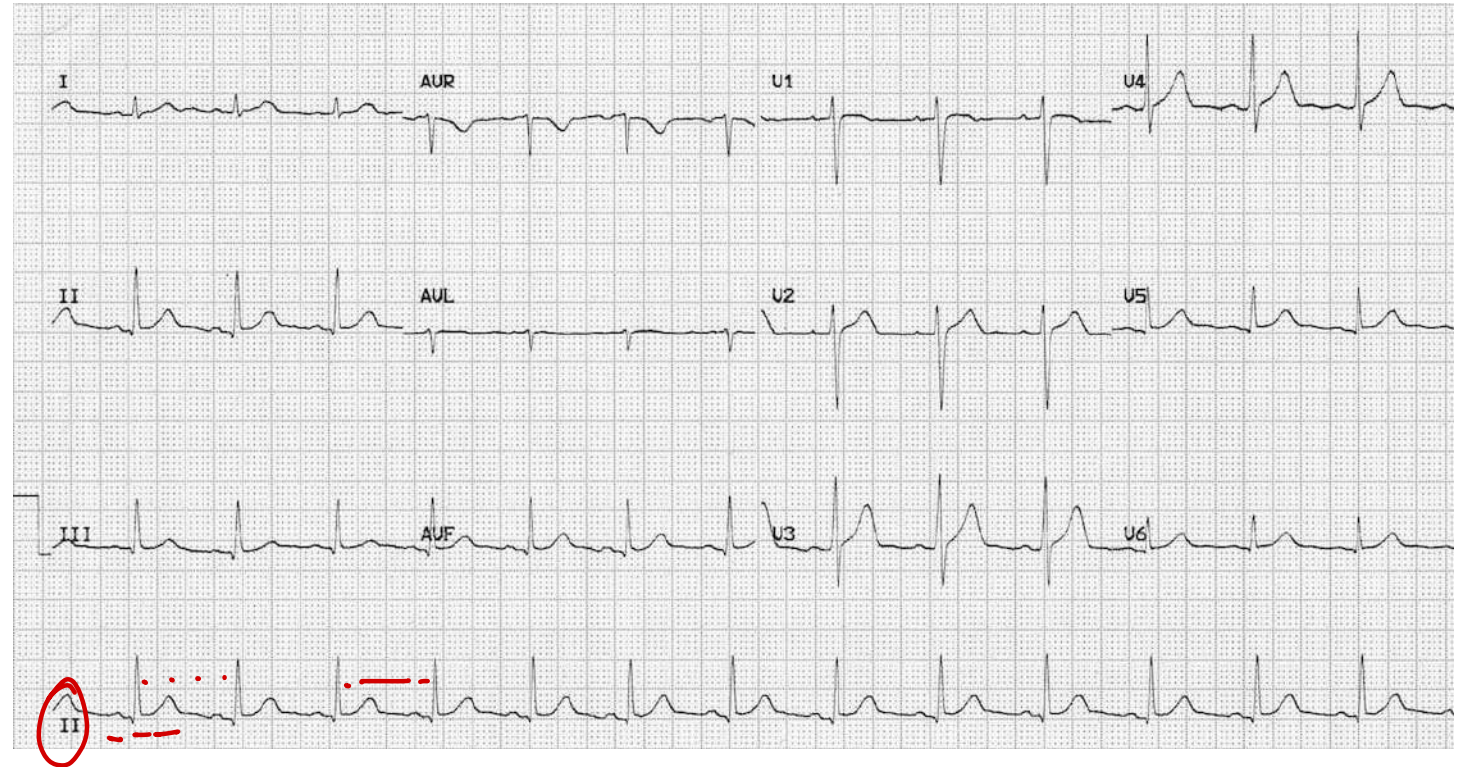
High intensity statins indications:

- Clinical ASCVD/Acute Coronary Syndrome
- Prophylaxis for patients with history of Angina/myocardial infarction/stroke
- LDL > 190 mg/dl
- Hypertriglyceridemia with ASCVD risk

Intensity	Atrovastatin	Rosuvastatin	Simvastatin	Pravastatin	Lovastatin
High (reduce LDL > 50 %)	40-80 mg	20-40 mg	-	-	-
Moderate (reduce LDL by 30-49 %)	10-20 mg	5-10 mg	20-40 mg	40-80 g	40 mg
Low (Reduce LDL by < 30 %)	-	-	10 mg	10-20 mg	20 mg

89. A 52-year-old man presents to the emergency with burning chest pain. Examine the ECG shown below. What does it indicate?

- A. Sinus tachycardia
- B. Irregular rhythm
- ~~C. Normal sinus rhythm~~
- D. Sinus bradycardia



91. Which of the following methods can be used to calculate cardiac output?

1. Thermodilution ✓

2. ECHO ✓

MRI ✓

3. Fick's principle ✓

4. Plethysmography → RV

A. 1,2,3,4

B. 1,2,3

C. 2,4

D. 1,3

92. How should adenosine be administered to a patient with supraventricular tachycardia (SVT) for pharmacological cardioversion?

A. 6 mg IV bolus over 2–3 ~~minutes~~ followed by saline flush

B. 6 mg IV bolus over 2–3 seconds followed by a rapid flush with 20 mL normal saline

C. 6 mg slow IV infusion over 20–30 minutes

D. 6 mg slow infusion over 20 minutes, followed by 12 mg over 40 minutes

6 mg → 12 → 12

93. A patient with chest pain and palpitations has BP 130/90 mmHg and pulse 101/min. Echocardiography shows right atrial collapse during diastole. What is the most appropriate management?

A. Pericardiocentesis

B. NSAIDs

C. Steroids

D. Chest tube insertion or thoracotomy

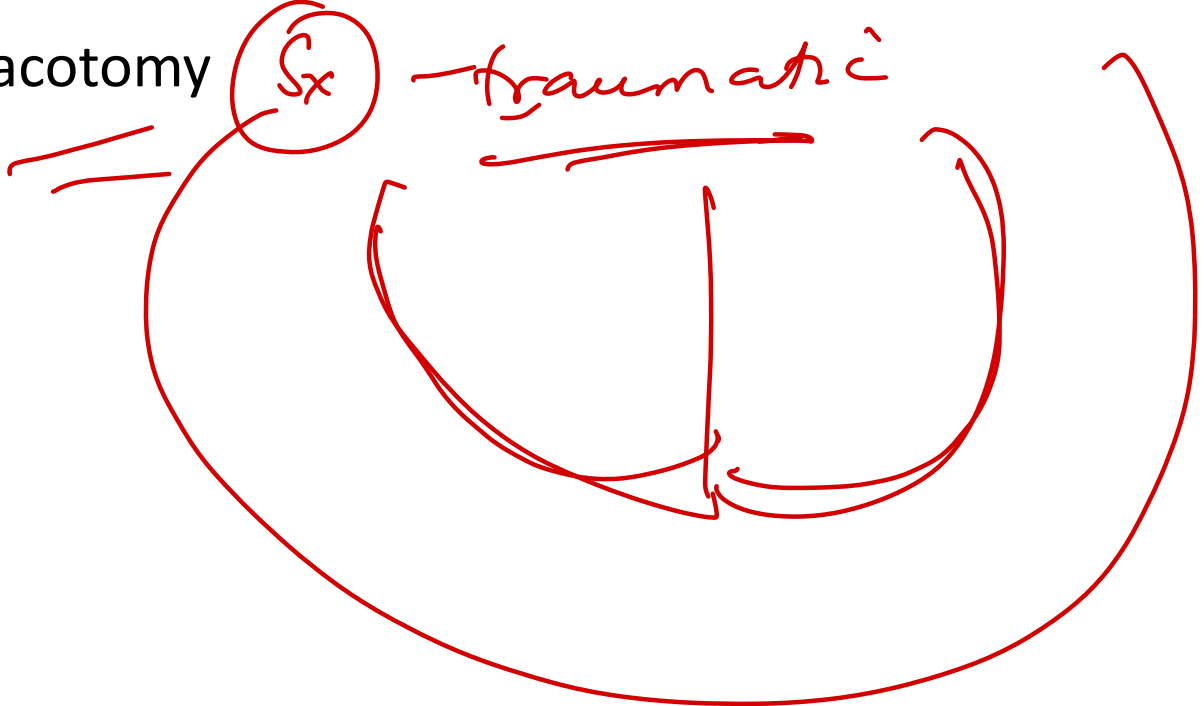
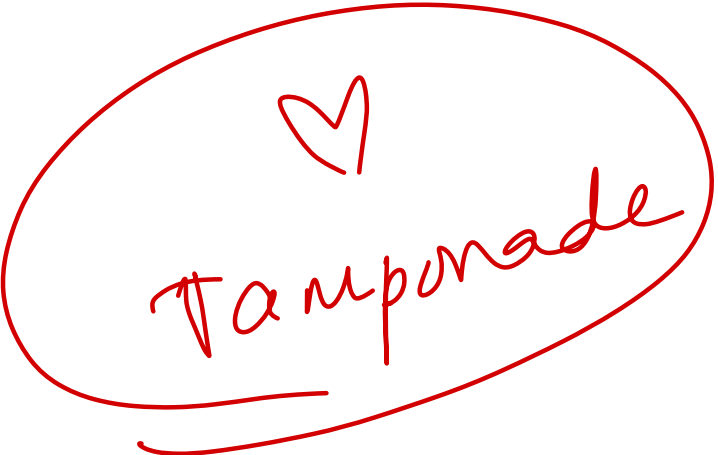Pyo


X

pericarditis

Sx

traumatic



95. A 54-year-old male with a long history of alcohol use disorder presents to the primary care physician with shortness of breath and increasing fatigue over the past year. The patient has also experienced decreased exercise tolerance and mild lower extremity swelling. He denies chest pain, nausea, vomiting, abdominal pain, or changes in his bowel movements. Vital signs include a temperature of 37.1°C (98.8 °F), blood pressure of 118/78 mmHg, heart rate of 80 beats/min, and respiratory rate of 16 breaths/min. Physical exam reveals diffuse bibasilar crackles, abdominal distension, and 2+ pitting lower extremity edema. Doppler echocardiography shows reduced left and right ventricular wall motion with an ejection fraction of 33%. The patient is counseled on the importance of reducing his alcohol consumption. The physician also explains that he will start the patient on a new medication to reduce harmful cardiac remodeling due to the actions of an endogenous vasoconstricting peptide hormone. The next day, the patient calls complaining of lightheadedness and dizziness. His last at-home blood pressure reading was 95/60 mmHg. Which of the following medications was this patient most likely prescribed? 

A. ~~Atorvastatin~~

B. Spironolactone *MRA*

C. ~~Budesonide~~ *steroid*

~~D. Enalapril~~ *ACE ⊖*

Angiotensin
CHF

96. A 66-year-old male with a past medical history of hypertension and a 40 pack-year cigarette smoking history comes to the cardiologist with intermittent chest pain. He previously had chest pain only when walking his dog, which subsided with rest; however, he now has pain while watching TV or reading the newspaper. The patient denies a correlation between his symptoms and eating. His family history includes coronary artery disease in his father at age 55. Temperature is 36.9°C (98.4°F), blood pressure is 138/82 mm Hg, pulse is 88 min, and respirations are 16/min. The patient is in no acute distress. Cardiopulmonary auscultation reveals a regular S1 and S2 with no rubs, murmurs, or gallops and clear breath sounds throughout. Extremities are warm and well-perfused. ECG shows normal sinus rhythm without ST-segment elevations, Q waves, or T wave inversions. Troponin levels are < 0.01 ng/mL. The patient undergoes evaluation by coronary angiography, revealing a partial occlusion of the posterior descending artery and codominant circulation. Which of the following vessels most likely supply the posterior descending artery in this patient?

- A. Left coronary and right marginal arteries
- B. Left anterior descending and right coronary arteries
- C. Right coronary and left circumflex arteries
- D. Right and left coronary arteries

RCA

LCx

99. A 64-year-old female with a past medical history of a right below-the-knee amputation with a transtibial prosthesis presents to the cardiologist for a cardiac stress test. She reports exertional chest pain and shortness of breath when walking to pick up her mail each afternoon. The pain is never present at rest. Due to her history of amputation and prosthesis, she is not a candidate for exercise stress testing. Therefore, the physician administers a medication that will induce a similar response. Following administration, the patient reports a crushing chest pain similar to her reported symptoms. Which of the following best describes the mechanism of action of the medication administered?

- A. agonist causing an increase in cGMP
- B. Gi antagonist causing an increase in cAMP
- C. Gq agonist causing an increase in IP3
- D. Gs agonist causing activation of adenylate cyclase

Dobutamine

Stress

ELHO

$\beta(+)$

100. A 10-year-old female who recently moved to the area presents to the cardiologist to establish care. The patient's father reports his daughter has always been "on the shorter side" and had a genetic abnormality noted on karyotype analysis during prenatal screening, but he does not recall the details. On physical exam, the patient appears short with a broadened chest. Excess skin folds extend along the lateral aspect of her neck bilaterally, and her toenails appear dysplastic. A computed tomography angiogram (CTA) completed at the patient's previous healthcare facility shows a narrowing of the aorta at the isthmus. Which of the following findings will most likely be appreciated on this patient's physical exam?

- A. Abdominal bruit
- B. Biphasic pulses
- C. Bounding femoral pulses
- D. Brachial-femoral delay

Turner sx

CoA

INTEGRATED HEMATOLOGY



54. All of the following are true regarding the management of Immune Thrombocytopenic Purpura (ITP) except:

- A. Splenectomy is considered after glucocorticoid therapy failure ✓✓
- B. IVIg is a treatment option in life-threatening bleeding ✓✓
- ~~C. Romiplostim and eltrombopag are avoided post-splenectomy~~
- D. Rh(D) immune globulin is used in Rh-positive patients

anti-GpIIb/IIIa

1st - steroids

↓
IVIg / anti-D

↓
Rituximab

↳ Splenectomy.

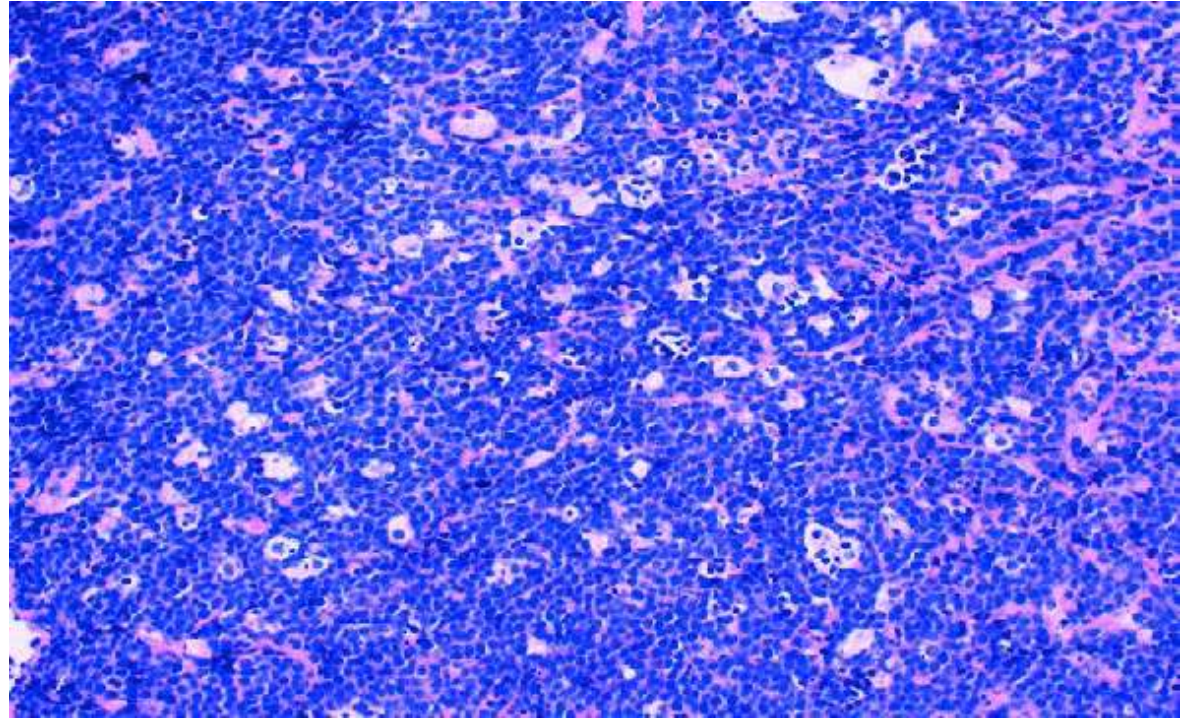
Fostamatinib

✓✓
TPO (+)
oprelvekin

55. A 18-year-old boy is brought to the hospital with a 2-week history of rapidly increasing swelling on his jaw, recurrent nosebleeds, weight loss, and ~~generalized fatigue~~. Physical examination of the neck reveals firm, nontender lymph nodes. The mass is biopsied, the image is shown below. Which of the following best describes the genomic structure of the most likely causative virus?

- A. Double-stranded circular DNA → Hep B
- ~~B. Double-stranded linear DNA~~
- ~~C. Double-stranded linear RNA~~
- ~~D. Single-stranded linear RNA~~


Burkitt



EBV

56. A 65-year-old male presents with sepsis and purpura fulminans. Thromboelastography (TEG) is ordered to assess the patient's clotting profile. Which of the following TEG tracings is most consistent with the patient's presentation?

- A. Reduced R-time, increased angle, increased MA, increased LY30
- B. Prolonged R-time, decreased angle, decreased MA, decreased LY30
- C. Prolonged R-time, decreased angle, decreased MA, increased LY30
- D. Reduced R-time, decreased angle, increased MA, decreased LY30



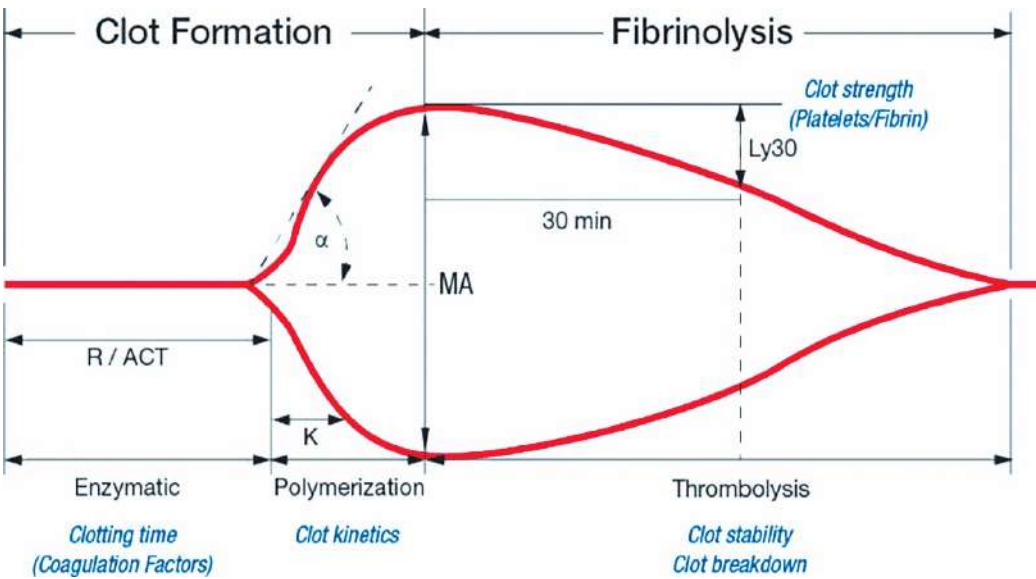
DIC

Coagn ↓

plt ↓

Abnormalities
↑↑

TEG



R K α MA Ly 30

✓ ✓

TEG	Normal	Abnormality / Cause	Treatment
Reaction Time (R value)	5–10 min	↑ R value: ↓ factors	FFP, protamine
K value	1–5 min	↑ K: ↓ fibrinogen	Cryoprecipitate, fibrinogen
α-angle	45–75°	↓ α-angle: ↓ fibrinogen	Cryoprecipitate, fibrinogen
Maximum Amplitude (MA)	50–75 mm	↓ MA / MCF: ↓ platelet count and/or function	Platelets, DDAVP
LY-30	0–10%	↑ LY-30 / CL: clot breakdown	TXA, Amicar

57. A 41-year-old woman with a long history of menorrhagia comes to the physician due to a low hemoglobin level identified on routine laboratory evaluation. She is diagnosed with iron deficiency anemia and started on oral ferrous sulfate. Which of the following cells secrete a substance that controls iron storage and release by other cells involved in iron homeostasis?

- A. Biliary lining cells
- B. Bone marrow macrophages
- C. Enterocytes
- D. Hepatic parenchymal cells

Hepcidin

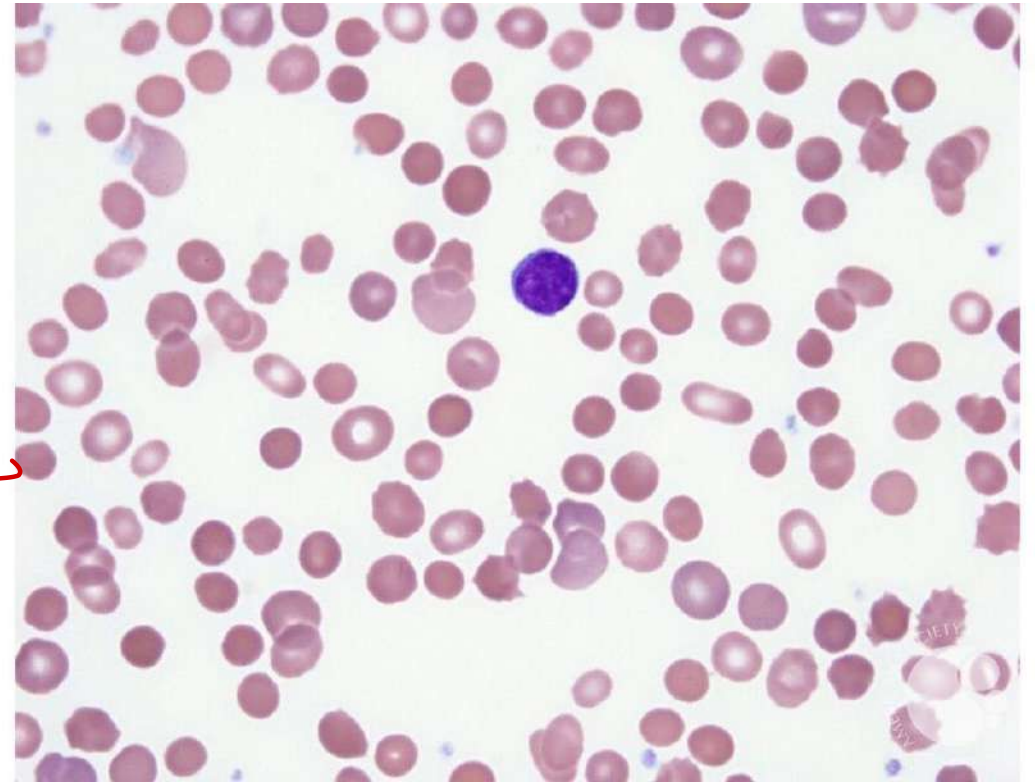
58. A 3-year-old boy is brought to the physician with jaundice and pallor. He was adopted and his family history is unknown. Laboratory studies show anemia, reticulocytosis, and increased indirect bilirubin. A peripheral blood smear is shown. This patient is most likely to have which of the following additional findings?

- A. ~~Decreased~~ lactate dehydrogenase
- B. ~~Increased~~ haptoglobin
- C. Increased MCHC
- D. Positive Coombs test

adult
AIHA
adult

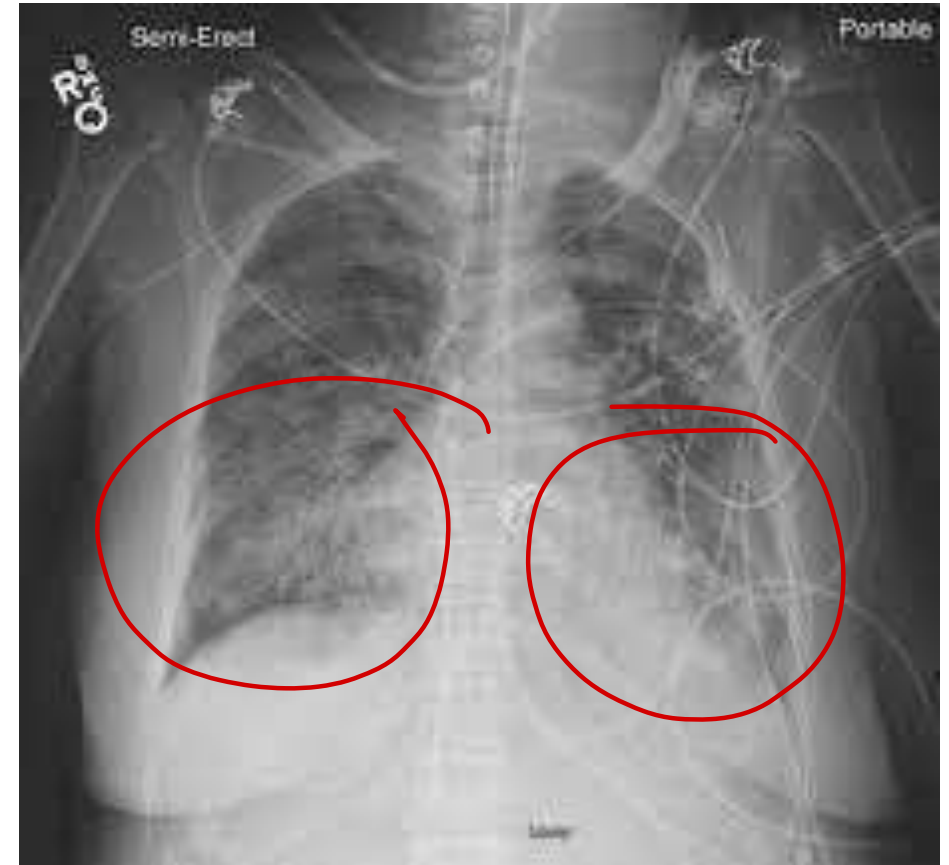
HS

VOL ↓



59. A 66-year-old woman with warfarin induced bleeding receives IV vitamin K, 4 U PRBCs and 4U FFP. 4h later, she begins to complain of shortness of breath. Vitals T - 39°C, RR 35/min, SpO2 84% on RA, and BP 88/52 mm Hg. Exam revealed B/L crackles and the patient was intubated for respiratory failure. CXR is as shown in the picture. What is the likely diagnosis?

- A. Anaphylaxis
- B. TACO
- C. TRALI**
- D. Aspiration



60. 7-year-old boy is brought to the clinic for a routine health maintenance examination. He underwent a splenectomy a year ago for persistent anemia and jaundice. He has received the pneumococcal and meningococcal vaccinations and takes penicillin prophylaxis. Physical examination reveals a well-appearing child. The sclerae are anicteric. The abdomen is soft and nontender; no masses are palpable. Several well-healed laparoscopy scars are noted. Complete blood count is as follows:

Hemoglobin: 11.3 g/dL

Reticulocytes: 3%

Platelets: 160,000/mm³

Leukocytes: 8,200/mm³

Peripheral blood smear with Wright stain is shown.

This patient's findings are most likely related to which of the following?

nuclear remnants

- A. Chronic Hb oxidation and precipitation
- B. Inability to produce beta globin chains
- C. Mechanical red-blood-cell membrane damage
- D. Persistence of red blood cell precursor nuclei

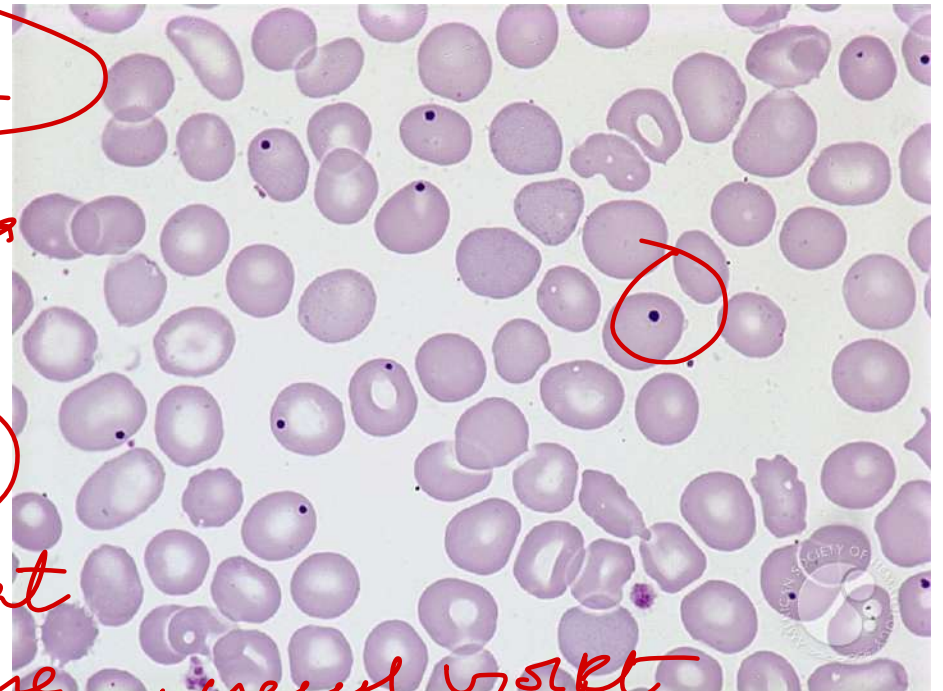Howell Jolly

asplenia

Heinz

supranat

new methyl blue, cresyl violet



61. A 5-year-old girl is brought to the OPD by her mother due to leg pain. One week ago mother saw the patient fall onto the living room floor after climbing on a couch. Since the incident, she has had persistent leg pain that appears to be worse at night, and for the last 2 days she has been refusing to walk asking her mother to carry her. The patient has no chronic medical conditions but has had a mild, non-productive cough for the past month. Temperature is 38.3 C (100.9 F); all other vital signs are normal. Examination shows a pale child. The abdomen is nontender and moderate hepatosplenomegaly is noted. Palpation of the bilateral anterior proximal tibias elicits pain. There are a few scattered bruises across the chest and back. Complete blood count results are as follows:

Hemoglobin-8g/dL

Platelets-30,000/mm³

Leukocytes-3,000/mm³

Which of the following is the most likely cause of this patient's symptoms?

A. Acute lymphoblastic leukemia

B. Aplastic anemia X HSM


C. Immune thrombocytopenia

D. Infectious mononucleosis

Pan cytopenia

✓ HSM

Leukemia

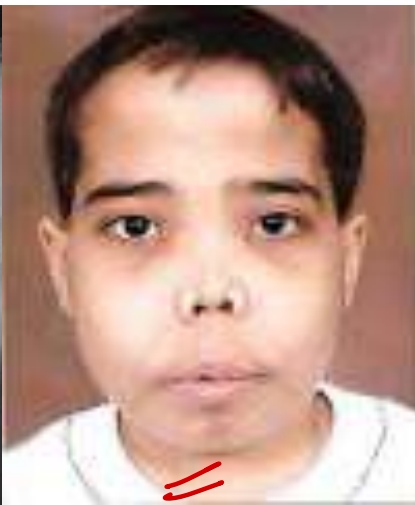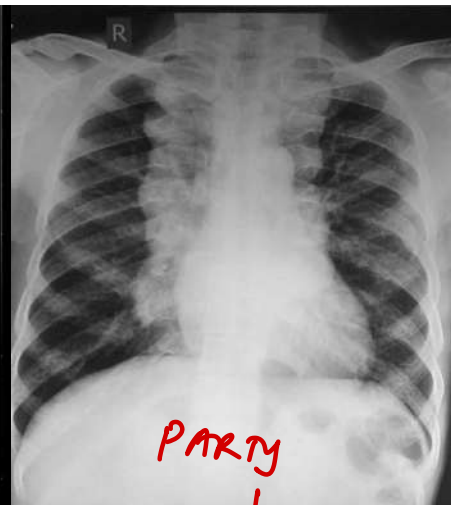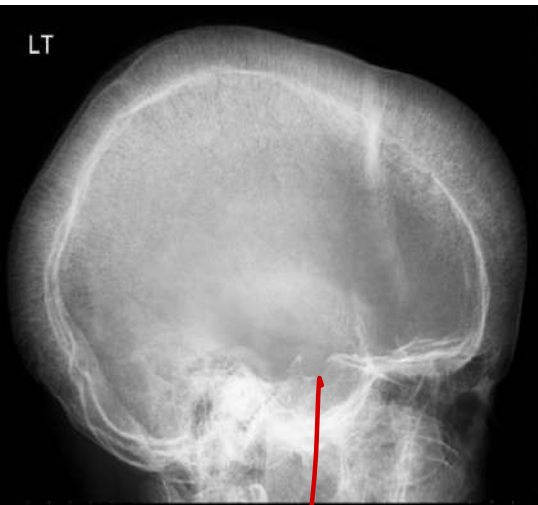


62. A ~~67~~4-month-old boy is brought to the clinic by his mother due to concerns of appearing pale. Over the past few days, he has been sleeping more than usual and is less interactive. He continues to have good urine output. The patient was born at 40 weeks gestation and had a normal nursery course. However, the patient's newborn screen revealed an extra band representing gamma tetramers on haemoglobin electrophoresis. The patient takes a vitamin D supplement daily. Vital signs are normal. He appears tired and has mild scleral icterus. The remainder of the examination shows no abnormalities. What is the likely diagnosis?

- A. Beta thalassemia
- B. HbH disease
- C. Hb Barts
- D. Sickle cell anemia

$\gamma 4$

$B_4 \rightarrow HbH$



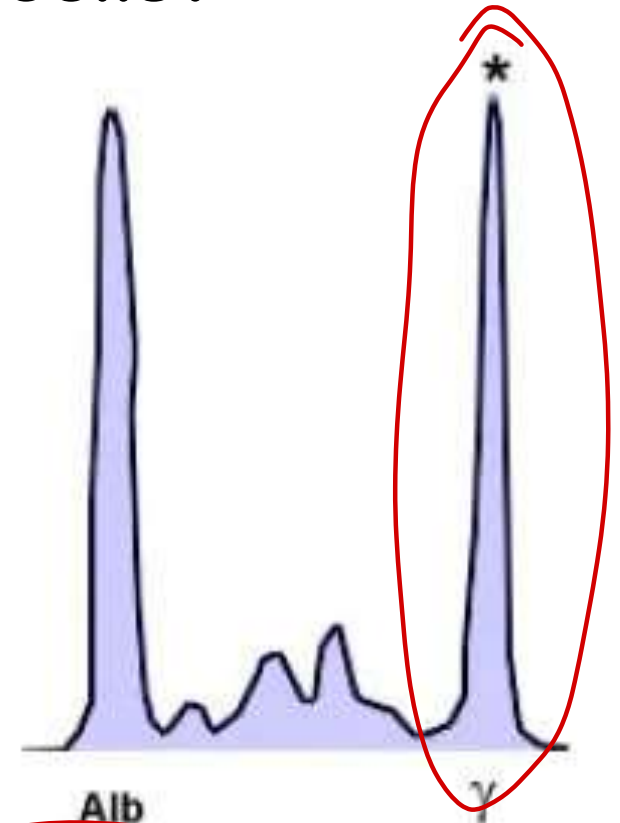
Chr 16 deletion: α Thal — — — —
 1- -+ / ++ : minima - silent carrier
 2- -+ / -+ / -- / ++ minor / trait - mild IDA
 3- -- / -+ : β^+ → severe - HbH
 4- -- / -- : Hydrops → Bart disease ($\gamma 4$)
 Chr 11 Splicing mutation: β Thal — —
 1- - / + : Minor
 2- - / - : Mjr

↓
 Hair on end EM 4

HbF $\alpha 2$ ($\gamma 2$)
 HbA $\alpha 2 \beta 2$

63. A 67-year-old man is evaluated for persistent lower back pain and fatigue. Laboratory testing shows anemia and renal dysfunction. Serum electrophoresis of the serum proteins is shown below. A medication that blocks cellular proteasome action is administered. This treatment is most likely to cause which of the following effects on the abnormal cells?

- A. Augmented cytotoxic T-cell response
- B. Decreased DNA methylation
- C. Impaired RNA splicing
- D. Increased apoptosis



Burkett's



apoptosis

64. A 20-year-old woman comes to the emergency department due to bloody stools. For the past month, she has also had decreased energy. Skin examination shows pallor and scattered bruises in various stages of healing throughout the trunk. The abdomen is soft without organomegaly. Complete blood count results are as follows:

Hemoglobin: 7.2 g/dL ✓

Mean corpuscular volume 90 μm^3

Platelets: 10,000/ mm^2 ✓

Leukocytes: 1050/ mm^3 ✓

Neutrophils: 5%

Lymphocytes: 95%

Pancytopenia
MDS
AA

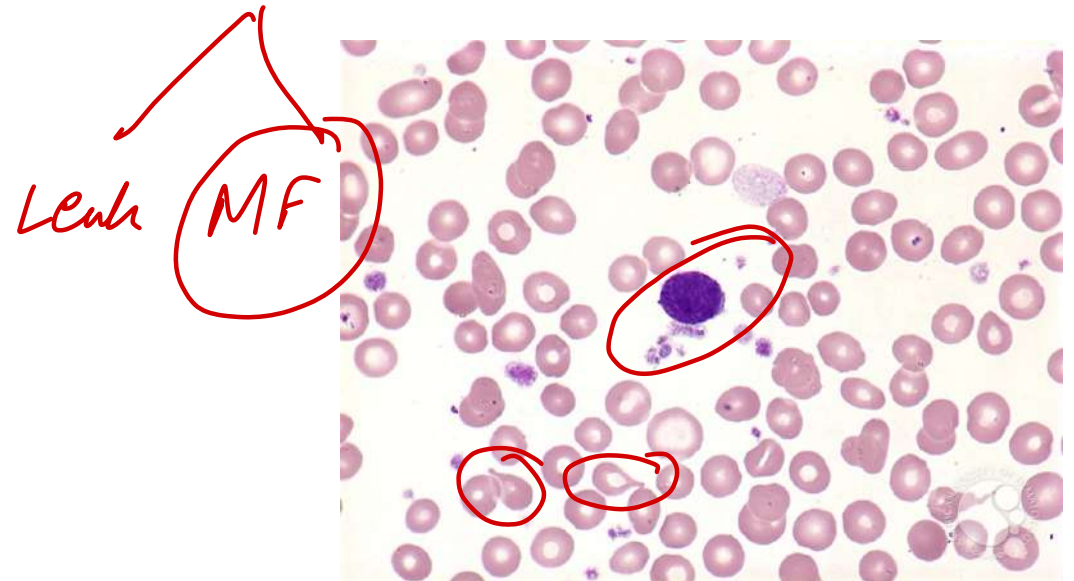
Which of the following is the most likely cause of this patient's condition?

- A. Autoimmune-induced loss of self-renewing hematopoietic stem cells AA
- B. Bone marrow replacement by constitutively active tyrosine kinase-stimulated cells CM2
- C. Splenic hyperactivity with cell trapping by the reticuloendothelial system
- D. Ineffective hematopoiesis secondary to micronutrient deficiency *Hypersplenism*

B12 def.

65. A 68-year-old man comes to the OPD with a few months of severe fatigue and a 6.8-kg unintentional loss in weight. Abdominal examination shows mild hepatomegaly and a markedly enlarged spleen. Stool guaiac testing is negative. Laboratory results show pancytopenia, and peripheral blood smear is shown below. Bone marrow aspiration is attempted but yields no marrow, and a bone marrow biopsy is subsequently performed. Which of the following findings is most likely to be observed in this patient's bone marrow?

- A. Diffusely fibrotic marrow with clusters of megakaryocytes
- B. Increased staining for storage iron in marrow macrophages *Sideroblasts*
- C. Marrow replaced by dysplastic cells of all 3 lineages *MDS*
- D. Severely hypocellular marrow replaced by adipose cells *AA*



66. 35-year-old woman comes to the physician complaining of weakness, fatigue, and pallor. Physical examination is unremarkable except for conjunctival pallor. Laboratory results are as follows:

Haemoglobin: 7.2 g/dL ✓

Mean corpuscular volume: 90 fL

Reticulocytes: 0.1% ✓

Platelets: 280,000 /uL ✓

Leukocyte count: 6,700 cells/uL ✓

Iron studies and serum B12 and folic acid levels are within normal limits. Bone marrow biopsy shows absence of erythroid precursors but preserved myeloid and megakaryocytic elements. Further workup would most likely show which of the following?

- A. Hepatocellular carcinoma
- B. Renal cell carcinoma
- C. Thymic tumor
- D. Cerebellar hemangioblastoma

PRCA

MG

Good's → ↓ gamma glob

AA

1.7.

67. Supravital stain of a peripheral smear of a patient is shown. What is the likely inheritance pattern of this condition?


- A. Autosomal dominant inheritance
- B. Autosomal recessive inheritance
- C. X-linked dominant inheritance
- D. X-linked recessive inheritance



68. Part 1 of 2

A 54-year-old previously healthy man comes to the OPD due to several weeks of leg swelling. He has had no fever, chest pain, or dyspnea. The patient has a 40-pack-year smoking history. The abdomen is soft and nondistended. A mobile left flank mass can be palpated. There are several vertically oriented tortuous veins on the lower abdominal wall. Which of the following structures is most likely obstructed in this patient?

- A. Femoral veins
- B. Iliac veins
- C. Inferior vena cava
- D. Portal vein



69. Part 2 of 2

Further evaluation of the patient reveals microscopic hematuria.

Laboratory results are as follows:

Leukocytes: 9,000/mm³

Hemoglobin: 19.2 g/dL

Platelets: 230,000/mm³

RCC

Which of the following is the most likely cause of this patient's hematologic findings?

A. Arteriovenous malformation

B. Excess erythropoietin production

C. Extramedullary hematopoiesis

D. Myeloproliferative disorder

HCC

Hemangioblastoma

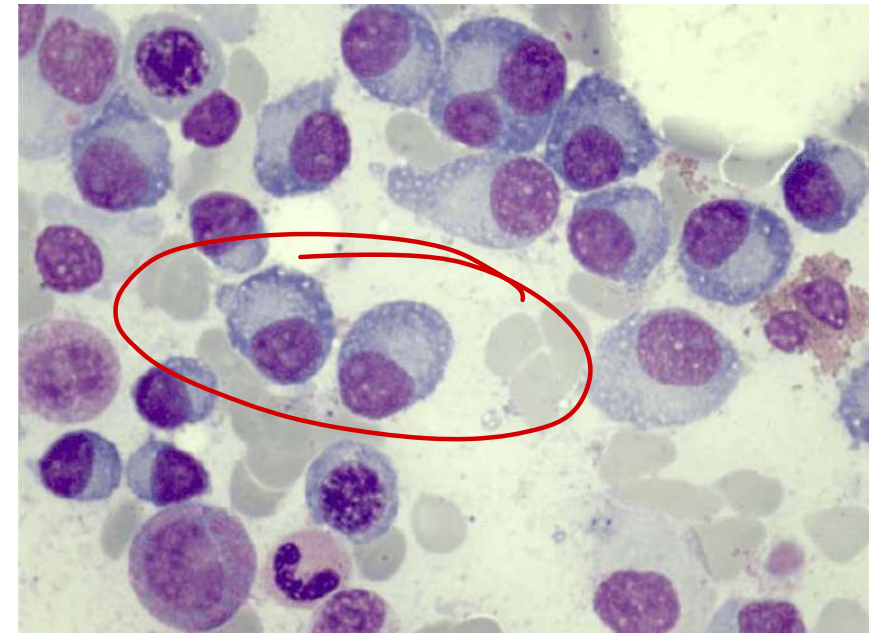
70. A 59-year-old man comes to the OPD due to 3 months of progressive fatigue and back pain. The back pain occurs mainly with movement or positional changes. Physical examination reveals midline tenderness over the middle and lower back. Laboratory evaluation shows a hemoglobin level of 10.2 g/dL and serum calcium level of 12 mg/dL. A bone marrow aspirate is performed, and the histopathologic findings are shown below. This patient is at greatest risk for developing which of the following conditions?

- A. Amyloidosis
- B. Cardiac tamponade
- C. Hepatic failure
- D. Hyperthyroidism

AL

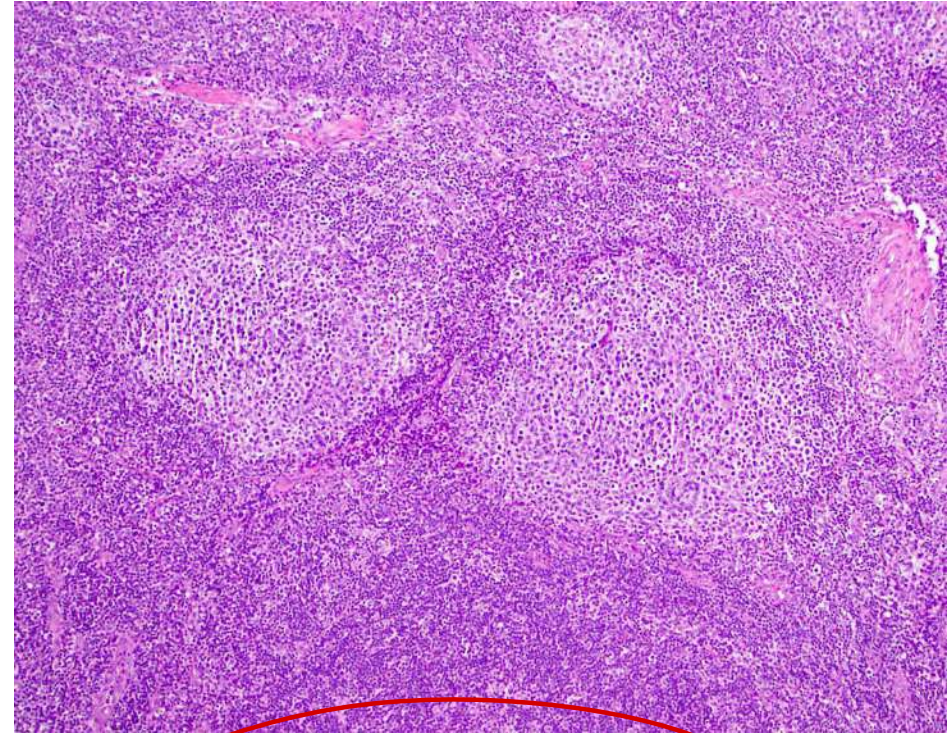
CAMB

MM



71. A 35-year-old man is being evaluated for nontender cervical lymphadenopathy that he first noticed while shaving. A biopsy is performed and is shown below. Cytogenetic analysis would most likely demonstrate which of the following patterns?

- A. BCL-2 overexpression
- B. BCR-ABL rearrangement
- C. C-MYC overexpression
- D. Constitutive tyrosine kinase activation



Follicular

72. A 9-year-old girl is brought to the emergency department due to prolonged epistaxis. The girl says that she picked her nose immediately before the bleeding started. Her parents decided to take her to the emergency department after the epistaxis persisted for 20 minutes despite constant compression. The patient has had frequent nosebleeds that often last >10 minutes. Laboratory tests are ordered, and results are as follows:

Hematocrit: 43%

Bleeding time: prolonged

Partial thromboplastin time (PTT): prolonged

Prothrombin time (PT): normal

Thrombin time (TT): normal

D-dimer: normal

Which of the following is the most likely diagnosis?

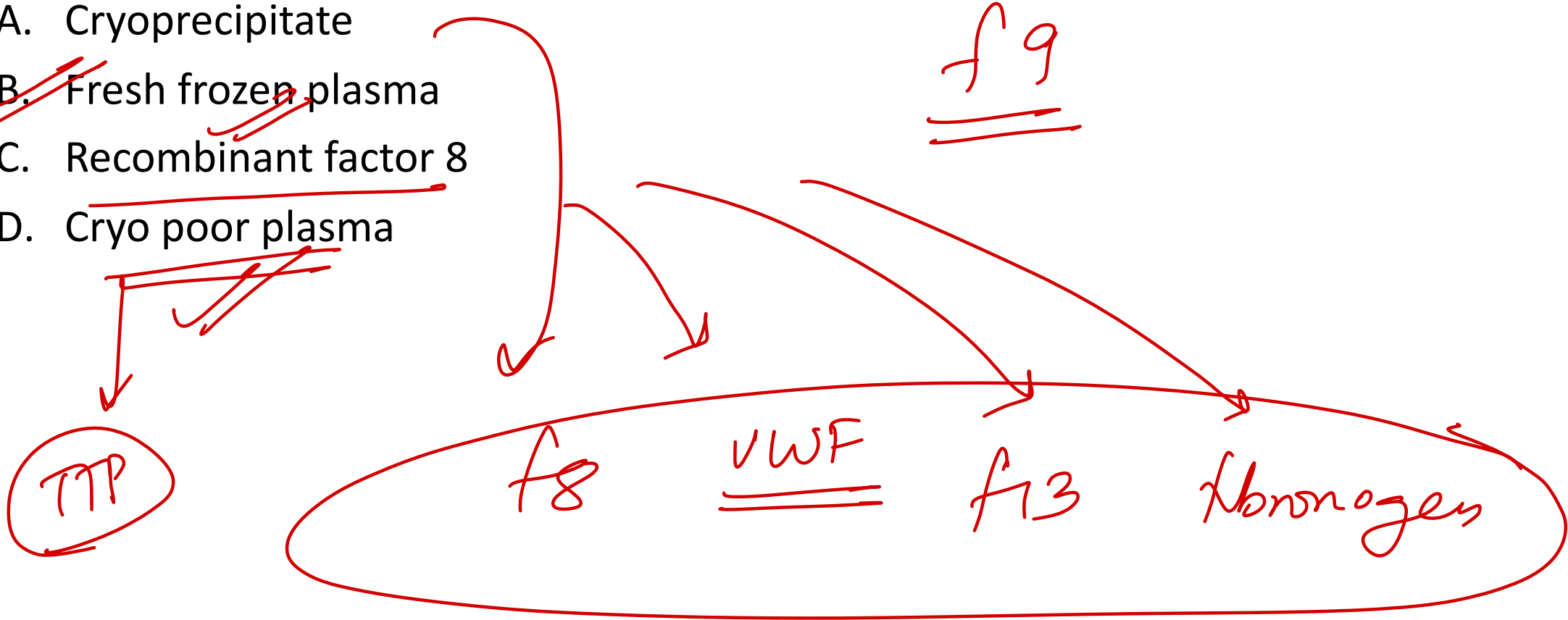
- A. Factor XIII deficiency
- B. Hemophilia A
- C. Vitamin K deficiency
- D. von Willebrand disease**



AD
chr 12

73. Which of the following is useful for a patient having Haemophilia B?

- A. Cryoprecipitate
- ~~B. Fresh frozen plasma~~
- C. Recombinant factor 8
- ~~D. Cryo poor plasma~~



74. A 71-year-old woman comes to the physician because of palpitations and shortness of breath that started 3 days ago. She has hypertension and congestive heart failure. An ECG shows a narrow-complex tachycardia without P waves. The patient is prescribed a prophylactic medication that can be reversed with idarucizumab. The expected beneficial effect of the prescribed drug is most likely due to which of the following effects?

- A. Induction of conformational change in antithrombin III
- B. Direct inhibition of factor Xa
- C. Reduced activation of clotting factors II, VII, IX, and X
- D. Direct inhibition of thrombin

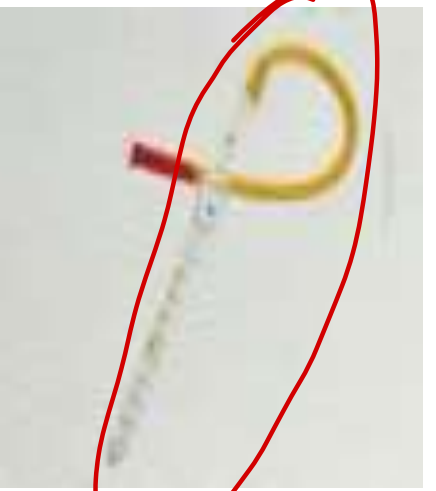75. Which of the following is not useful for hemoglobin estimation by the calorimetric test?

pyq -

- A. RBC pipette *- RBC / PLT*
- B. Sahli graduated hemoglobin tube
- C. Comparator with brown glass standard
- D. Hemoglobin pipette



Sahli's



RBC pipette

N/10 HCC

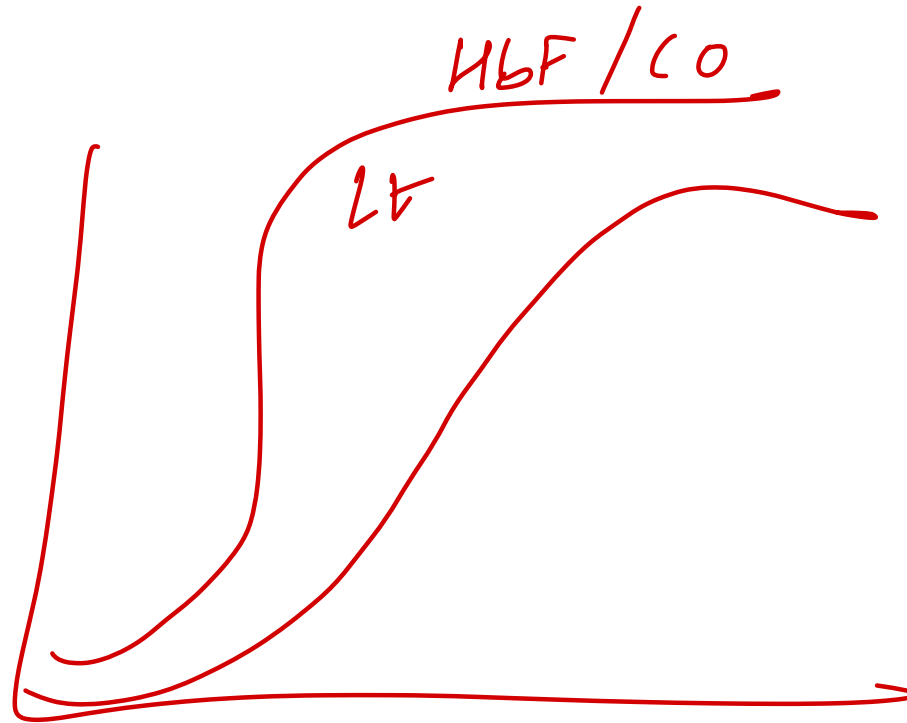
76. An investigator is studying the changes that occur in the oxygen-hemoglobin dissociation curve of different types of hemoglobin under various conditions. The blood obtained from a male infant shows decreased affinity for 2,3-bisphosphoglyceric acid. Which of the following is the most likely composition of the hemoglobin molecule in this sample?

A. $\alpha_2\beta_2$

B. $\alpha_2\gamma_2$

C. β_4

D. $\alpha_2\delta_2$



77. A 25 yr old women G2P1L1 is brought to the emergency at 30 weeks gestation in active labor. The patient had severe anemia during pregnancy and received multiple blood transfusions during past months. An uncomplicated Vaginal delivery is performed and 2.5kg infant is delivered. Post operatively she continues to bleed and receives a transfusion of 1 unit of packed RBC. One hour later, the patient appears to have flank pain and in acute distress. Temperature is 101° F, pulse 115/min and BP is 92/66 mmHg. Foley catheter shows dark brown urine. Further evaluation is most likely to show:

A. Serum antibodies against Class 1 HLA

B. Positive Direct Coomb's

C. B/L pulmonary infiltrates on CXR

D. Low levels of serum IgA

anaphylaxis

TRALI

acute
hemolytic

ABO incompat.

78. Which of the following is correctly matched:

A. FFP: Hemophilia A

B. Saline washed RBC: Increased risk of allergic reaction

C. Cryoprecipitate: Hemophilia B

D. Cryo-poor plasma: TTP

cryo

xxx

79. Splenectomy is contraindicated in which of the following conditions? (FMGE JULY 2024)

A. Splenic rupture ✓

B. Thrombocytopenia ✓

C. Hairy cell leukemia ✓

D. Bone marrow failure

EMH

→

80. A 7-year-old boy is brought to the office by his parents due to fatigue, easy bruising, and frequent nosebleeds for 2 weeks. On physical examination, the child appears pale with scattered petechiae. Laboratory studies show:

Hemoglobin: 8.9 g/dL

Platelet count: 21,000/mm³

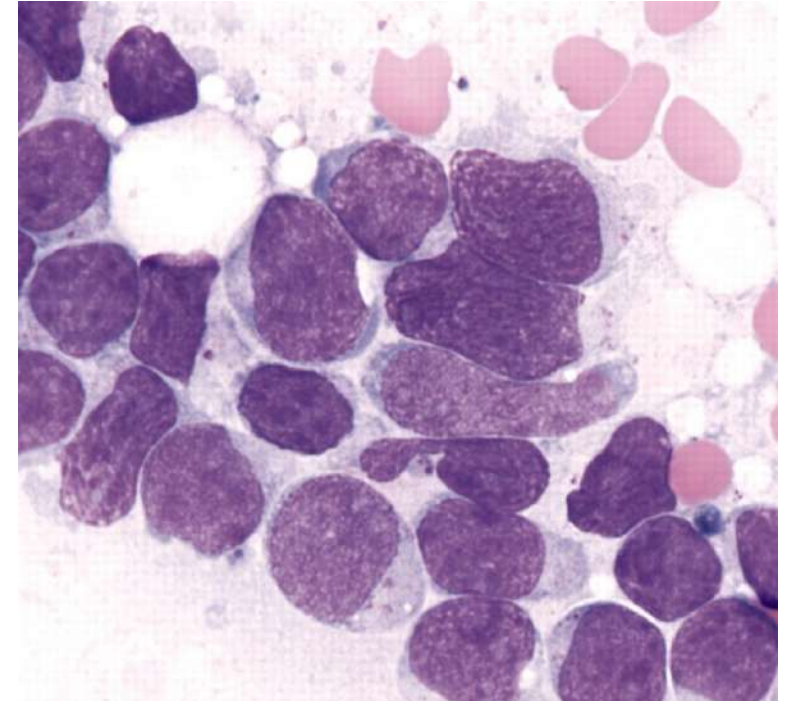
Leukocyte count: 15,500/mm³

A bone marrow aspirate reveals the findings shown in the image below. The cells are positive for terminal deoxynucleotidyl transferase (TdT) and express CD19 and CD10.

Which of the following is the most likely diagnosis?

- A. Precursor B-cell leukemia
- B. Precursor T-cell leukemia
- C. Mature B-cell leukemia
- D. Mature T-cell leukemia

ALL B



A 69-year-old woman comes to the physician for a routine health maintenance examination. She feels well. Physical examination shows nontender cervical and axillary lymphadenopathy. The spleen is palpated 5 cm below the costal margin. Her leukocyte count is 12,000/mm³ and platelet count is 217,000/mm³. Further evaluation is most likely to show which of the following findings?

- A. Ringed sideroblasts *Siderob* ✗
- B. Teardrop cells ✗✗
- C. ~~Smudge cells~~ *CLL*
- D. Rouleaux formation *MM*

82. A 21-year-old man comes to the physician because of a 3-day history of yellowing of his eyes. He has also noticed a decrease in his exercise capacity and gets quickly exhausted after minor physical activity. Examination shows scleral icterus and pale mucous membranes. He has splenomegaly. His hemoglobin concentration is 7.9 mg/dL, leukocyte count 8500/mm³ and platelet count is 1.8 lakhs/mm³. Direct antiglobulin and heterophile antibody tests are positive. Which of the following additional laboratory findings are most likely present in this patient?

- A. Decreased reticulocyte count
- B. Decreased haptoglobin levels
- C. Decreased mean corpuscular volume
- D. Increased ~~direct~~ to total bilirubin ratio

↑

Normocytic

DCT ——— Ery

AIHA - Cold

—————

83. A 66-year-old woman presents to the clinic with 2 months of worsening fatigue and persistent lower back pain that is aggravated by movement. Physical examination shows pallor and tenderness over the lower spine. Radiographic imaging reveals lytic bone lesions.

Laboratory findings include:

Hemoglobin: 8.5 g/dL

Serum creatinine: 2.8 mg/dL

Serum calcium: 11.0 mg/dL

Urine dipstick is negative for protein, but 24-hour urine protein quantification shows elevated protein levels. Urine electrophoresis is most likely to detect which of the following?

Options:

A. Gamma heavy chains

B. Immunoglobulin G *serum*

C. Immunoglobulin M

D. Lambda light chains

MM

Bence Jones

84. Which of the following are reduced in Iron Deficiency Anemia ?

- 1. Ferritin (↓) storage
- 2. TIBC (↑)
- 3. Transferrin saturation (↓)
- 4. RDW (↑)
- 5. Hepcidin (↓)
- 6. Soluble transferrin receptor (↑)

Hepcidin ↓

Tf ↑

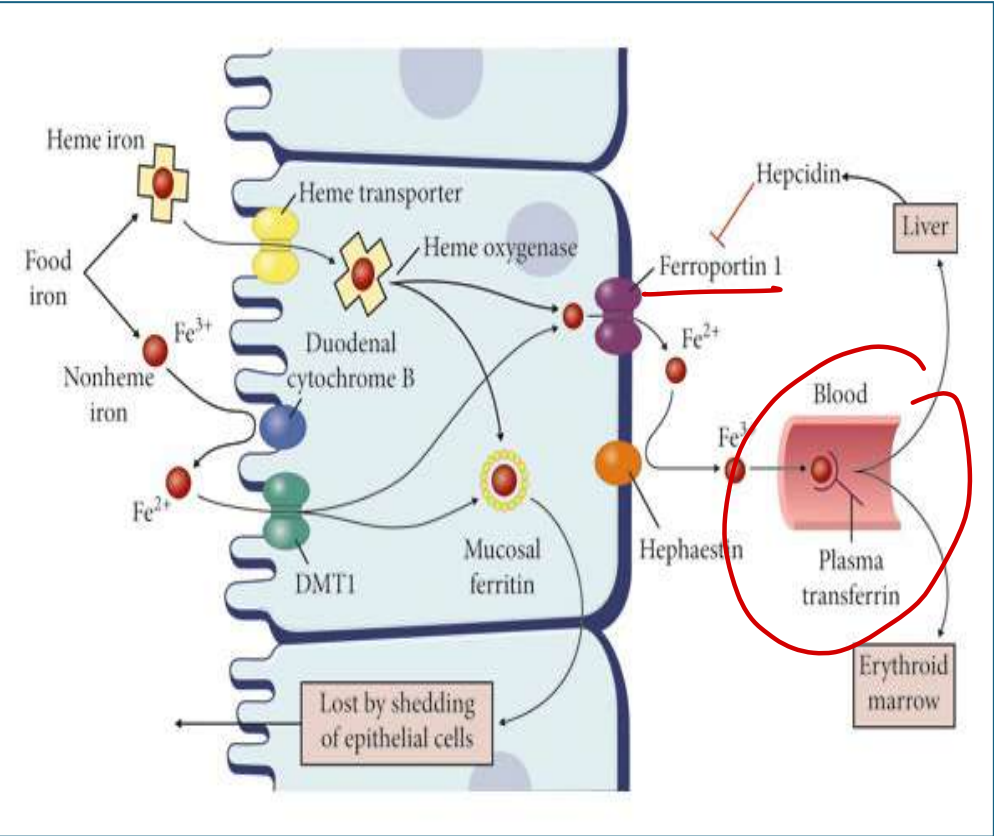
TIBC ↑

tf satn ↓

1, 3, 5

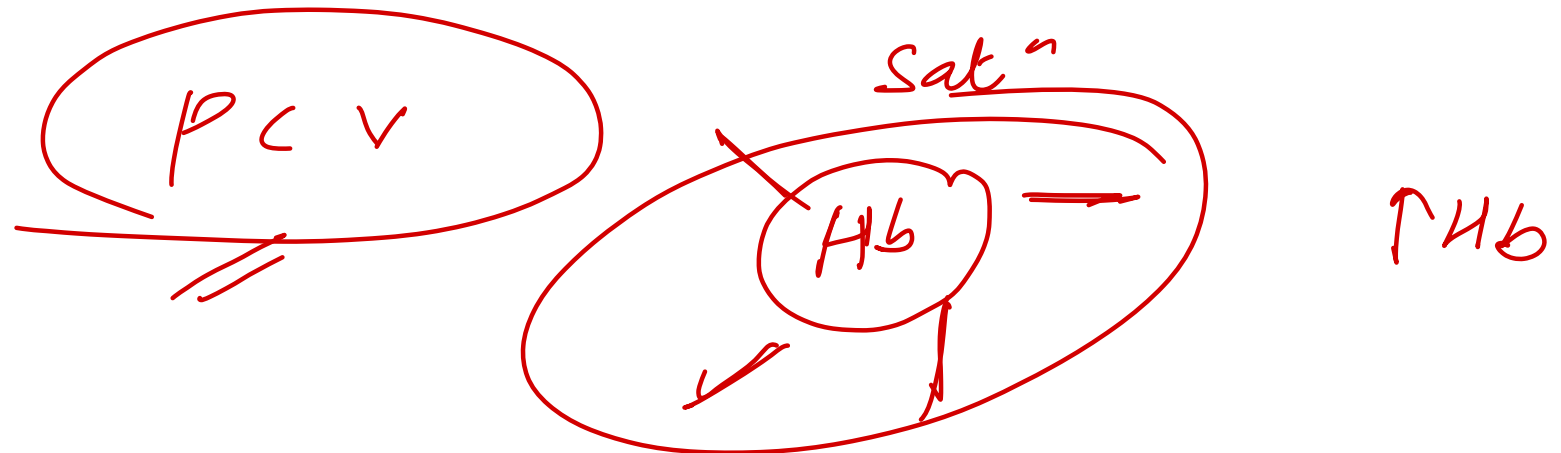
- A. 1, 3, 5
- B. 1, 3, 4, 6
- C. 2, 4, 5
- D. 1, 3, 5, 6





85. A 65-year-old male patient comes to the clinic with unbearable itching while taking a shower which has been present for many months. Physical examination shows the presence of facial plethora. Laboratory examination shows a hemoglobin of 20 g/dL. What would be the best match for this patient?

- A. RBC mass increased, O2 saturation increased, EPO decreased
- B. RBC mass increased, O2 saturation normal, EPO decreased
- C. RBC mass increased, O2 saturation increased, EPO normal
- D. RBC mass normal, O2 saturation normal, EPO increased



86. Which of the following is not associated with poor prognosis in a patient with multiple myeloma?

A. t(4;14)

B. High serum beta-2 microglobulin

C. Low serum albumin

D. t(11;14)

Poor Prognosis	Good Prognosis
t(4;14), t(14;16), t(14;20), del(17p), aneuploidy, hypodiploidy	Hyperdiploid,
↑ beta-2 microglobulin	t(11;14)
Plasmablastic morphology	t(6;14)
Low serum albumin	cyclin D1/D3+

87. All of the following anticoagulants inhibit both Factor Xa and Factor IIa, except:

A. Unfractionated heparin II / X

B. LMWH X > II

~~C. Fondaparinux~~ only X

D. None of the above

90. Which of the following is not compatible with a diagnosis of chronic myelomonocytic leukemia (CMML)?

- A. More than 20% blasts in blood or bone marrow
- B. Absence of Philadelphia chromosome
- C. Peripheral blood monocytos $>1 \times 10^9/L$
- D. Minimal or absent dysplasia in myeloid lineages

AML blastic crises

CMML monocytic

ca - blastic

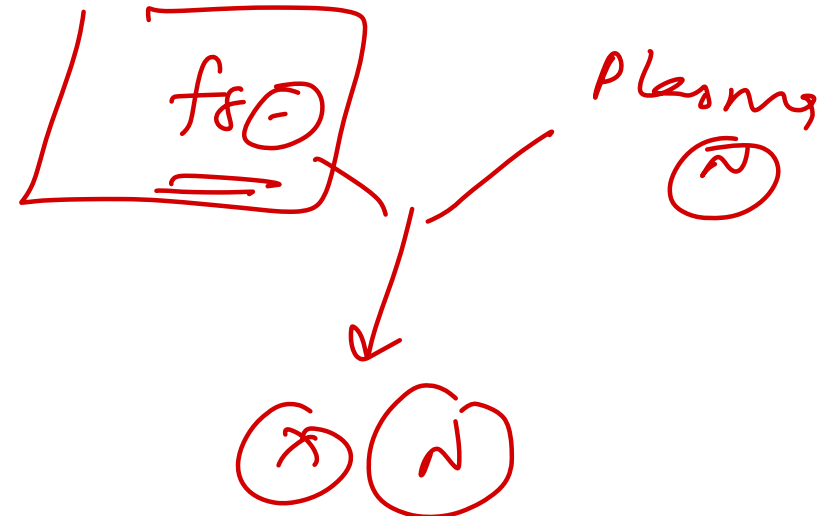
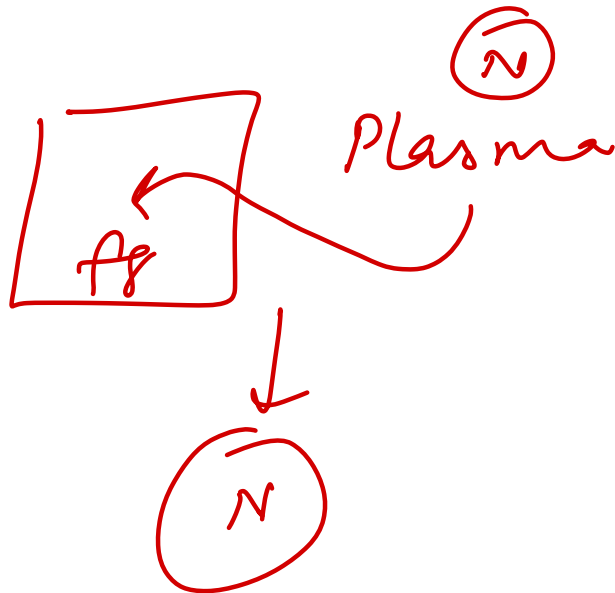
94. Which of the following is false about acquired hemophilia A?

- A. Autoantibodies are formed against factor VIII
- B. Associated with lymphoproliferative malignancies
- ~~C. Presents in childhood or early adulthood~~
- D. Bethesda assay confirms the diagnosis

f8 ⊖

adult late

Plasma mixing



97. A previously healthy 37-year-old female, gravida 0 para 0, presents to the gynecology office with cyclic pelvic pain and bloating. She has been experiencing these symptoms for the past three years but has been unable to seek care due to insurance issues. She describes her menstrual cycles as "heavy" and states they occur every 28 days and last seven to ten days. She denies significant pain or cramping associated with her periods. Vital signs and physical exam are unremarkable. The physician orders a pelvic ultrasound, which shows the presence of multiple uterine leiomyomas, with the largest measuring 10 cm by 8 cm. A complete blood count reveals a hemoglobin of 9.0 g/dL. Peripheral blood smear shows the presence of several large cells with bluish-tinted cytoplasm. Dark blue dots and curved linear structures are observed in the cytoplasm with the Romanowsky stain. Which of the following best describes these inclusions?

- A. Denatured hemoglobin *hemolysis*
- B. Iron deposits *sideroblastic*
- C. Nuclear remnants *asplenia*
- D. ~~Ribosomal genetic material~~

Retenocyte ↑

IDA

98. A 39-year-old female with a past medical history of hypothyroidism, HIV, and psoriasis presents to the emergency department with a one-month history of weight loss and night sweats. She unintentionally lost 13 lbs (5.9 kg) over the previous month. The patient complains of significant fatigue, requiring naps throughout the day. Her current medications include levothyroxine, lamivudine, efavirenz, maraviroc, and topical hydrocortisone cream. She denies tobacco and alcohol use but admits to using intravenous heroin regularly over the past eight years. Vital signs include a blood pressure of 122/82 mmHg, heart rate of 68 beats/min, respiratory rate of 17 breaths/min, and temperature of 38.2°C (100.8 °F). Physical exam reveals multiple enlarged, nontender cervical lymph nodes. A dermatologic exam reveals multiple erythematous lesions and needle track marks on both arms. Her abdomen is nontender and nondistended. A lymph node biopsy is scheduled for the following week. Which of the following will most likely be observed on this biopsy if a $t(8;14)$ translocation is detected?

A. Eosinophilic Cowdry inclusion bodies

B. Monoclonal plasma cells

C. Myeloblasts with Auer rods

D. Tingible body macrophages

$t(8;14)$

HL
MM
AML M3
starry sky

Burkitt



Cerebellum

Get the balance right

Thank you

Best wishes!